

# Spontaneous Intrabronchial Rupture of Bronchogenic Cyst Causing Lobar Pneumonia

Mohd Ilyas, Mohd Yaqoob Wani, Musaib Ahmad Dar, Mir Junaid Ahmad Kazime, Gh. Mohammad, Zubair Ahmad

Department of Radiodiagnosis, Sher-I-Kashmir Institute of Medical Sciences, Srinagar, Jammu and Kashmir, India

## Abstract

Bronchogenic cysts may be asymptomatic or may present with symptoms of tracheal or esophageal compression. Several complications of bronchogenic cysts may occur. Intrabronchial rupture is an infrequent complication. A case of spontaneous intrabronchial rupture of a bronchogenic cyst with basal lobar pneumonia.

**Keywords:** Bronchogenic cyst, intrabronchial rupture, lower lobe consolidation

## INTRODUCTION

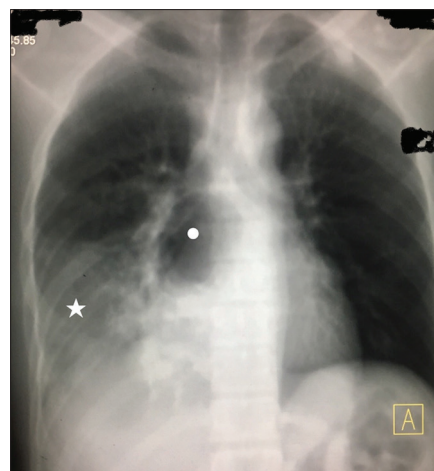The embryologic foregut gets differentiated in trachea and esophagus. Abnormal budding may result in the formation of bronchogenic cysts. The thick walls of bronchogenic cysts may contain ciliated columnar epithelium, cartilage, and mucinous glands. These are commonly seen in the posterior mediastinum, but uncommon locations include intraparenchymal and in the neck.<sup>[1]</sup> Complications of bronchogenic cysts include superior vena cava compression, pleurisy, intrabronchial, and intramediastinal rupture. The intrabronchial rupture is an infrequent complication. A case of spontaneous intrabronchial rupture of a bronchogenic cyst with basal lobar pneumonia is presented here.

## CASE REPORT

A 28-year-old male presented to the medical emergency with the chief complaints of high-grade fever, cough with expectoration (nonpurulent), and chest discomfort. He was diagnosed as having an uncomplicated bronchogenic cyst 3 years previously. The blood pressure at the time of presentation was 120/80 mmHg with a heart rate of 74 beats/min. The body temperature was 101.4°F, and the respiratory rate was 15 breaths/min. Physical examination of the chest revealed pronounced fremitus and decreased breath sounds in the right lower area.

A posteroanterior chest radiograph was performed which revealed a well-defined hyperlucent paravertebral lesion

with an air-fluid level with opacities involving the lower zone of the right lung [Figure 1]. The previous records



**Figure 1:** A posteroanterior chest radiograph showing a hyperlucent posterior mediastinal lesion (white dot) with an air-fluid level and consolidation of the lower lobe of the right lung

**Address for correspondence:** Dr. Mohd Ilyas,  
Department of Radiodiagnosis, Sher-I-Kashmir Institute of Medical  
Sciences, Srinagar - 190 011, Jammu and Kashmir, India.  
E-mail: ilyasmir40@gmail.com

This is an open access journal, and articles are distributed under the terms of the Creative Commons Attribution-NonCommercial-ShareAlike 4.0 License, which allows others to remix, tweak, and build upon the work non-commercially, as long as appropriate credit is given and the new creations are licensed under the identical terms.

**For reprints contact:** reprints@medknow.com

**How to cite this article:** Ilyas M, Wani MY, Dar MA, Kazime MJ, Mohammad G, Ahmad Z. Spontaneous intrabronchial rupture of bronchogenic cyst causing lobar pneumonia. *Ibnosina J Med Biomed Sci* 2018;10:65-7.

### Access this article online

#### Quick Response Code:

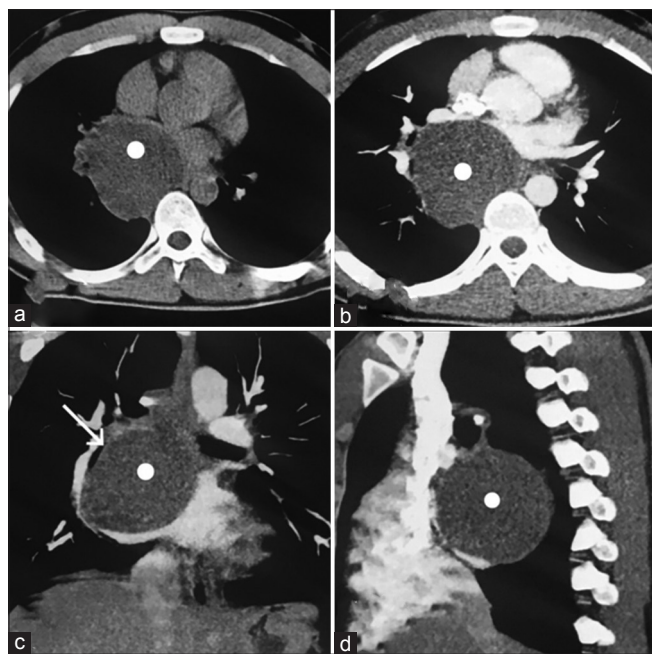


**Website:**  
www.ijmbs.org

**DOI:**  
10.4103/ijmbs.ijmbs\_76\_17

were reviewed. Computed tomography scan dated 3 years back revealed a well-defined, homogeneously fluid-attenuation, nonenhancing lesion in the posterior mediastinum on the right side posterior to the lower lobe bronchus, consistent with features of a bronchogenic cyst [Figure 2]. A contrast-enhanced computed tomography scan was performed using 64-slice CT scanner (Somatom Sensation-64; Siemens Healthcare, Germany) by injection iopromide (Ultravist-370) at a rate of 2.5 ml/s. The study revealed a well-defined air-density lesion in the posterior mediastinum on the right side with an evident air-fluid level giving indirect evidence of the intrabronchial rupture of the bronchogenic cyst. There was evidence of hyperattenuation with air bronchograms involving the lower lobe of the right lung suggesting lobar consolidation. Maximum intensity projection images demonstrated the communication between the cyst and lower lobe bronchus [Figure 3]. The clinical, radiographic, and computed tomographic features confirmed a diagnosis of intrabronchial rupture of a bronchogenic cyst with secondary infection (air-fluid level) with a lobar consolidation of the lower lobe of the right lung was formulated.

The patient was treated with intravenous antibiotics for 3 weeks. The consolidation resolved and the patient was referred to the cardiothoracic surgeon who performed thoracotomy and deroofting of the bronchogenic cyst with its excision. The patient remained presently free of symptoms.



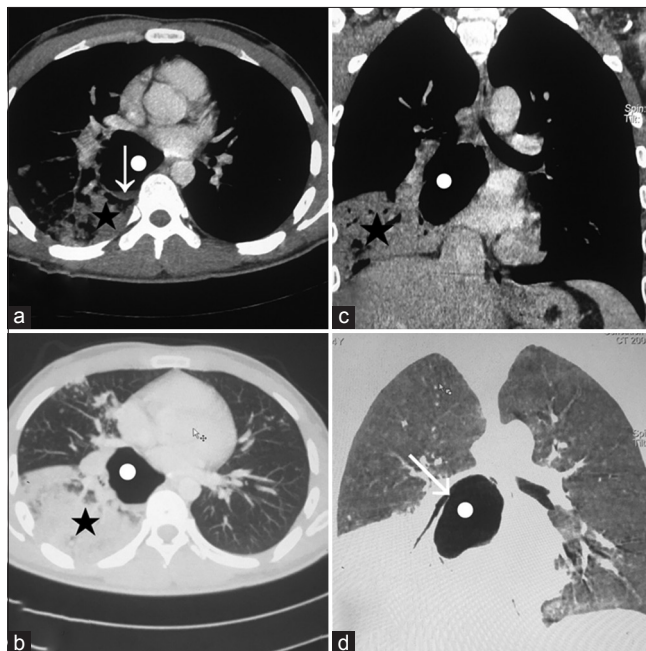
**Figure 2:** Axial noncontrast computed tomography image (obtained 3 years back) showing a well-defined homogeneously fluid-attenuation lesion (white dot) in the posterior mediastinum (a). Axial (b), coronal (c), and sagittal (d) contrast-enhanced computed tomography images showing the lesion to be nonenhancing posterior to lower lobe bronchus on the right side (arrow-c)

## DISCUSSION

Bronchogenic cysts result due to maldevelopment of the primitive foregut. They are mostly located in the mediastinum, but about 20% occur in the lungs. They may be single or multiple and unilocular or multilocular. They are predominantly symptomatic presenting as respiratory distress, cough, stridor, or wheezing. In cases of super-added infection or intrabronchial rupture with associated consolidation, they may present with fever and nonpurulent expectoration.<sup>[2]</sup>

The diagnosis of complicated or uncomplicated bronchogenic cyst can be made using radiography, computed tomography, and endobronchial ultrasonography.<sup>[3]</sup> Surgical excision is the most appropriate treatment for bronchogenic cysts. Transbronchial aspiration can be used as a diagnostic method and as a therapeutic measure in cases who are poor candidates for surgery. Rupture of a cyst may occur during this procedure. Transbronchial aspiration has high recurrence rate but acts as a palliative measure in cases who have features of respiratory obstruction.<sup>[4]</sup>

The management of bronchogenic cysts includes surgical excision even in asymptomatic cases due to the risk of developing the complications. In some cases, where excision is not possible, surgical deroofting can be performed to avoid the complications and relieve the mass effects.<sup>[5]</sup>



**Figure 3:** Axial contrast-enhanced computed tomography image showing right posterior mediastinal lesion (white dot) with air-density and air-fluid level (arrow) and consolidation of the lower lobe on the right side (asterisk) (a). Axial lung window computed tomography image showing the right lower lobe consolidation (asterisk) and air-filled bronchogenic cyst (b). Coronal contrast-enhanced computed tomography image showing the consolidation and air-filled bronchogenic cyst (c). Coronal maximum intensity projection image showing the communication of air-filled bronchogenic cyst with right lower lobe bronchus (arrow) (d). These findings are consistent with intrabronchial rupture of a bronchogenic cyst with lower lobe consolidation in the right lung

## CONCLUSION

The present report highlights the issue of bronchogenic cyst complications. In patients known to have bronchogenic cysts, if they present with the symptoms of pneumonia, a suspicion of intrabronchial rupture shall be kept in mind and proper evaluation by computed tomography was done.

## Declaration of patient's consent

The authors certify that they have obtained the appropriate patient consent form. In the form, the patient has given his consent for his images and other clinical information to be reported in the journal. The patient understands that no names and initials will be published and all due efforts will be made to conceal his identity, but anonymity cannot be guaranteed.

## Disclosures

MI, MYW, MAD: Concept, writing, CT and radiographic evaluation, and editing. MJAK, GM: Review of literature, CT evaluation; ZA: Expertise, guidance, and final review.

## Financial support and sponsorship

Nil.

## Conflicts of interest

There are no conflicts of interest.

## Compliance with ethical principles

No prior ethical approval is required for single case reports.

However, the patient provided consent for publication.

## REFERENCES

1. Marshall G, Cheah C, Lenzo N. Bronchogenic cyst with multiple complications. *Biomed Imaging Interv J* 2007;3:e42.
2. Takeda S, Miyoshi S, Minami M, Ohta M, Masaoka A, Matsuda H, *et al.* Clinical spectrum of mediastinal cysts. *Chest* 2003;124:125-32.
3. Anantham D, Phua GC, Low SY, Koh MS. Role of endobronchial ultrasound in the diagnosis of bronchogenic cysts. *Diagn Ther Endosc* 2011;2011:468237.
4. Nakajima T, Yasufuku K, Shibuya K, Fujisawa T. Endobronchial ultrasound-guided transbronchial needle aspiration for the treatment of central airway stenosis caused by a mediastinal cyst. *Eur J Cardiothorac Surg* 2007;32:538-40.
5. Parambil JG, Gersh BJ, Knight MZ, Krowka MJ, Ryu JH. Bronchogenic cyst causing atrial fibrillation by impinging the right inferior pulmonary vein. *Am J Med Sci* 2006;331:336-8.

### Reviewers:

Ashraf Elghul (Abu Dhabi, UAE)  
Ala-Eddin Sagar (Houston, TX, USA)

### Editors:

Salem A Beshyah (Abu Dhabi, UAE)  
Elmahdi Elkhammas (Ohio, USA)