

Clinical Value of Adipose Tissue-derived Stem Cells Application in Healing of Experimental diabetic and Nondiabetic Burn

Randa Samir Hana¹, Heba Atia Yassa²

Departments of ¹Biochemistry and ²Toxicology and Forensic Medicine, Faculty of Medicine, Assiut University, Assiut, Egypt

Abstract

Objectives: The mechanisms underlying delayed healing in diabetes are not completely understood and biomarkers to identify and to treat such pathways are needed. The aim of the present study is to assess the clinical effect of adipose tissue-derived stem cells in accelerating third-degree burns healing in diabetic and normal mouse model and to restore skin integrity. Assessment of healing by Serpin B3 and keratinocyte growth factor-1 (KGF-1) as novel biomarkers and possible molecular targets of impaired diabetic wound healing. **Materials and Methods:** Forty male mice were set up as an experimental model for third-degree burn. They were randomly divided into four groups as follows: the control group, the diabetic (received high-fat diet) burnt group, the diabetic burnt group treated with adipose tissue-derived stem cells, and the nondiabetic burnt group treated with adipose tissue-derived stem cells. The rate of burn healing, the degree of angiogenesis, and collagen formation were evaluated by histological examination, Serpin B3 (enzyme-linked immunosorbent assay), and KGF-1 measured by real-time polymerase chain reaction. They were sacrificed after the 3rd week for tissue sampling. **Results:** Adipose tissue-derived stem cells accelerate the healing of experimental burns. Serpin B3 was upregulated in adipose tissue-derived stem cells treated burns associated with denser collagen deposition, angiogenesis, and increased expression of KGF-1. Hair growth occurred in adipose tissue-derived stem cells-treated groups but not in the untreated groups. **Conclusion:** Adipose tissue-derived stem cells represent an effective treatment for burn healing especially in resistant diabetic burns. High Serpin B3 and KGF-1 were found to be valuable biomarkers of successful healing in diabetic burns.

Keywords: Adipose-derived stem cell, burn, keratinocyte growth factor-1, mouse model, serpin

INTRODUCTION

Burns occur with high incidence worldwide causing high mortality and morbidity.^[1] After skin injury, the skin depends on stem cells for its renewal involving inflammation, angiogenesis with cytokines, and growth factors production.^[2] In pathological conditions as diabetes mellitus, healing is not completed or delayed. Chronic nonhealing burns have many precipitating factors as reduced angiogenesis and impairment in the cytokines production.^[3] In diabetes, the adult stem cell cannot function properly resulting in impaired healing.^[4] Adipose-derived stromal cells (ADSCs) treatments have been associated with promising outcomes in the wound healing.^[5] Serpin B3, also known as “squamous cell carcinoma antigen-1”, is a member of the serpin superfamily of serine protease inhibitors which are involved in the regulation of apoptosis, inflammation, and angiogenesis.^[6]

Keratinocyte growth factor-1 (KGF-1) is a member of the fibroblast growth factor family produced by fibroblasts,

smooth muscle cells, and endothelial cells.^[7] It is expressed in injured skin and extensively produced in the early healing process of the wound.^[8] KGF-1 has been shown to induce migration and multiplication of keratinocytes that produce various growth factors and cytokines during the healing process.^[9,10]

Therefore, identification of the value and possible adverse effects of ADSCs for burn healing in normal and diabetic conditions using an animal model are needed before the human trials. The assessment of healing by Serpin B3 and KGF-1 as novel biomarkers and molecular targets of impaired diabetic wound healing.

Address for correspondence: Dr. Randa Samir Hana,
Department of Biochemistry, Forensic Medicine,
Assiut University, Egypt.
E-mail: mariam132002@yahoo.com

This is an open access journal, and articles are distributed under the terms of the Creative Commons Attribution-NonCommercial-ShareAlike 4.0 License, which allows others to remix, tweak, and build upon the work non-commercially, as long as appropriate credit is given and the new creations are licensed under the identical terms.

For reprints contact: reprints@medknow.com

How to cite this article: Hana RS, Yassa HA. Clinical value of adipose tissue-derived stem cells application in healing of experimental diabetic and nondiabetic burn. *Ibnosina J Med Biomed Sci* 2018;10:119-24.

Access this article online

Quick Response Code:



Website:
www.ijmbs.org

DOI:
10.4103/ijmbs.ijmbs_33_18

MATERIALS AND METHODS

Animal work

Young adult male mice (c57BL6 strain, 6-week old) were purchased and housed in the animal laboratory of Assiut University after approval of the Ethics Committee. They were allowed to adapt the new place for a week. Body weights were measured [Figure 1]. Mice were fed with either a standard chow (10% fat, the normal healthy group) or a high-fat diet (60% fat) to induce diabetes.^[11] Blood was collected in the 3rd week after 6-h fasting by retro-orbital sinus puncture. Blood glucose was determined with Beckman Coulter (Fullerton, CA, USA). Insulin concentrations were determined with the Rat Insulin ELISA kit (Crystal Chem, Downers Grove, PA, USA). Both blood glucose and insulin levels were higher in the high fat fed than in the normal chow group (glucose: 7.0 ± 0.2 vs. 10.2 ± 0.4 mM, $P < 0.01$; insulin: 1.4 ± 0.2 vs. 6.2 ± 1.5 ng/ml), respectively.

Thermal injury and stem cell production

Following general anesthesia, the dorsum was shaved and a heated metal probe (300 g, 70°C contact temperature) were placed on the back of mice for 7 s to produce a third-degree burn where the epidermis and the deep layer of the dermis were affected. Collagen fibers were abnormally arranged, and hair follicles were degenerated.^[12] They received analgesia

with buprenorphine subcutaneously for pain control, mice were allowed to recover under heat lamp, early cleaning, debriding plus antibiotic ointments were used. 1 g of subcutaneous mice inguinal and epididymal adipose tissue (6–8 weeks old) were taken to increase the amount of fat. Digestion medium-containing collagenase (1800 units of collagenase/3 ml DMEM/1 g fat) was added and shaken at 37°C for 90 min until complete digestion (no tissue clumps), centrifuged at 700 rpm for 10 min to collect the pellet of stromal-vascular cells. The cells were counted with a hemocytometer then seeded into a dish with culture medium containing 10% fetal bovine serum, DMEM/F12, and 1% antibiotics and incubated. ADSCs were induced to differentiate into adipocytes using cell differentiation kits (RandD Systems Minneapolis, USA) in accordance with the manufacturer instruction. Adipocyte differentiation was determined using flow cytometry and Oil Red O staining [Figure 2].

The mice were randomly divided into two groups as follows: the ADSCs-treated group (20 mice, ten healthy, and ten diabetics) and the untreated group (20 mice, ten healthy, and ten diabetic). One day after burn, mice received 100 μ L of 1×10^6 ADSCs in PBS/wound by 1 mL syringe guided to the base of the wounds at the periphery. Images of the burnt area were taken by a digital camera (Samsung Galaxy note) on day 1, 3, 7, 14, and 21 after injury to measure the surface area as an oval shape = maximum diameter \times maximum diameter perpendicular to the first one.^[13] Images of the burns were taken by a digital camera twice a week which were calculated by a digital camera combined with Image J medical imaging software with no significant difference found by the two methods. Hair growth was evaluated. After the 3rd week, the mice were sacrificed to obtain full-thickness tissue samples to make stained slides, analysis of protein content, RNA quantification and to measure inflammatory, and angiogenic biomarkers.

Examination of healing-related factors

After homogenization, total RNA was extracted using TRIzol (Invitrogen, Carlsbad, CA, USA) and reverse transcription polymerase chain reaction was performed using specific primer for KGF-1 (GAPDH for normalization Forward GGCACCAGGGCTGCTTT 209 Reverse ATTTGATGTTGGCGGGATKGF-1, KGF-1: Forward

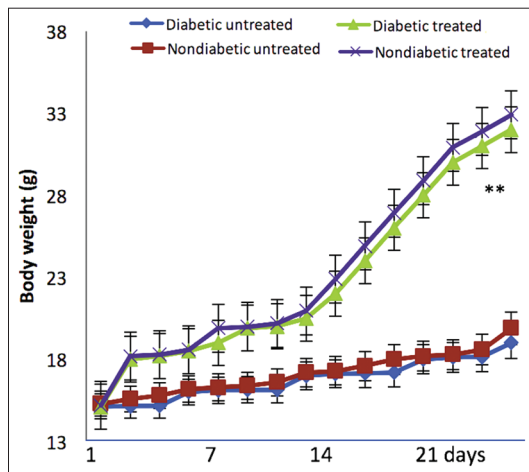


Figure 1: Body weights of different study groups (mean \pm standard deviation, $**P < 0.01$)

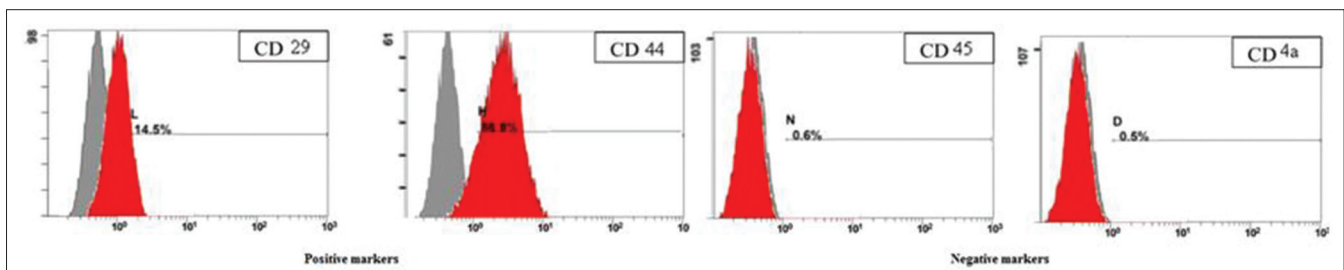


Figure 2: Identification of surface markers for adipose-derived stromal cell after reaction with specific antibodies and analysis by flow cytometry. The y-axis represents the cells. The x-axis represents the relative fluorescence intensity. Numbers indicate the percentage of stained cells (red) compared with the unstained cells

5'-CACCATGCACAAATGGATACTGACATG-3', and 5'-AGTTATTGCCATAGGAAGAAAGT-3'). The PCR conditions were as follows: 94°C, 30 s for denaturation, followed by 30 cycles, annealing at 58°C for 30 s, and extension at 72°C for 30 s. The bands obtained were measured, and the relative mRNA expression was calculated as the ratio of the KGF-1 mRNA to the density of GAPDH mRNA.

ELISA

Frozen tissue was minced, RIPA buffer (Sigma-Aldrich, St Louis, USA) was added then centrifuged at 4°C for 20 min to separate insoluble proteins and the supernatant was centrifuged at 15°C for 15 min to avoid crystallization of salt. Protein content was quantified using the lowery method.^[14] ELISA was used to measure Serpin B3 content in tissue samples (Catalog No. LS-F17049, Lifespan bioscience, 2401 Fourth Avenue Suite 900 Seattle, WA 98121, USA). In brief, 100 µl sample was added and incubated at room temperature for 2.5 h. 100 µl prepared biotin antibody was added and incubated at room temperature 1 h. Then, 100 µl streptavidin was added and incubated at room temperature 45 min. Then, 100 µl TMB substrate was added and incubated at room temperature 30 min. Finally, 50 µl stop solution was added and read at 450 nm.

Statistical analysis

Data were analyzed using Statistical Package for Social Sciences (SPSS Inc., version 13, Chicago, IL, USA) and expressed as mean ± standard deviation. Data were analyzed using unpaired student's *t*-tests and one-way analysis-of-variance with $P < 0.05$ was considered statistically significant.

RESULTS

All experimental animals maintained a normal appetite and body temperature. All burns healed and scars formed at the site of each burn. In the control group, one mouse died in the 1st week. No other complications were observed. ADSCs-treated burns showed significantly smaller surface

areas and greater collagen deposition ($P < 0.05$). Hair growth occurred in ADSCs-treated groups but not in the untreated groups. In the 1st week, wound area measured $127.3 \pm 10.0 \text{ mm}^2$ in the healthy control group, $129.7 \pm 22.0 \text{ mm}^2$ in the diabetic group, $121.3 \pm 13.0 \text{ mm}^2$ in the ADSCs healthy group, and $125.1 \pm 11.0 \text{ mm}^2$ in the ADSCs diabetic group adipose tissue group [Figures 3 and 4].

There were statistically significant lower epithelial gap values, higher collagen deposition for the ADSCs groups [Figure 5, $P < 0.05$]. The mean difference between burns on days 1 and 14 of all ADSCs-treated burns ($2.1 \pm 0.1 \text{ mm}$ in healthy group, 2.6 ± 0.2 in the diabetic group, $P < 0.05$) were significantly smaller than those of the untreated wounds ($2.8 \pm 0.2 \text{ mm}$ in healthy group, 3.0 ± 0.1 in the diabetic group $P < 0.05$). In the sections stained with Masson's trichrome, all ADSCs-treated burns showed higher blue staining densities than the untreated burns [Figures 5 and 6].

The degree of collagen deposition was highest in the healthy-treated group and tends to decrease in the treated diabetic, then the untreated nondiabetic and finally the diabetic untreated group ($P < 0.05$ for all). Lymphocyte and polymorphonuclear leukocytes counts were smaller in the ADSCs group than in the two other groups while macrophage count was higher in these; however, none were statistically significant [Table 1]. The ADSCs groups had the highest degree of neovascularization as detected by KGF-1 and Serpin B3 (significantly higher in the nondiabetic group, $P < 0.05$) and then in the untreated nondiabetic and the diabetic group [Figures 7 and 8].

ELISA was used to measure Serpin B3 concentrations after normalization to the total protein concentration. The Serpin B3/protein ratio was significantly two-fold higher in ADSCs-treated groups ($P < 0.01$, significantly higher in the nondiabetic group, $P < 0.05$) compared with the untreated groups (significantly higher in the nondiabetic group, $P < 0.05$). The mouse model suggests that high serpinB3 level is sufficient to improve diabetic and nondiabetic burn healing. It represents a nonpathogenic marker of effective burn healing.

DISCUSSION

Many recent studies have highlighted stem cells role in wound healing generally and burn healing in specific.^[15,16] Stem cells are considered highly promising candidate cells for regenerative applications, especially in chronic nonhealing wounds, such as diabetic burns that are characterized by delayed healing, increased oxidative stress, and a heightened inflammatory state because they possess a high proliferative capacity, the potential to differentiate into other cell types without any concerns about rejection, or the need for immunosuppressive treatment.^[17]

Adipose tissue is a multifunctional organ that contains mature adipocytes, endothelial cells macrophages, smooth muscle

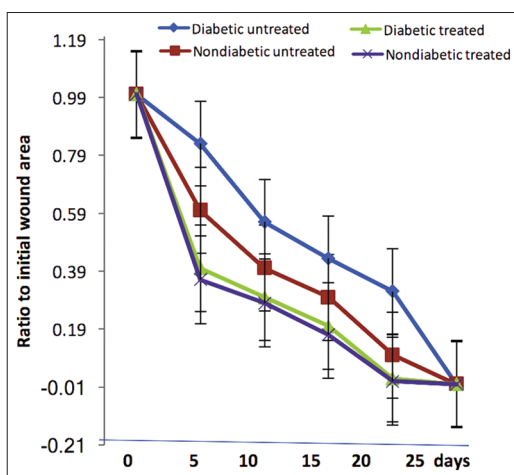


Figure 3: Ratio of wound surface area in different groups (mean ± standard deviation)

Table 1: Parameters of inflammatory reactions in different study groups

Inflammatory reaction	ADSCs nondiabetic group	ADSCs diabetic group	Untreated nondiabetic group	Untreated diabetic group
Polymorphonuclear leukocyte count	207.3±113.3	217.3±161.1	282.3±112.2	299.3±111.3
Lymphocyte count	11.5±8.2	17.3±9.3	10.3±5.6	13.2±7.3
Macrophage count	45.2±24.1	39.9±13.6	37.8±18.9	41.3±24.3

ADSCs: Adipose tissue-derived stem cells

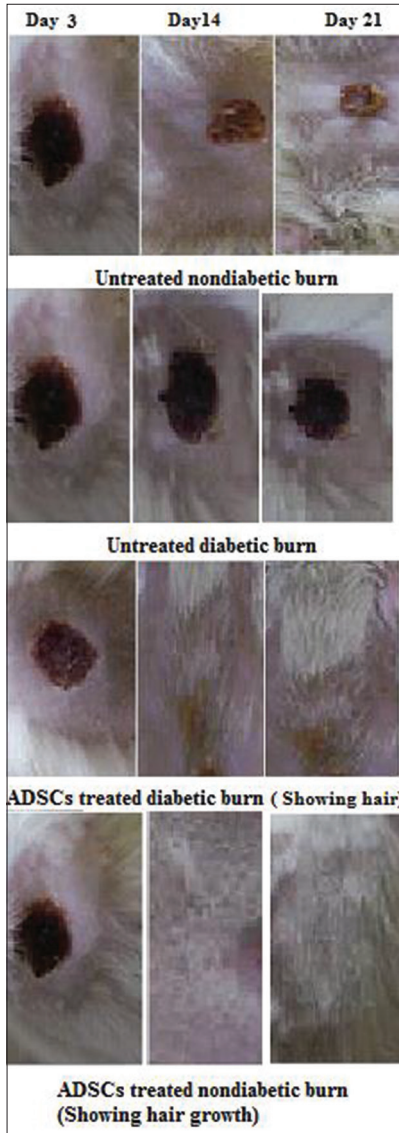


Figure 4: Photos showing the wound surface area in different studied groups

cells, and preadipocytes. This tissue contains progenitor cells with a perivascular origin called adipose-derived stem cells that can differentiate in various cell lineages. The potential plasticity of these cells offers new approaches in surgery and regenerative medicine.^[18,19] In the current study, ADSCs-treated burns showed more rapid closure associated with hair growth but not in the untreated groups; this was presumed to be due to ADSCs promoting reepithelialization. Koenen *et al.*^[20] isolated

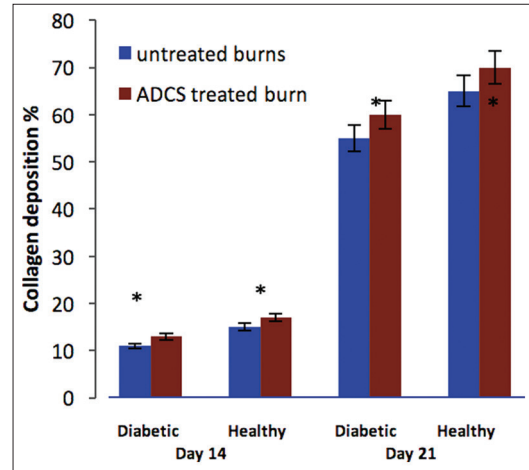
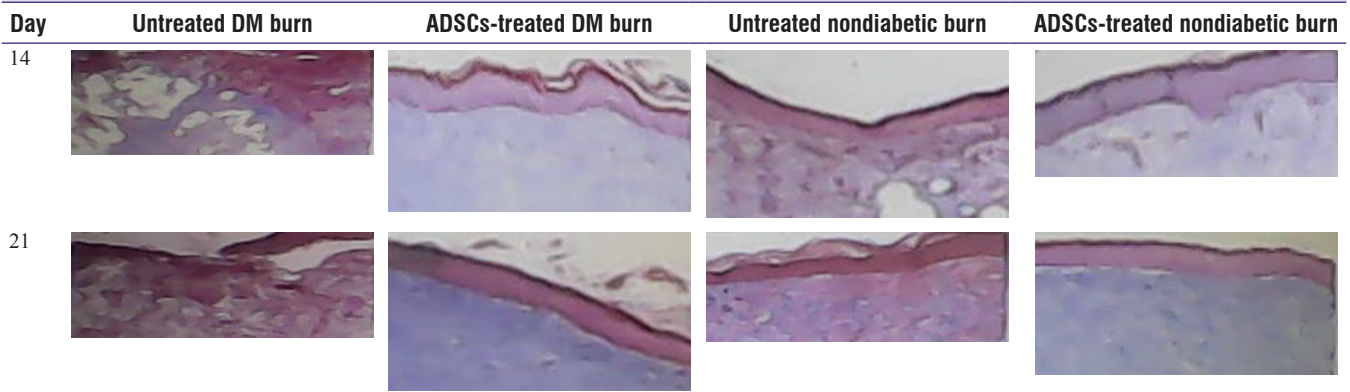


Figure 5: Comparison of the percentage of collagen fibers (all adipose-derived stromal cells-treated wounds showed a statistically significant higher levels, * $P < 0.05$)

healing and nonhealing wound fluids and compared their effects on adipose tissue-derived stem cell function. They concluded that healing wound fluids (unlike chronic ones) stimulate the proliferation of adipose-derived stem cells.^[20] Hence, delayed healing may be due to ADSCs deficiency that may explain the current findings. Fibroblasts are responsible for secreting different growth factors such as KGF-1, which has an important role in keratinocyte morphogenesis.^[21-23] Hence, to detect the transformation of stem cells into a keratinocyte and keratinocyte differentiation, the expression of KGF-1 was analyzed.

In the current study, increase in KGF-1 in ADSCs treated was demonstrated. Alexaki *et al.*,^[24] successfully used ADSCs in wound healing in mice and concluded that ADSCs promoted reepithelialization by their effect on keratinocytes mediated by KGF-1 and platelet-derived growth factor-BB similar to the current findings but in burns. KGF-1 induces the proliferation of epithelial cells, hair follicle development, and keratinocyte differentiation.^[24] In the stained slides, increased collagen deposition in ADSCs-treated burns was detected, which indicated the promotion of the proliferation of the fibroblast, the accumulation of collagen fibers that increase the strength of the wound.^[25] The previous studies have shown that stem cells promote fibroblast proliferation resulting in increased granulation tissue formation.^[3,26] In a previous study, topical application of KGF has been successfully tested for treatment of injuries. It was important to repeatedly administer large amounts because of its short half-life, and hence, increasing the costs.^[26]

Figure 6: Collagen deposition in granulation tissue at day 14 and 21. The adipose tissue-derived stem cells-treated burns showed denser collagen than the untreated burns (magnified × 9200)



DM: Diabetes mellitus, ADSCs: Adipose tissue-derived stem cells

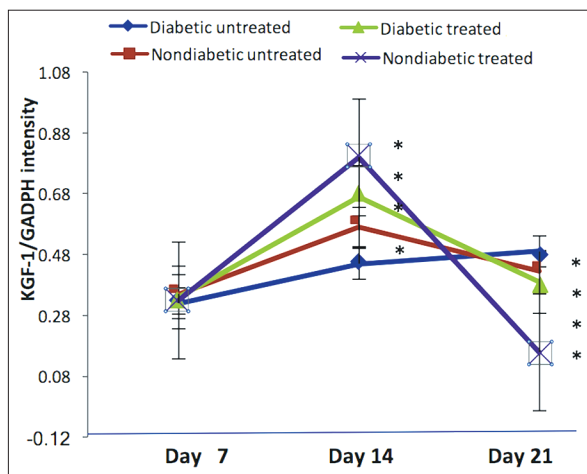


Figure 7: Keratinocyte growth factor-1 expression in different studied groups (mean ± standard deviation, *P < 0.05)

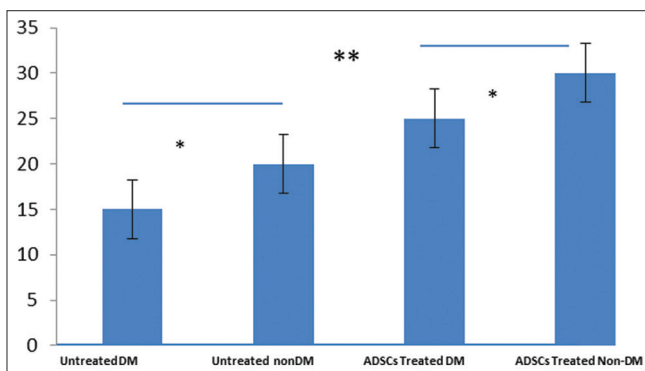


Figure 8: Validation of Serpin B3 (ng/ml/total protein ug/ml) in different studied groups (*P < 0.05, **P < 0.01)

ADSCs stimulate keratinocyte proliferation and migration possibly^[25] through KGF-1 as the mRNA expression of KGF-1 in ADSCs-treated wounds was increased; hence, it represents a better alternative for recombinant KGF-1 topical application.

SerpinB3 belongs to the serine protease inhibitors family, involved in wound healing including epithelial-to-mesenchymal

transition.^[27] The current study showed higher Serpin B3 levels in ADSCs treated compared with untreated burns. Previous studies reported higher levels of Serpin B3 in rapidly healing compared with nonhealing wounds, especially if impaired by diabetes, as the current work. An imbalance between metalloproteases and their inhibitors appears to be associated with features of nonhealing diabetic.^[28,29] Hence, Serpin B3 levels may serve as a biomarker of burn healing in diabetic patients based on the ROC curve, Serpin B3 showed the ability to discriminate between healing wounds and those which will not improve at follow-up as it can reflect features of the ongoing systemic inflammatory process.

CONCLUSION

Subcutaneous injection of ADSCs resulted in increased collagen deposition, angiogenesis, and hair growth (may become more prominent with higher ADSCs dose) in a mouse burn model suggesting that ADSCs may be applied in patients with nonhealing skin defects, KGF-1 and Serpin B3 are valid biomarkers of successful healing that can differentiate between pathogenic and nonpathogenic burn healing in diabetes.

Acknowledgments

The authors are grateful to Dr. Bahaa Lamie for providing an expert insight about surgical management of burns.

Authors' contributions

RH performed the experiment and drafted the manuscript and HAY contributed to the stem cells work. Both authors revised and approved the final manuscript.

Financial support and sponsorship

Nil.

Conflicts of interest

There are no conflicts of interest.

Compliance with ethical principles.

All animal experiments were approved by the Institutional Animal Care and Use Committee, Assiut University.

REFERENCES

- Brigham PA, McLoughlin E. Burn incidence and medical care use in the United States: Estimates, trends, and data sources. *J Burn Care Rehabil* 1996;17:95-107.
- Fuchs E, Segre JA. Stem cells: A new lease on life. *Cell* 2000;100:143-55.
- Singer AJ, Clark RA. Cutaneous wound healing. *N Engl J Med* 1999;341:738-46.
- Wu Y, Chen L, Scott PG, Tredget EE. Mesenchymal stem cells enhance wound healing through differentiation and angiogenesis. *Stem Cells* 2007;25:2648-59.
- Branski LK, Gauglitz GG, Herndon DN, Jeschke MG. A review of gene and stem cell therapy in cutaneous wound healing. *Burns* 2009;35:171-80.
- Benarafa C, Remold-O'Donnell E. The ovalbumin serpins revisited: Perspective from the chicken genome of clade B serpin evolution in vertebrates. *Proc Natl Acad Sci U S A* 2005;102:11367-72.
- Sutherland J, Denyer M, Britland S. Motogenic substrata and chemokinetic growth factors for human skin cells. *J Anat* 2005;207:67-78.
- Finch PW, Rubin JS. Keratinocyte growth factor/fibroblast growth factor 7, a homeostatic factor with therapeutic potential for epithelial protection and repair. *Adv Cancer Res* 2004;91:69-136.
- Goldman R. Growth factors and chronic wound healing: Past, present, and future. *Adv Skin Wound Care* 2004;17:24-35.
- Galkowska H, Olszewski WL, Wojewodzka U. Keratinocyte and dermal vascular endothelial cell capacities remain unimpaired in the margin of chronic venous ulcer. *Arch Dermatol Res* 2005;296:286-95.
- Schreyer SA, Wilson DL, LeBoeuf RC. C57BL/6 mice fed high fat diets as models for diabetes-accelerated atherosclerosis. *Atherosclerosis* 1998;136:17-24.
- Saranto JR, Rubayi S, Zawacki BE. Blisters, cooling, antithromboxanes, and healing in experimental zone-of-stasis burns. *J Trauma* 1983;23:927-33.
- Falanga V, Brem H. Wound bed preparation for optimal use of advanced therapeutic products. In: Falanga V, editor. *Cutaneous Wound Healing*. London: Taylor & Francis; 2001.
- Lowry OH, Rosebrough NJ, Farr AL, Randall RJ. Protein measurement with the folin phenol reagent. *J Biol Chem* 1951;193:265-75.
- Ra JC, Shin IS, Kim SH, Kang SK, Kang BC, Lee HY, *et al*. Safety of intravenous infusion of human adipose tissue-derived mesenchymal stem cells in animals and humans. *Stem Cells Dev* 2011;20:1297-308.
- Falanga V, Iwamoto S, Chartier M, Yufit T, Butmarc J, Kouttab N, *et al*. Autologous bone marrow-derived cultured mesenchymal stem cells delivered in a fibrin spray accelerate healing in murine and human cutaneous wounds. *Tissue Eng* 2007;13:1299-312.
- Badiavas EV, Ford D, Liu P, Kouttab N, Morgan J, Richards A, *et al*. Long-term bone marrow culture and its clinical potential in chronic wound healing. *Wound Repair Regen* 2007;15:856-65.
- Ozturk S, Karagoz H. Experimental stem cell therapies on burn wound: Do source, dose, timing and method matter? *Burns* 2015;41:1133-9.
- Chae DS, Han S, Son M, Kim SW. Stromal vascular fraction shows robust wound healing through high chemotactic and epithelialization property. *Cytotherapy* 2017;19:543-54.
- Koenen P, Spanholtz TA, Maegele M, Stürmer E, Brockamp T, Neugebauer E, *et al*. Acute and chronic wound fluids inversely influence adipose-derived stem cell function: Molecular insights into impaired wound healing. *Int Wound J* 2015;12:10-6.
- Eyuboglu AA, Uysal CA, Ozgun G, Coskun E, Markal Ertas N, Haberal M, *et al*. The effect of adipose derived stromal vascular fraction on stasis zone in an experimental burn model. *Burns* 2018;44:386-96.
- Rodgers K, Jadhav SS. The application of mesenchymal stem cells to treat thermal and radiation burns. *Adv Drug Deliv Rev* 2018;123:75-81.
- Watt SM, Pleat JM. Stem cells, niches and scaffolds: Applications to burns and wound care. *Adv Drug Deliv Rev* 2018;123:82-106.
- Alexaki VI, Simantiraki D, Panayiotopoulou M, Rasouli O, Venihaki M, Castana O, *et al*. Adipose tissue-derived mesenchymal cells support skin reepithelialization through secretion of KGF-1 and PDGF-BB: Comparison with dermal fibroblasts. *Cell Transplant* 2012;21:2441-54.
- Luo G, Cheng W, He W, Wang X, Tan J, Fitzgerald M, *et al*. Promotion of cutaneous wound healing by local application of mesenchymal stem cells derived from human umbilical cord blood. *Wound Repair Regen* 2010;18:506-13.
- Javazon EH, Keswani SG, Badillo AT, Crombleholme TM, Zoltick PW, Radu AP, *et al*. Enhanced epithelial gap closure and increased angiogenesis in wounds of diabetic mice treated with adult murine bone marrow stromal progenitor cells. *Wound Repair Regen* 2007;15:350-9.
- Marti GP, Mohebi P, Liu L, Wang J, Miyashita T, Harmon JW. KGF-1 for wound healing in animal models. *Electroporation Protoc* 2008;423:383-91.
- Quarta S, Vidalino L, Turato C, Ruvoletto M, Calabrese F, Valente M, *et al*. SERPINB3 induces epithelial-mesenchymal transition. *J Pathol* 2010;221:343-56.
- Menghini R, Uccioli L, Vainieri E, Pecchioli C, Casagrande V, Stoehr R, *et al*. Expression of tissue inhibitor of metalloprotease 3 is reduced in ischemic but not neuropathic ulcers from patients with type 2 diabetes mellitus. *Acta Diabetol* 2013;50:907-10.

Reviewers:

Atilla Eyuboglu (Ankara, Turkey)
Sushin Lee (Kaohsiung, Taiwan)

Editors:

Salem A Beshyah (Abu Dhabi, UAE)
Elmahdi Elkhammas (Columbus, Ohio, USA)