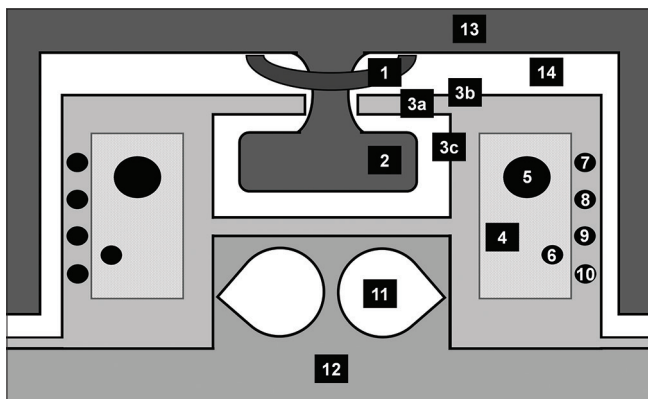


## Neuroanatomy of Cavernous Sinus and Sellar Region: Clinico-anatomical Correlation

Dear Editor,

We read the article entitled “Unusually Long Survival of an Adult Patient with Atypical Teratoid/Rhabdoid Tumor of the Sellar Region: A Follow-Up Report” in a recent issue of the journal with great interest. Almalki *et al.* reported the follow-up of an adult female diagnosed with a sellar atypical teratoid/rhabdoid tumor treated with surgical resection, radiotherapy, and chemotherapy. Almost 2 years postoperatively, she had no radiological evidence of recurrence since the first management.<sup>[1]</sup>

Herein, we would like to provide a figure [Figure 1] and a table [Table 1] to better comprehend the sellar region that clinico-anatomically correlate with the cavernous sinus. As we already stated



**Figure 1:** Schematic diagram of the cavernous sinus. 1: Optic chiasm, 2: Pituitary gland, 3a: Diaphragm selli, 3b: Meningeal layer, 3c: Endosteal layer, 4: Cavernous sinus, 5: Internal carotid artery, 6: VI Cranial nerve, 7: III Cranial nerve, 8: IV Cranial nerve, 9: V1 Cranial nerve, 10: V2 Cranial nerve, 11: Sphenoid sinus, 12: Sphenoid bone, 13: Brain, 14: Subarachnoid space

previously, any process that affects the intracranial region may lead to lesions in more than one cranial nerve (CN) or structure, and when this occurs, the clinical presentation could be complex, causing a delay in the diagnosis.<sup>[2]</sup> One example of this complexity is the isolated Horner’s syndrome secondary to rhinosinusitis, which can be explained by Raeder syndrome affecting the third neuron of the oculosympathetic pathway.<sup>[3]</sup>

The sellar region includes the sella turcica and the pituitary gland (adenohypophysis and neurohypophysis); on the other hand, the parasellar region comprizes the cavernous sinuses, suprasellar cistern, hypothalamus, and ventral inferior third ventricle. It is noteworthy that the anatomic localization of the lesions during the clinical examination is essential for the differential diagnosis between sellar and parasellar lesions. In this way, due to the small size of the pituitary gland and its proximity to many important structures, the neuroimaging diagnosis is challenging.<sup>[4]</sup>

The cavernous sinus is a venous dural sinus located on either side of the pituitary fossa and the body of the sphenoid bone between the endosteal and meningeal layers of the dura. The dural venous sinuses are embryologically created by the separation of these meningeal layers, and they are full of venous blood and lined by endothelium. The cranial nerves III, IV, V1, and V2 enter by the lateral wall of the cavernous sinus, but the internal carotid artery and the CN VI enter more centrally. It is worthy of mentioning that

**Table 1: Cavernous sinus contents and rule of 3 (CAVERN)**

Letter	Acronym	Rule of 3 - content
C	Contents, types of content present	CNs, internal carotid artery (arterial), and sinus (venal)
A	Afferent veins	Ophthalmic veins, superficial middle cerebral artery, and sphenoparietal sinus (vault veins)
V	Vein (anatomical regions drained)	Orbit, brain, and vault bones
E	Efferent veins	Superior petrosal sinus, inferior petrosal sinus, and emissary vein to the pterygoid plexus
R	Runner emissary veins	Foramen lacerum, ovale, and accessory sphenoidal foramen
N	Nerves	Motor (III, IV, and VI), sensory (V1 and V2), and sympathetic

CN: Cranial nerve

the sympathetic trunk forms a plexus of nerves around the internal carotid artery known as the carotid plexus. Furthermore, all the nerves that pass in the cavernous sinus go after in the superior orbital fissure.<sup>[5]</sup>

In summary, the neuroanatomy of the sellar and parasellar regions is intricate and needs a continuous review. In this context, the comprehension of these small structures and its correlation with the neurological examination can improve the differential diagnosis, prompt the diagnosis of rare pathologies, and avoid its complications.

#### Financial support and sponsorship

Nil.

#### Conflicts of interest

None.

**Jamir Pitton Rissardo<sup>1</sup>,  
Ana Letícia Fornari Caprara<sup>1</sup>**

<sup>1</sup>Department of Medicine, Federal University of Santa Maria, Santa Maria, Rio Grande do Sul, Brasil


**Address for correspondence:** Dr. Jamir Pitton Rissardo,  
Rua Roraima, Santa Maria, Rio Grande do Sul, Brasil.  
E-mail: jamirrissardo@gmail.com

**Submitted:** 27-Mar-2020  
**Accepted:** 28-Mar-2020 **Published:** 27-Jun-2020

#### REFERENCES

1. Almalki MH, Altwairgi A, Orz Y. Unusually long survival of an adult patient with atypical teratoid/rhabdoid tumor of the sellar region: A follow-up report. *Ibnosina J Med Biomed Sci* 2020;12:53-6.
2. Rissardo JP, Caprara AL. Syndromes with involvement of multiple cranial nerves: An overview. *Ibnosina J Med Biomed Sci* 2020;12:74-5.
3. Rissardo JP, Caprara AL, Silveira JO, Jauris PG. Isolated Horner's syndrome secondary to rhinosinusitis: A case report and literature review. *Egypt J Neurol Psychiatry Neurosurg* 2020;56:1-4.
4. Abad AP. Sellar and parasellar pain syndromes. *Current Pain Headache Rep* 2019;23:7.
5. Petre G, Marinescu T, Stroica L, Lupu CN, Tarta-Arsene E, Lupu G, *et al.* Anatomic and imaging aspects of cavernous sinus. *Rom J Funct Clin Macro Micros Anat Anthropol* 2019;18:161-64.

This is an open access journal, and articles are distributed under the terms of the Creative Commons Attribution-NonCommercial-ShareAlike 4.0 License, which allows others to remix, tweak, and build upon the work non-commercially, as long as appropriate credit is given and the new creations are licensed under the identical terms.

Access this article online	
<b>Quick Response Code:</b> 	<b>Website:</b> <a href="http://www.ijmbs.org">www.ijmbs.org</a>
	<b>DOI:</b> 10.4103/ijmbs.ijmbs_32_20

**How to cite this article:** Rissardo JP, Caprara AL. Neuroanatomy of cavernous sinus and sellar region: Clinico-anatomical correlation. *Ibnosina J Med Biomed Sci* 2020;12:137-8.

© 2020 Ibnosina Journal of Medicine and Biomedical Sciences | Published by Wolters Kluwer - Medknow

#### Reviewers:

Not Applicable (Correspondence)

#### Editors:

Elmahdi Elkhammas, (Columbus OH, USA)  
Salem A Beshyah (Abu Dhabi, UAE)