

# Evaluation of Platelet-Rich Fibrin and Platelet-Rich Plasma in Impacted Mandibular Third Molar Extraction Socket Healing and Bone Regeneration: A Split-Mouth Comparative Study

Ravi Bhujbal, Suresh Kandagal Veerabhadrapa<sup>1</sup>, Seema Yadav<sup>2</sup>, Mouneshkumar Chappi<sup>3</sup>, Vinay Patil

Department of Oral and Maxillofacial Surgery, Nanded Rural Dental College and Research Center, Nanded, <sup>3</sup>Department of Oral and Maxillofacial Surgery, School of Dental Sciences, Krishna Institute of Medical Sciences Deemed University, Karad, Maharashtra, India, Departments of <sup>1</sup>Oral Diagnosis and Radiology, and <sup>2</sup>Periodontology, Faculty of Dentistry, SEGi University, Petaling Jaya, Selangor, Malaysia

## Abstract

**Objective:** To compare the efficacy of platelet-rich fibrin (PRF) and platelet-rich plasma (PRP) in postoperative extraction socket healing, pain, swelling, and bone regeneration after surgical removal of impacted mandibular third molars. **Materials and Methods:** The present split-mouth comparative study was conducted on 20 patients undergoing bilateral identical mandibular third molar extraction. PRF was placed on the right side of the third molar extraction socket, and PRP was placed on the contralateral side. Evaluation of soft tissue healing, pain, and swelling was carried out on immediate postoperative and on the 1<sup>st</sup> day, 3<sup>rd</sup> day, and 7<sup>th</sup> day. Radiological bone density was assessed on the 3<sup>rd</sup> and 6<sup>th</sup> months postoperatively. **Results:** Soft tissue healing was better in PRF site. The postoperative pain scores in PRF site were less compared with PRP site; however, there was no significant difference between immediate postoperative period ( $P < 0.15$ ), 1<sup>st</sup> day ( $P < 0.96$ ), 3<sup>rd</sup> day ( $P < 0.58$ ), and 7<sup>th</sup> day ( $P < 0.78$ ). Measurement of swelling on the 1<sup>st</sup> day ( $P < 0.0020$ ) and 3<sup>rd</sup> day ( $P < 0.0010$ ) showed significant difference on PRF site, but it ceases to nonsignificant on the 7<sup>th</sup> day ( $P < 1.00$ ). Postoperative mean bone density at the 3<sup>rd</sup> and 6<sup>th</sup> months was higher in PRF site, which was statistically significant ( $P < 0.00001$ ). **Conclusion:** Our results showed a significant improvement in the soft tissue wound healing and increase in bone density in PRF site than PRP site. There was significant reduction of the swelling found on the 1<sup>st</sup> and 3<sup>rd</sup> day at PRF site as compared to the PRP site. Although the postoperative pain scores were less in PRF site, this was not statistically significant among the two groups.

**Keywords:** Pain, platelet-rich fibrin, platelet-rich plasma, soft tissue healing, swelling, third molar

## INTRODUCTION

Extraction of mandibular third molar is one of the most common surgical procedures performed in oral and maxillofacial surgery, which results in pain, swelling, and bony defect. Many attempts are being made to improve the postoperative recovery and patient quality of life after third molar surgery. Although several materials have been used to minimize the postoperative sequelae, autologous graft is still considered as the gold standard.<sup>[1]</sup> One such autologous bone graft material with abundance of growth factors that gained popularity in recent years is platelet concentrates such as platelet-rich plasma (PRP) and protein-rich fibrin (PRF).<sup>[2]</sup> The earlier studies found that the growth factors present in PRF and PRP enhance the healing and improve the postoperative recovery.<sup>[3,4]</sup>

PRP is an autologous concentrate of platelets suspended in plasma, which contains vital growth factors such as platelet-derived growth factors and transforming growth factor-beta 1 and 2 and vascular endothelial growth factors, all of which positively influence the repair and regeneration of tissues.<sup>[5,6]</sup> It is prepared by a two-stage centrifugation procedure

**Address for correspondence:** Dr. Suresh Kandagal Veerabhadrapa, Faculty of Dentistry, SEGi University, No. 9 Jalan Teknologi, Taman Sains, Petaling Jaya, Kota Damansara, Selangor-47810, Malaysia.  
E-mail: dr.suri88@gmail.com

This is an open access journal, and articles are distributed under the terms of the Creative Commons Attribution-NonCommercial-ShareAlike 4.0 License, which allows others to remix, tweak, and build upon the work non-commercially, as long as appropriate credit is given and the new creations are licensed under the identical terms.

**For reprints contact:** reprints@medknow.com

**How to cite this article:** Bhujbal R, Veerabhadrapa SK, Yadav S, Chappi M, Patil V. Evaluation of platelet-rich fibrin and platelet-rich plasma in impacted mandibular third molar extraction socket healing and bone regeneration: A split-mouth comparative study. *Eur J Gen Dent* 2020;9:96-102.

**Submitted:** 26-Aug-2019

**Revised:** 31-Oct-2019

**Accepted:** 09-Apr-2020

**Published:** 29-Apr-2020

### Access this article online

Quick Response Code:



**Website:**  
www.ejgd.org

**DOI:**  
10.4103/ejgd.ejgd\_133\_19

by addition of anticoagulant or bovine thrombin that isolates the platelet concentrate. This is found to contain 6–8 times higher amount of growth factors as compared to normal blood. However, few researchers believe that the use of an anticoagulant to obtain PRP could be disadvantageous for wound healing.<sup>[7]</sup>

PRF is a next generation of platelet concentrate with autologous leukocytes, cytokines, structural glycoproteins, and a strong fibrin matrix which is prepared by simple method without adding any biochemical agent.<sup>[7]</sup> It contains leukocytes which provides adequate immunity and anti-infectious activities. In addition, the dense fibrous matrix polymerization mode of PRF creates a physiologic architecture favorable for wound healing.<sup>[8,9]</sup> Although many researchers have reported the role of PRF and PRP in wound healing of extraction sockets, we could not find any literature regarding the comparison of efficacy of PRF over PRP in split-mouth study in patients with bilateral mandibular third molar extraction cases. Hence, in this study, an attempt was made to assess the soft tissue healing, pain, swelling, and radiological bone density in patients undergoing identical bilateral third molar surgery using PRF and PRP.

## MATERIALS AND METHODS

A prospective split-mouth comparative study was conducted between June 2017 to May 2018 in the department of oral and maxillofacial surgery. The present study was a continuation of our previous research on PRP by incorporating the newer objective of comparing the effectiveness of PRF and PRP in healing of extraction socket and bone regeneration.<sup>[5]</sup>

A total of 20 patients who had identical bilateral mandibular impaction type and similar difficulty level and who agreed to come for follow-up visits were included. Written informed consent was obtained for complete diagnostic workup and extraction of third molars. The difficulty of mandibular third molar extraction was evaluated using the index given by Pederson,<sup>[10]</sup> and the extraction with the same difficulty level was included in both the groups.

Digital panoramic radiographs were taken pre- and postoperatively. PRF was placed on the right side of the third molar extraction socket, and PRP was placed on the left side. Postoperative evaluation of soft tissue healing, pain, swelling, and radiological bone density was carried out. Healthy patients (American Society of Anesthesiologists I and II) and patients with similar difficulty level of impacted mandibular third molars were included in the study.

### Exclusion criteria

- Patients with localized infection in the region of lower third molars
- Patients with immune compromised status or systemic disease which might affect normal healing process
- Patients with adverse oral habits such as smoking and alcohol
- Patients with platelet count <150,000/cu.mm and history of bleeding disorder

- Patient taking any medication that influences the healing.

Preparation of PRF was carried out according to the technique described by Dohan *et al.* in clinical setting and immediately placed in the socket area.<sup>[11]</sup>

Under aseptic techniques, 6 ml of blood was drawn intravenously from the antecubital region of patients using flashback blood collection needle and BD Vacutainer without anticoagulant. The collected blood was centrifuged at 3000 rpm for 10 min. The resultant product consisted of following three layers:

- Top most layer consisted of acellular platelet-poor plasma (PPP)
- PRF clot in the middle
- Red blood cells (RBCs) at the bottom.

The topmost layer of PPP was discarded. PRF and the uppermost layer of RBCs were isolated and used in extraction socket.

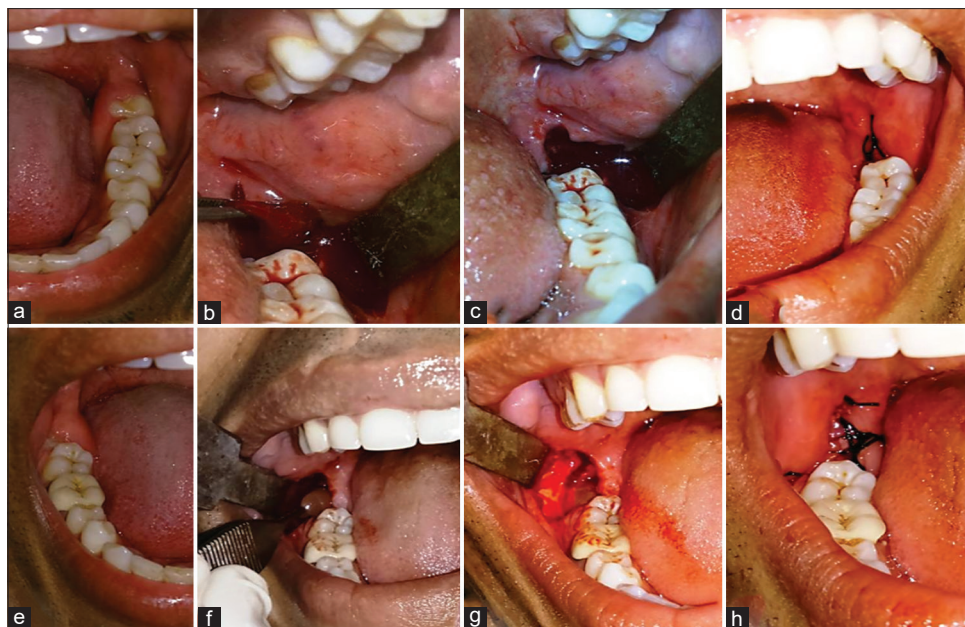
### Preparation of platelet-rich plasma

PRP is prepared by a process known as differential centrifugation. In differential centrifugation, acceleration force is adjusted to sediment certain cellular constituents based on different specific gravity.<sup>[12]</sup>

Six milliliters of intravenous blood was collected in BD Vacutainer containing citrate phosphate dextrose adenine solution and centrifuged at 1200 rpm for 10 min. The result was separation of the whole blood into a lower RBC region and upper straw-colored plasma. This plasma contains relatively low concentration of platelets in the uppermost region and higher concentration of platelets in the boundary layer often called as “buffy coat.” PPP, buffy coat, and upper 1 ml RBC layer was collected in a borosilicate glass tube and centrifuged at 2000 rpm for 10 min. The upper half of the supernatant was discarded, and the lower half was mixed to yield PRP and transferred into a clean sterile stainless-steel bowl, and 0.5–1 ml of 10% calcium chloride was added to the PRP, leading to formation of PRP gel.

### Surgical technique for the removal of bilateral impacted mandibular third molar

Under aseptic precautions, 2% lignocaine hydrochloride with 1:200,000 adrenaline was administered using the conventional inferior alveolar nerve block to anesthetize the mandibular third molar area. A mucoperiosteal flap was raised after the standard classical ward incision. Bone on the buccal and the distal aspect of the impacted tooth was removed using a round bur. Odontectomy was done whenever required to facilitate extraction. The impacted tooth was removed using the elevators, and sharp bony edges were removed. The extraction socket was irrigated with 0.5% diluted povidone iodine and saline. Complete hemostasis was achieved, and primary wound closure was done using 3-0 black silk by interrupted sutures [Figure 1]. Standard postextraction instructions along with the antibiotics (capsule amoxicillin 500 mg TDS for 5 days) and analgesics (tablet diclofenac 50 mg BD for 3 days) were prescribed. The operator and examiners were blinded. All the



**Figure 1:** Photograph showing steps of surgical removal of left and right impacted third molars and placement of platelet-rich plasma and PRF. (a) Left impacted third molar socket, (b) platelet-rich plasma being placed in the third molar socket, (c) platelet-rich plasma in the socket, (d) wound closed with 3-0 black silk interrupted sutures. (e) Right impacted third molar, (f) PRF being placed in the third molar socket, (g) PRF in the socket, (h) wound closed with 3-0 black silk interrupted sutures

extractions were carried out by single experienced oral surgeon using the same sets of sterilized equipment in all extractions. Postoperative measurement of soft tissue healing, pain, and swelling was performed by another experienced oral surgeon.

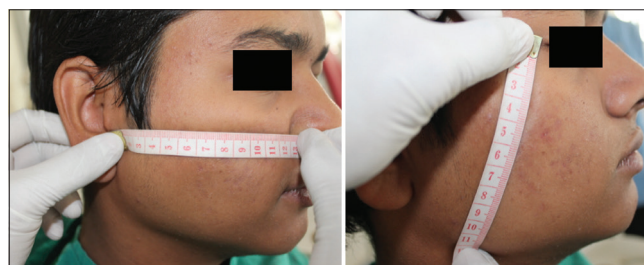### Postoperative measurement of soft tissue healing, pain, and swelling

The soft tissue healing, pain, and swelling were measured on immediate postoperative and on the 1<sup>st</sup>, 3<sup>rd</sup>, and 7<sup>th</sup> postoperative days. Soft tissue healing was assessed as per the healing index given by Landry *et al.*<sup>[13]</sup> The parameters evaluated include the change of tissue color more than 50% gingival red, bleeding on palpation, and granulation tissue formation.

Pain intensity was assessed using a 10-level visual analog scale (VAS) with the patient placing a mark on the scale to indicate an intensity range from no pain (0) to severe/unbearable pain (10).

Pre- and post-operative swelling was assessed using a flexible plastic millimeter measuring tape. The permanent markings were made prior to surgery on the following facial landmarks, lower attachment of the ear lobe, ala of the nose, outer canthus of the eye, and angle of the mandible. The horizontal dimension of swelling was measured from the lower attachment of the ear lobe to the ala of the nose, and the vertical dimension of swelling was measured from the outer canthus of the eye to the angle of the mandible using the measuring tape [Figure 2].

The facial measurement was made preoperatively and on the 1<sup>st</sup>, 3<sup>rd</sup>, and 7<sup>th</sup> days postoperatively. The measurement of swelling was determined by subtracting postoperative facial measurement from preoperative facial measurement



**Figure 2:** Photograph showing horizontal and vertical measurement of face

and calculating the percentage swelling to rule out individual differences in facial dimension.

Bone density was assessed using digital panoramic radiograph (Orthopantomography) on the 3<sup>rd</sup> and 6<sup>th</sup> months postoperatively. The mean gray-level histogram values of the OPG of the extraction socket were obtained through adobe Photoshop 7.0 software, Adobe Inc. San Jose, California, U.S.

Procedure: The scanned OPG image was imported to adobe Photoshop 7.0, and histogram tool in software was selected to draw the outline of the socket. The cursor was placed at the center of the socket and the mean value of the selected area was recorded. The difference in the mean gray-level values at PRF and PRP sites was tabulated and compared [Figure 3].

## RESULTS

The present study consisted of total 20 patients, of which 7 (35%) were male and 13 (65%) were female patients, with a mean age of 22 years [Table 1].

### Assessment of soft tissue healing

At the PRF site, there were no patients with tissue color more than 50% gingival red, bleeding on palpation, or granulation tissue formation on the 1<sup>st</sup>, 3<sup>rd</sup>, and 7<sup>th</sup> postoperative days. At the PRP site, tissue color more than 50% red was present in two patients on the 1<sup>st</sup> day, bleeding on palpation was present in two patients on the 1<sup>st</sup> day, and granulation tissue was present in one patient on the 7<sup>th</sup> day. Soft tissue healing was significantly better in PRF site compared to PRP site [Table 2].

### Assessment of pain by visual analog scale

Immediate postoperative evaluation showed mean pain score of 1.9 in PRF site and 2.3 in PRP site, 1.8 in PRF site and 2.3 in PRP site on the 1<sup>st</sup> day, 2.2 in PRF site and 2.7 in PRP site on the 3<sup>rd</sup> day, and on the 7<sup>th</sup> day the score was 0 in PRF site and 0.1 in PRP site. Postoperative pain scores were less in PRF site as compared to PRP site; however, Mann–Whitney U-test showed no significant difference between both the groups on immediate postoperative period ( $P < 0.15$ ) and on the 1<sup>st</sup> day ( $P < 0.96$ ), 3<sup>rd</sup> day ( $P < 0.58$ ), and 7<sup>th</sup> day ( $P < 0.78$ ) [Table 3].

### Assessment of swelling

On the 1<sup>st</sup> day, the mean dimension of swelling was 9.83 cm in PRF site and 9.92 cm in PRP site. On the 3<sup>rd</sup> day, it was 9.92 in PRF site 10.06 in PRP site. On the 7<sup>th</sup> day, it was 9.68 in PRF site and 9.68 in PRP site. Significant reduction of the swelling was found in PRF site on the 1<sup>st</sup> day ( $P < 0.0020$ ) and 3<sup>rd</sup> day ( $P < 0.0010$ ); however, the facial measurements recorded on the 7<sup>th</sup> day showed no statistically significant differences between the two groups ( $P < 1.00$ ) [Table 4].

### Radiological assessment

The mean bone density score on the 3<sup>rd</sup> month in PRF site was 135.16 and in PRP site was 132.49 and on the 6<sup>th</sup> month in PRF site was 140.57 and PRP site was 135.92. Significant improvement in bone density in PRF site was noticed on the 3<sup>rd</sup> month ( $P < 0.00001$ ) and 6<sup>th</sup> month ( $P < 0.00001$ ) postoperatively [Table 5].

Gender	Number of patients (%)	Mean age	SD
Male	7 (35)	26.43	7.44
Female	13 (65)	25.77	6.89
Total	20 (100)	26.00	6.90

SD: Standard deviation

### DISCUSSION

Healing is a complex biological process which involves participation of many cells and growth factors. The platelets are activated by coagulation cascade, particularly thrombin and subendothelial collagen. These platelets contain several growth factors, which stimulates biological functions such as chemotaxis, angiogenesis, proliferation, differentiation, and modulation, which affects the wound healing and regeneration. The application of autologous PRP in oral and maxillofacial surgery was popularized by Marx.<sup>[14]</sup>

PRP and PRF are the autologous concentrates of platelets predominately used in oral and maxillofacial surgery and periodontology to enhance the healing process and to minimize the potential postoperative complications.<sup>[14-16]</sup> Earlier research suggested that the platelet-rich concentrates have optimistic effects to jump start the cascade of osteogenesis by providing vital growth factors, bone morphogenetic proteins, and early consolidation of the graft, all of which accelerate the mineralization of the graft.<sup>[17]</sup> In addition, platelet concentrates may be used alone or in combination with bone grafts such as calcium sulfate hemihydrate as a socket preservation material and for the treatment of periodontal bony defects.

Soft tissue healing was assessed as per the healing index given by Landry *et al.*,<sup>[13]</sup> on the 1<sup>st</sup>, 3<sup>rd</sup>, and 7<sup>th</sup> postoperative days after placement of PRF and PRP. The soft tissue healing was superior at PRF site than PRP site on all postoperative days. These results were supported by Yelamali and Saikrishna<sup>[18]</sup> who noticed a significant difference in the PRF site as compared to PRP site. Doiphode *et al.*<sup>[19]</sup> found no evidence of wounds dehiscence in PRF site as compared to control and PRP site. This signifies

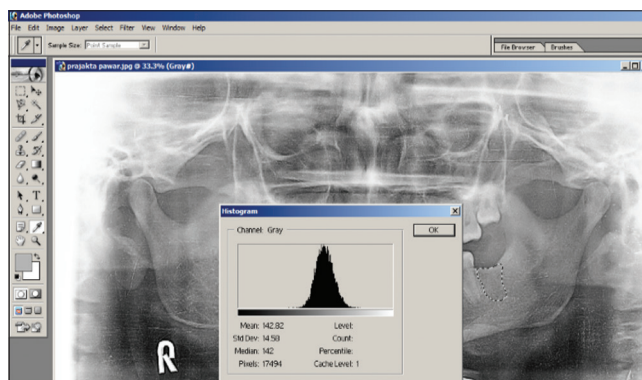


Figure 3: OPG showing gray-level histogram on a left third molar extraction socket

Table 2: Comparison of PRF and PRP site with tissue color more than 50% gingival red, bleeding on palpation, and granulation tissue

Groups	Tissue color >50% gingival red			Bleeding on palpation			Granulation tissue		
	1 <sup>st</sup> day	3 <sup>rd</sup> day	7 <sup>th</sup> day	1 <sup>st</sup> day	3 <sup>rd</sup> day	7 <sup>th</sup> day	1 <sup>st</sup> day	3 <sup>rd</sup> day	7 <sup>th</sup> day
PRF site	0	0	0	0	0	0	0	0	0
PRP site	2	0	0	2	0	0	0	0	1

PRP: Platelet-rich plasma, PRF: Platelet-rich fibrin

**Table 3: Comparison of PRF and PRP site with respect to visual analog scale scores at immediate postoperative after local anesthesia worn off, 1<sup>st</sup> day, 3<sup>rd</sup> day, and 7<sup>th</sup> day by Mann-Whitney U-test**

Groups	Immediate postoperative		1 <sup>st</sup> day		3 <sup>rd</sup> day		7 <sup>th</sup> day		Changes from immediate postoperative to					
									1 <sup>st</sup> day		3 <sup>rd</sup> day		7 <sup>th</sup> day	
	Mean	SD	Mean	SD	Mean	SD	Mean	SD	Mean	SD	Mean	SD	Mean	SD
PRF	1.9	0.9	1.8	0.7	2.2	0.7	0.0	0.0	0.1	0.9	-0.3	1.1	1.9	0.9
PRP	2.3	0.7	2.3	0.8	2.7	1.0	0.1	0.2	0.0	1.0	-0.5	1.2	2.2	0.8
Percentage of change in PRF site									5.3%#	P=0.6241	13.2%#	P=0.3259	100.0%#	P=0.0001*
Percentage of change in PRP site									03.0%#	P=0.9687	20.0%#	P=0.1235	97.8%#	P=0.0001*
Z	-1.4066		-1.6636		-1.8935		-0.2705		-0.0541		-0.4463		-1.1902	
P	0.1596		0.0962		0.0583		0.7868		0.9569		0.6554		0.2340	

\*P<0.05, #Applied Wilcoxon matched pairs test. PRP: Platelet-rich plasma, SD: Standard deviation

**Table 4: Comparison of PRF and PRP site with respect to vertical swelling (cm) scores at immediate preoperative, 1<sup>st</sup> day, 3<sup>rd</sup> day, and 7<sup>th</sup> day by paired t-test**

Groups	Immediate preoperative		1 <sup>st</sup> day		3 <sup>rd</sup> day		7 <sup>th</sup> day		Changes from immediate preoperative to					
									1 <sup>st</sup> day		3 <sup>rd</sup> day		7 <sup>th</sup> day	
	Mean	SD	Mean	SD	Mean	SD	Mean	SD	Mean	SD	Mean	SD	Mean	SD
PRF	9.68	0.93	9.83	0.95	9.92	0.95	9.68	0.93	0.15	0.08	0.24	0.11	0.00	0.00
PRP	9.68	0.93	9.92	0.98	10.06	0.96	9.68	0.93	0.24	0.09	0.38	0.14	0.00	0.00
Percentage of change in PRF site									1.5%#	P=0.0001*	2.5%#	P=0.0001*	0.0%#	-
Percentage of change in PRP site									2.5%#	P=0.0001*	3.9%#	P=0.0001*	0.0%#	-
t	0.0000		-0.2941		-0.4634		0.0000		-3.3275		-3.5835		-	
P	1.0000		0.7703		0.6457		1.0000		0.0020*		0.0010*		-	

\*P<0.05, #Applied paired t-test. PRP: Platelet-rich plasma, SD: Standard deviation

**Table 5: Comparison of PRF and PRP site with respect to bone density scores at 3<sup>rd</sup> and 6 months by paired t-test**

Groups	3 months		6 months		Changes from 3 <sup>rd</sup> day to			
					3 months		6 months	
	Mean	SD	Mean	SD	Mean	SD	Mean	SD
PRF	135.16	4.41	140.57	4.52	8.09	2.56	13.50	2.58
PRP	132.49	4.36	135.92	4.34	4.46	1.26	7.89	1.39
Percentage of change in PRF site					6.4%#	P=0.0001*	10.6%#	P=0.0001*
Percentage of change in PRP site					3.5%#	P=0.0001*	6.2%#	P=0.0001*
t		1.9269		3.3147		5.6937		8.5485
P		0.0615		0.0020*		0.00001*		0.00001*

\*P<0.05, #Applied paired t-test. PRP: Platelet-rich plasma, SD: Standard deviation

a better soft tissue healing of extraction sockets with PRF as compared to the PRP. In contrast, Dutta *et al.*<sup>[20]</sup> reported slightly better soft tissue healing in PRP site compared to PRF site on the 3<sup>rd</sup> day, 7<sup>th</sup> day, and 14<sup>th</sup> day postoperatively; however, there was no statistical significant difference between the two groups.

This is due the fact that PRF clot forms a strong fibrin matrix with a complex × 3-dimensional architecture which dissolves slowly similar to the natural blood clot and it also releases growth factors in more controlled manner over long term.

Furthermore, it is an autologous soluble biologic material which is prepared without the addition of any foreign bodies; hence, it prevents the consequent foreign-body inflammatory responses.<sup>[21,22]</sup> The postoperative pain was assessed using VAS on immediate postoperatively and on the 1<sup>st</sup>, 3<sup>rd</sup>, and 7<sup>th</sup> postoperative days. Although the pain scores were relatively lesser on postoperative days in PRF site, these scores were not statistically significant. This was in accordance with the study by Unakalkar *et al.*,<sup>[23]</sup> who also reported no significant differences between PRF and PRP sites. However, contrast

findings were reported by Daugela *et al.*,<sup>[24]</sup> and Dutta *et al.*<sup>[20]</sup> noticed a significant reduction of pain on the 1<sup>st</sup> postoperative week in PRF site as compared to PRP site. The accurate assessment of pain in split-mouth design would be difficult as there is overlapping of pain due to the carry-across effect from one site to another site in this study design.

Assessment of swelling was carried out on the 1<sup>st</sup> day, 3<sup>rd</sup> day, and 7<sup>th</sup> day postoperatively. The mean dimension of swelling was significantly lesser on the 1<sup>st</sup> day and 3<sup>rd</sup> day on PRF site, which was statistically significant. However, on the 7<sup>th</sup> day, no significant changes were observed in both the sites. PRF may provide significant reduction of swelling in shorter time compared to PRP. These findings were supported by Daugela *et al.*,<sup>[24]</sup> who noticed significant reduction of facial swelling on the 1<sup>st</sup> and 3<sup>rd</sup> postoperative days in PRF which ceases to nonsignificant at day 7. Dutta *et al.*<sup>[20]</sup> reported a significant reduction of swelling on PRF site on the 3<sup>rd</sup>, 7<sup>th</sup>, and 14<sup>th</sup> day postoperatively. In contrast, a study by Unakalkar *et al.*<sup>[23]</sup> observed slightly better reduction of swelling in PRP group than PRF group on the 7<sup>th</sup> postoperative day. However, these findings were nonsignificant in both the groups.

The mean bone density scores were recorded at the 3<sup>rd</sup> month and 6<sup>th</sup> month using digital panoramic radiographs. Statistically significant difference was found in PRF site on the 3<sup>rd</sup> and 6<sup>th</sup> months. This finding was in accordance with the study by Yelamali and Saikrishna,<sup>[18]</sup> they noticed that the mean values of bone density in PRF group were significantly higher than PRP group. Similar findings were observed by Dutta *et al.*:<sup>[20]</sup> bone healing index was significantly higher in PRF site on the 1<sup>st</sup> month, 3<sup>rd</sup> month, and 6<sup>th</sup> month. The autologous growth factors present in PRF have stronger and more durable effect on proliferation and differentiation of osteoblasts.<sup>[25]</sup>

This signifies the use of PRF over other platelet concentrates as it releases the growth factors at a sustained rate over a longer period, thereby optimizing wound healing.<sup>[26,27]</sup> The main advantage of PRF is that it is prepared naturally without addition of thrombin, and it is hypothesized that PRF has a natural fibrin framework and can protect growth factors from proteolysis. Thus, growth factors can keep their activity for a relatively longer period and stimulate bone regeneration effectively.<sup>[28]</sup> The limitations of the present split-mouth study include small sample size and absence of control group as it was difficult to recruit the cases with bilateral impacted teeth with similar difficulty level. In addition, the inclusion and exclusion criteria of our study further resulted in difficulty in enrolling the cases. The present study was done with a follow-up of 6 months which was adequate to evaluate the effects of PRF and PRP. However, further histological studies to evaluate the bone and randomized trials are required to check the efficacy of these platelet concentrates to get conclusive results.

## CONCLUSION

Our results showed a significant improvement in the soft tissue wound healing and increase in bone density in PRF

site. Although the postoperative pain scores were less and reduction of swelling was noticed in initial days in PRF site, this was not significant between two groups. This clearly signifies that the PRF has better hard and soft tissue healing properties than PRP.

## Ethical approval

The ethical clearance was obtained from the institutional ethical committee and written informed consent was taken from the patient for complete diagnostic workup and extraction of mandibular third molar. Patient consent was also obtained for publication of their data.

## Financial support and sponsorship

Nil.

## Conflicts of interest

There are no conflicts of interest.

## REFERENCES

- Misch CM. Autogenous bone: Is it still the gold standard? *Implant Dent* 2010;19:361.
- Al-Hamed FS, Mahri M, Al-Waeli H, Torres J, Badran Z, Tamimi F. Regenerative effect of platelet concentrates in oral and craniofacial regeneration. *Front Cardiovasc Med* 2019;6:126.
- de Sousa Gomes P, Daugela P, Poskevicius L, Mariano L, Fernandes MH. Molecular and cellular aspects of socket healing in the absence and presence of graft materials and autologous platelet concentrates: A focused review. *J Oral Maxillofac Res* 2019;10:e2.
- Simonpieri A, Del Corso M, Vervelle A, Jimbo R, Inchingolo F, Sammartino G, *et al.* Current knowledge and perspectives for the use of platelet-rich plasma (PRP) and platelet-rich fibrin (PRF) in oral and maxillofacial surgery part 2: Bone graft, implant and reconstructive surgery. *Curr Pharm Biotechnol* 2012;13:1231-56.
- Fortier LA, Barker JU, Strauss EJ, McCarrel TM, Cole BJ. The role of growth factors in cartilage repair. *Clin Orthop Relat Res* 2011;469:2706-15.
- Bhujbal R, A Malik N, Kumar N, Kv S, I Parkar M, Mb J. Comparative evaluation of platelet rich plasma in socket healing and bone regeneration after surgical removal of impacted mandibular third molars. *J Dent Res Dent Clin Dent Prospects* 2018;12:153-8.
- Miron RJ, Fujioka-Kobayashi M, Bishara M, Zhang Y, Hernandez M, Choukroun J. Platelet-rich fibrin and soft tissue wound healing: A systematic review. *Tissue Eng Part B Rev* 2017;23:83-99.
- Preeja C, Arun S. Platelet-rich fibrin: Its role in periodontal regeneration. *Saudi J Dent Res* 2014;5:117-22.
- Nehls V, Herrmann R. The configuration of fibrin clots determines capillary morphogenesis and endothelial cell migration. *Microvasc Res* 1996;51:347-64.
- Koerner KR. The removal of impacted third molars. Principles and procedures. *Dent Clin North Am* 1994;38:255-78.
- Dohan DM, Choukroun J, Diss A, Dohan SL, Dohan AJ, Mouhyi J, *et al.* Platelet-rich fibrin (PRF): A second-generation platelet concentrate. Part I: technological concepts and evolution. *Oral Surg Oral Med Oral Pathol Oral Radiol Endod* 2006;101:e37-44.
- Sweeny J, Grossman BJ. Blood collection, storage and component preparation methods. In: Brecher M, editor. *Technical Manual*. 14<sup>th</sup> ed. Bethesda, MD: American Association of Blood Banks; 2002. p. 955-8.
- Landry RG, Turnbull RS, Howley T. Effectiveness of benzydiamine HCL in the treatment of periodontal post-surgical patients. *Res Clin Forums* 1988;10:105-18.
- Ogundipe OK, Ugboko VI, Owotade FJ. Can autologous platelet-rich plasma gel enhance healing after surgical extraction of mandibular third molars? *J Oral Maxillofac Surg* 2011;69:2305-10.
- Célio-Mariano R, de Melo WM, Carneiro-Avelino C. Comparative radiographic evaluation of alveolar bone healing associated with

- autologous platelet-rich plasma after impacted mandibular third molar surgery. *J Oral Maxillofac Surg* 2012;70:19-24.
16. Fennis JP, Stoelting PJ, Jansen JA. Mandibular reconstruction: A histological and histomorphometric study on the use of autogenous scaffolds, particulate cortico-cancellous bone grafts and platelet rich plasma in goats. *Int J Oral Maxillofac Surg* 2004;33:48-55.
  17. Marx RE, Carlson ER, Eichstaedt RM, Schimmele SR, Strauss JE, Georgeff KR. Platelet-rich plasma: Growth factor enhancement for bone grafts. *Oral Surg Oral Med Oral Pathol Oral Radiol Endod* 1998;85:638-46.
  18. Yelamali T, Saikrishna D. Role of platelet rich fibrin and platelet rich plasma in wound healing of extracted third molar sockets: A comparative study. *J Maxillofac Oral Surg* 2015;14:410-6.
  19. Doiphode AM, Hegde P, Mahindra U, Santhosh Kumar SM, Tenglikar PD, Tripathi V. Evaluation of the efficacy of platelet-rich plasma and platelet-rich fibrin in alveolar defects after removal of impacted bilateral mandibular third molars. *J Int Soc Prev Community Dent* 2016;6:S47-52.
  20. Dutta SR, Passi D, Singh P, Sharma S, Singh M, Srivastava D. A randomized comparative prospective study of platelet-rich plasma, platelet-rich fibrin, and hydroxyapatite as a graft material for mandibular third molar extraction socket healing. *Natl J Maxillofac Surg* 2016;7:45-51.
  21. Dohan Ehrenfest DM, Del Corso M, Diss A, Mouhyi J, Charrier JB. Three-dimensional architecture and cell composition of a Choukroun's platelet-rich fibrin clot and membrane. *J Periodontol* 2010;81:546-55.
  22. Tsay RC, Vo J, Burke A, Eisig SB, Lu HH, Landesberg R. Differential growth factor retention by platelet-rich plasma composites. *J Oral Maxillofac Surg* 2005;63:521-8.
  23. Unakalkar S, Bhushan K, Sahu R. Comparison of the efficacy of platelet-rich fibrin with platelet-rich plasma in third molar extraction socket – A prospective clinical study. *Int J Oral Care Res* 2018;6:S44-9.
  24. Daugela P, Grimuta V, Sakavicius D, Jonaitis J, Juodzbalsys G. Influence of leukocyte- and platelet-rich fibrin (L-PRF) on the outcomes of impacted mandibular third molar removal surgery: A split-mouth randomized clinical trial. *Quintessence Int* 2018;49:377-88.
  25. He L, Lin Y, Hu X, Zhang Y, Wu H. A comparative study of platelet-rich fibrin (PRF) and platelet-rich plasma (PRP) on the effect of proliferation and differentiation of rat osteoblasts *in vitro*. *Oral Surg Oral Med Oral Pathol Oral Radiol Endod* 2009;108:707-13.
  26. Blair P, Flaumenhaft R. Platelet alpha-granules: Basic biology and clinical correlates. *Blood Rev* 2009;23:177-89.
  27. Sharma A, Pradeep AR. Autologous platelet-rich fibrin in the treatment of mandibular degree II furcation defects: A randomized clinical trial. *J Periodontol* 2011;82:1396-403.
  28. Lundquist R, Dziegiel MH, Agren MS. Bioactivity and stability of endogenous fibrogenic factors in platelet-rich fibrin. *Wound Repair Regen* 2008;16:356-63.