

Central giant cells lesion: Report of a conservative management

Marina Rolo Pinheiro da Rosa¹, Juliana Lopes de Sá², Valber Barbosa Martins³,
Marcelo Vinícius de Oliveira³

¹Resident of Oral and Maxillofacial Surgery, Department of Oral and Maxillofacial Surgery, Amazon State University, Manaus, Brazil,

²Dentistry Student, Department of Oral and Maxillofacial Surgery, Amazon State University, Manaus, Brazil,

³Professor at the Residence in Maxillofacial and Traumatology Surgery, Department of Oral and Maxillofacial Surgery, Amazon State University, Manaus, Brazil

Correspondence: Marina Rolo Pinheiro da Rosa
Email: marinarolo@hotmail.com

ABSTRACT

Central giant cells lesion (CGCL) is defined as a benign intraosseous destructive pathology. It is classified as aggressive or nonaggressive, depending on their clinical, imaginologic, and histological behavior. The behavior, location, and extension of the lesion added to the patient's age will determine the choice of the treatment, either surgical or clinical. Thereby, the aim of this work is to review the literature related to the CGCL, as well as to present a clinical case report of a 22-year-old female patient, affected with an injury on the left side of her jaw. After the diagnosis, it was decided to carry out a conservative treatment with intralesional injections of triamcinolone (10 mg/ml). The injections were performed once a week for 6 weeks. The progress of the patient was satisfactory, and after 4 years, it has been observed through imaging and clinical bone formation examinations with complete remission of the injury and no signs of recurrence.

Key words: Adrenal cortex hormones, central giant cells granuloma, giant cells, maxillofacial injuries

INTRODUCTION

Central giant cell lesion (CGCL) is defined by the World Health Organization as an "intraosseous lesion" formed by fibrous tissue that contains multiple focus of hemorrhage, aggregation of multinucleated giant cells, and occasionally presents tissue trabeculae of immature bone.^[1]

CGCL is an intraosseous pathology that corresponds to 7% of nonneoplastic jaw injury cases^[2] and can usually be found in the jaw and mandible,^[3,4] but

it can also affect extragnathic bones, being mostly bones present in the craniofacial region and small bones and long bones, such as on the hands and feet.^[5,6]

The main areas affected by CGCL are those support of the previous teeth that can extend to the first permanent molar region.^[7-9] As for the site of predilection in the gnathic bones, CGCL is more common in the mandible

This is an open access journal, and articles are distributed under the terms of the Creative Commons Attribution-NonCommercial-ShareAlike 4.0 License, which allows others to remix, tweak, and build upon the work non-commercially, as long as appropriate credit is given and the new creations are licensed under the identical terms.

For reprints contact: reprints@medknow.com

How to cite this article: Pinheiro da Rosa MR, de Sá JL, Martins VB, de Oliveira MV. Central giant cells lesion: Report of a conservative management. Eur J Dent 2018;12:305-10.

DOI: 10.4103/ejd.ejd_402_17

Access this article online	
Quick Response Code: 	Website: www.eurjdent.com

than in the maxilla,^[3,4,10,11] with a jaw/maxilla ratio of 2:1,^[3,8] 3:1,^[12] and even 4:1.^[13] In the case of the group age, it affects mostly children or young adults under 30 years of age, most likely in the female gender.^[3,8,11,12,14]

CGCL is considered a destructive lesion of variable size and rate of progression. Based on the clinical and radiographic features, Chuong *et al.* classified the lesion as nonaggressive, which consist in the majority of cases, or aggressive. The nonaggressive form exhibits slow growth, usually asymptomatic, it does not pierce the cortical bone and it does not induce root resorption, presenting low rates of relapse after treatment. The aggressive form of the lesion is less common and characterized by faster growth, showing a higher rate of recurrence, a greater tendency for root resorption, and painful symptomatology.^[10] For Kruse-Lösler *et al.*, (2006)^[14] the combination of clinical parameters with histomorphometric analysis may be useful for the classification of giant cell central granulomas in aggressive and nonaggressive lesions.^[14] The injury may expand over the maxilla, invading the floor of the maxillary sinus, orbit, or even the nasal cavity. Moreover, in the jaw, when it expands, it can penetrate the cortical bone, displacing teeth, and reabsorbing roots.^[15]

On examination of the images, most CGCL appears as an extensive radiolucent defect, which may be unilocular or multilocular,^[3,8,11] which is usually pierced by bone spicules.^[1] The lesion margins have been reported in the literature as well defined in 56% of cases, poorly defined in 30%, and diffuse in 14%.^[3] It is worth mentioning that the radiographic features of the injury are not pathognomonic signs and may be confused with several other maxillary injuries. Small unilocular injuries may be confused with periapical granulomas or cysts, and multilocular injuries cannot be distinguished radiographically from ameloblastomas or other multilocular injuries.^[1,8]

Histologically, the presence of multinucleated giant cells in a fund of ovoid or fusiform mesenchymal cells and rounded macrophages are common in all injuries. It has been reported a variability in the size and shape of giant cells,^[14] which may be locally aggregated, or may be diffusely present throughout the lesion.^[8] The aggressive and nonaggressive form of the CGCL exhibits similar histological characteristics, although aggressive injuries are correlate, with larger giant cells.^[10]

CGCL is histopathologically identical to cherubism, sometimes to the brown tumor of hyperparathyroidism

and to the aneurysmal bone cyst. Because of this, the pathologist cannot predict the prognosis of the injury,^[10] and clinical parameters, especially the size of the tumor should be assessed.^[14] Hyperparathyroidism should be discarded in all cases,^[8] being performed routine examinations for evaluation of calcium, phosphorus, and parathyroid rates.^[16]

The traditional treatment of CGCL in the jaws consists of the surgical removal of the injury^[17] followed or not by curettage and blocking bone resection. There are a few reported cases, in which curettage has been supplemented with cryosurgery^[18] or with peripheral osteotomy.^[19] Other alternative treatments include radiation and systemic calcitonin therapies,^[20-22] and effective treatment with corticosteroid intralesional injection has been mentioned.^[4,23-30] The treatment chosen will depend on clinical parameters of CGCL, such as aggressive or nonaggressive behavior, location, size, and radiographic appearance, and in cases of lesion recurrence, there may be a combination of one or more therapeutic interventions.

CASE REPORT

Patient A. M. R. 22-year-old, leukoderma, female, attended the Dental Polyclinic with referral for evaluation of possible lesion in a mandibular body region, left side, identified by radiographic examination of the jaws. The patient reports that she had been undergoing orthodontic treatment for about 3 years. The patient agreed to submit to the appointments and norms of the institution through the informed consent term.

During the anamnesis, the patient did not present any changes in the systems revision or underlying disease. She also did not report any painful symptomatology or phlogistic sign in the lesion region, denying any previous surgical intervention at the site. On an extraoral physical examination, there was a slight facial asymmetry in the lower third of the face. On intraoral physical examination, there was a slight volume increase on the left side region of the mandibular body and angle, suggesting expansion of the cortical bone. Absence of oral mucosal continuity solution was observed as well as other alterations.

Computed tomography (CT) scanning revealed a hypodense multilocular lesion in the left mandibular body (first molar region), compromising the mandibular ramus, and extending the mandible head region and coronoid process on the same side [Figure 1].

An incisional biopsy of the lesion was performed, in which a descriptive report of central lesion of giant cells was obtained. The microscopic report of the incisional biopsy indicated that histological sections stained by hematoxylin and eosin showed areas constituted by vascular proliferation in a loose stroma amid the presence of chronic inflammatory infiltrate with predominance of plasma cells and the presence of multinucleated giant cells with nuclei arranged in an orderly fashion peripherally and others with central nuclei [Figure 2].

To conclude the diagnosis, the patient underwent complementary laboratory tests to distinguish histopathologically similar pathologies similar to CGCL.

Due to the size of the lesion, the age of the patient, morbidity, possible damages to nearby noble structures and economic factors, a less invasive treatment was chosen when compared to the bone resection.

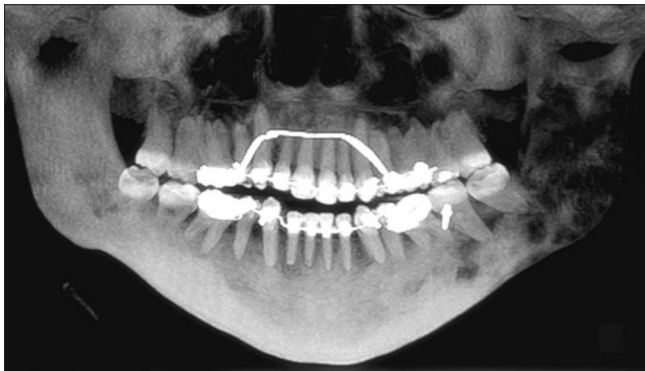


Figure 1: Computed tomography panoramic reconstruction evidencing a multilocular hypodense area compromising the left mandibular ramus and extending to condyle and coronoid process

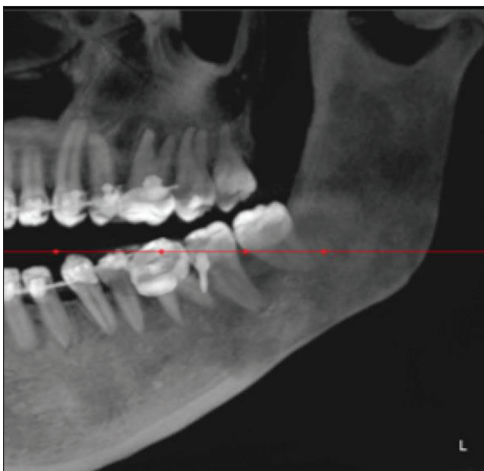


Figure 3: The left mandibular region after 5 months of intralesional corticoid therapy showing local increased bone density

According to the protocol proposed by Terry and Jacoway, the conservative treatment was based on intralesional injections of triamcinolone (10 mg/ml) associated with lidocaine 2% and epinephrine 1:200,000. The infiltrations were 2 ml of solution every 2 cm of radiolucency of the lesion.^[23] Weekly applications were carried out for 6 consecutive weeks, once a week.

After 5 months, new imaging tests were performed, where the lesion reduction was observed, almost in its entirety [Figure 3].

After 4 years of therapy, there was an increase in bone density in the region, with total remission of the lesion and absence of clinical and radiographic signs of relapse [Figure 4].

DISCUSSION

CGCL is an uncommon neoplastic lesion accounting for <7% of all benign tumors of the jaw.^[2] It is most commonly reported in female patients under the age of 30,^[3,11-14] a fact reinforced by the report described. The literature further confirms that the mandible is often more affected than the maxilla,^[3,4,10,13] generally

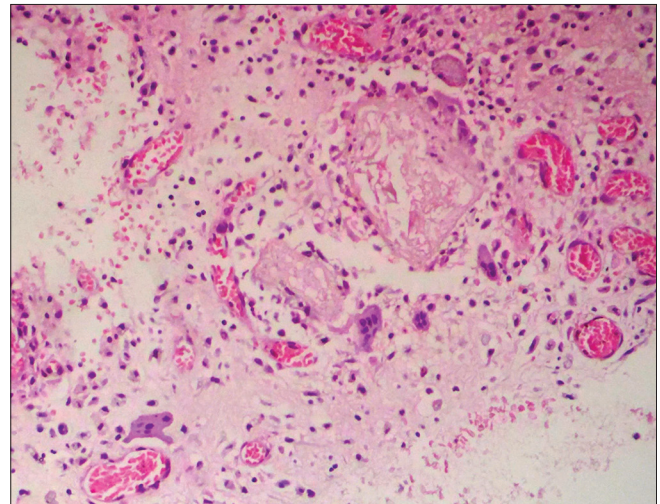


Figure 2: Chronic inflammatory infiltrate with predominance of plasma cells and the presence of multinucleated giant cells

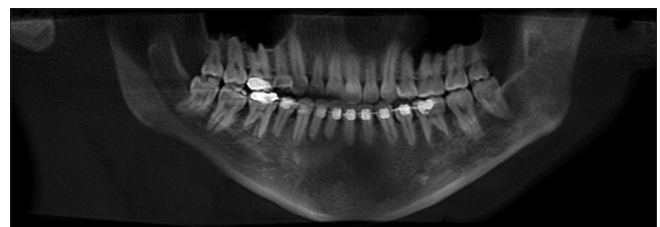


Figure 4: Computed tomography panoramic view evidencing remission of the lesion after 4 years of therapy

crossing the midline.^[8,31] In the present case, the lesion was evidenced comprising body, mandibular branch, condyle, and coronoid process; however, remained only in the left hemiface, not crossing the midline.

Asymptomatic lesions may go unidentified for years. Neville *et al.* state that most GCCGs are usually detected on a routine radiographic examination or due to painless bone expansion.^[8] The clinical case is consistent with this statement since the patient did not report painful symptoms and did not present important clinical alterations in the lesion region, being diagnosed in a radiographic examination requested for orthodontic treatment. This fact makes the course of lesion growth doubtful because it cannot predict the exact onset of CGCL. In cases of symptomatic lesions, patients may present mainly pain, dental mobility, and accelerated growth of the lesion.^[19]

Chuong *et al.* and Kramer *et al.* (1991) classified CGCL as aggressive or nonaggressive according to the difference in the clinical behavior of the lesion, such as symptomatology, growth, involvement of adjacent teeth, cortical bone perforation, and relapse rates. The present clinical case, after being diagnosed, despite its extension, was classified as nonaggressive because it did not present painful symptoms, perforation of the cortical bone, or involvement of adjacent teeth.

The analysis of the clinical behavior of CGCL is of great importance for the diagnosis of the lesion. Histopathological examinations are considered to be less specific and may not be used as a reliable method for predicting the clinical course of the lesion.^[14] Other pathologies may present histopathological features similar to the CGCL, such as aneurysmal bone cyst, brown tumor of hyperparathyroidism, GCT, and cherubism.^[32] Therefore, further examination is required to complete the diagnosis. Laboratory tests to obtain the blood level of calcium, phosphorus, ionized calcium, and parathyroid can distinguish CGCL from the brown tumor of hyperparathyroidism. In the present case, laboratory tests did not show any changes, which led to discarding such hypothesis.

Histopathological examination revealed the presence of plasma cells in a loose stroma with vascular proliferation, with multinucleated giant cells. These characteristics confirm the findings of Kruse-lösler *et al.* and Eckardt *et al.*^[14,33] The authors further state that aggressive and nonaggressive behavioral CGCLs exhibit very similar histological findings; however, aggressive lesions differ histopathologically with a

greater number of uni or multinucleated giant cells. Fact disagreed by Chuong *et al.*, which assure that there are no histological differences between the aggressive and nonaggressive types of the lesion.^[10] Studies are performed to understand the true meaning of this cell type.^[32] The literature shows a current consensus that such cells have intermediate characteristics of osteoclasts and macrophages.^[31] Neville *et al.* still claim that there is evidence that giant cells represent osteoclasts.^[8]

The radiographic characteristics of the CGCL are not considered pathognomonic, leading the professional to a series of diagnostic hypotheses. As radiographic findings of the reported clinical case, it is emphasized that the lesion exhibited a multilocular and radiolucent form, breaking the cortical bone in some points but respecting its limits.

These findings corroborate with authors who confirm that the radiographic features of CGCL generally consist of a multilocular or, to a lesser extent, unilocular radiolucency.^[8,11-13] Studies reveal that extensive lesions may involve the roots of the teeth adjacent to the affected area, leading to its displacement,^[3,11,29] which did not occur in the case described, since despite the extension of the lesion in the patient's mandible, there was no dental involvement. It is worth highlighting, in a unique way, the importance of an imaging examination that provides detailed data, such as CT, which shows the real extent and location of the lesion, loss of vestibular and lingual bone cortices, and accurately demonstrate the proximity of the lesion with adjacent noble anatomical structures.^[15] With these data, it is also easier to diagnose the aggressiveness of the lesion.^[10,15] CT was of paramount importance in the present clinical case since it allowed to delimit the lesion in its true extension, and after the start of treatment, the lesion regression was accurately followed.

The most appropriate treatment modality of CGCL is much discussed in the literature. Among the different types of treatments proposed, the choice of therapy will depend on the age of the patient, clinical characteristics of the lesion, and its aggressiveness.^[24] In addition to these parameters, patient collaboration, economic factors, and time between the beginning of the treatment and clinical response. The traditional treatment of CGCL is surgical excision, either by enucleation or by curettage.^[12,29] Reports from the literature state that cases can be treated with simple curettage without the need for bone grafts;^[17] however, some authors confirm the need for complementation of the curettage with cryotherapy, to reduce the rates

of recurrence of the lesion, especially when it comes to the aggressive form.^[18] There are also other treatments complementary to the surgical treatment, which include peripheral ostectomy, Carnoy's solution, liquid nitrogen, and cryotherapy.^[22,34]

For Kruse-lösler *et al.*, curettage followed by conservative peripheral ostectomy is a common procedure for the treatment of CGCL. The author also emphasizes that the advantages of this conservative surgical procedure in the long term give the patient minimal morbidity; there are maximum tissue preservation and a rapid identification in the case of recurrence.^[14]

Alternatives to surgical treatment, noninvasive treatment of CGCL have become more common in the literature. To regress or even eliminate the lesion, these therapies have been indicated mainly in young patients who present extensive lesions that can lead to invasive and mutilating procedures.

The use of calcitonin has been advocated for cases where there was a complete reduction of the lesion without signs of relapse.^[21] Due to the duration of the treatment, 20 months on average, the use of calcitonin becomes restricted for multiple, recurrent, or aggressive lesions.^[22] Particularly, the application of calcitonin in the treatment of children should be avoided because it is not only long lasting but also causes discomfort in patients.^[19] It is believed that multinucleated giant cells present in CGCL have calcitonin receptors, and therefore, its growth can be controlled.^[22] In contrast, it is accepted that calcitonin does not promote healing of the lesion but rather a stabilization or regression of lesion size.^[35] Aggressive lesions that recur after calcitonin treatment may be treated by excision.^[20]

Intralesional injections of corticosteroids may also be used as a treatment for CGCL. This technique offers advantages to the patient, low cost, avoids compromising vital structures, and if necessary, it is possible to treat the lesion surgically in the future after its regression.^[4,28] The treatment of choice, in the reported clinical case, was with intralesional injections of triamcinolone (10 mg/ml), following the protocol recommended by Terry and Jacoway, which includes injections once every week for 6 weeks. Accompanied by examinations performed by CT, the treatment resulted in the remission of the lesion. There are authors who also confirm the efficacy of intralesional injections in their work,^[4,24,26-28] including Abdo *et al.*, who reported a failure curettage with a rapid recurrence of the lesion, followed

by an excellent intralesional injection result in a 14-year-old patient.^[25] However, the small drawbacks of this technique include the inconvenience of at least 6 weekly visits.^[4] Nevertheless, in comparison to the other treatment modalities, intralesional corticosteroid injection can be chosen as the first form of treatment of CGCL, emphasizing its benefits to the patient, avoiding serious mutilation in patients with extensive lesions, and preserving vital noble structures adjacent to the lesion.^[26,27]

There is still in the literature, treatment of CGCL by the administration of interferon alpha (INF- α). The use of INF- α subcutaneous route is based on the belief that CGCL is a proliferative vascular lesion, which, therefore, responds to this type of therapy.^[22] Nevertheless, continuous administration of INF- α has its questionable effect, being it is also necessary to associate another alternative treatment.^[36] The use of radiotherapy as a treatment was not advocated by any author and is contraindicated due to the potential for sarcomatous transformation reported.^[19,29]

Recurrence rates vary substantially in the literature, reported in a rate of 11%–49% of cases.^[12,21] The jaw lesions present a greater number of recurrences in the mandible and the aggressive form of the lesion presents a higher propensity of recurrence after the treatment.^[10,14,19,21] Authors affirm that there is a high tendency to recurrence of the lesion associated with younger patients.^[12,21] In the case reported in this study, at 4 years of follow-up, the patient did not show signs of relapse of the lesion.

CONCLUSION

Knowledge of the clinical, histopathological, and imaging characteristics of CGCL is extremely important for any professional to be able to make a differential diagnosis when encountering these types of intraosseous lesions. The choice of appropriate therapy for the treatment of CGCL depends mainly on the age of the patient, the clinical characteristics of the lesion, its aggressiveness, and socioeconomic factors. In comparison to surgical methods, intralesional injection presents the main advantage of avoiding possible sequelae for the patient. Other benefits of this treatment include low cost, convenience, less invasive nature and preservation of noble structures.

Declaration of patient consent

The authors certify that they have obtained all appropriate patient consent forms. In the form the patient(s) has/have

given his/her/their consent for his/her/their images and other clinical information to be reported in the journal. The patients understand that their names and initials will not be published and due efforts will be made to conceal their identity, but anonymity cannot be guaranteed.

Acknowledgment

The authors would like to thank the patient and workmates who took part in this study.

Financial support and sponsorship

Nil.

Conflicts of interest

There are no conflicts of interest.

REFERENCES

- Kramer IR, Pindborg JJ, Shear M. Histological Typing of Odontogenic Tumors. 2nd ed. Berlin: Springer-Verlag; 1991. p. 31.
- Austin LT Jr., Dahlin DC, Royer RQ. Giant-cell reparative granuloma and related conditions affecting the jawbones. *Oral Surg Oral Med Oral Pathol* 1959;12:1285-95.
- Kaffe I, Ardekian L, Taicher S, Littner MM, Buchner A. Radiologic features of central giant cell granuloma of the jaws. *Oral Surg Oral Med Oral Pathol Oral Radiol Endod* 1996;81:720-6.
- Kurtz M, Mesa M, Alberto P. Treatment of a central giant cell lesion of the mandible with intralesional glucocorticosteroids. *Oral Surg Oral Med Oral Pathol Oral Radiol Endod* 2001;91:636-7.
- Yamaguchi T, Dorfman HD, Eisig S. Cherubism: Clinicopathologic features. *Skeletal Radiol* 1999;28:350-3.
- Boedeker CC, Kayser G, Ridder GJ, Maier W, Schipper J. Giant-cell reparative granuloma of the temporal bone: A case report and review of the literature. *Ear Nose Throat J* 2003;82:926-9, 933-4, 936-7.
- Kauzman A, Li SQ, Bradley G, Bell RS, Wunder JS, Kandel R, *et al.* Central giant cell granuloma of the jaws: Assessment of cell cycle proteins. *J Oral Pathol Med* 2004;33:170-6.
- Neville BW, Damm DD, Allen CM, Bouquot JE. *Oral and Maxillofacial Pathology*. 3rd ed. Rio de Janeiro: Elsevier; 2009.
- Waldron CA, Shafer WG. The central giant cell reparative granuloma of the jaws. An analysis of 38 cases. *Am J Clin Pathol* 1966;45:437-47.
- Chuong R, Kaban LB, Kozakewich H, Perez-Atayde A. Central giant cell lesions of the jaws: A clinicopathologic study. *J Oral Maxillofac Surg* 1986;44:708-13.
- Cohen MA, Hertzanu Y. Radiologic features, including those seen with computed tomography, of central giant cell granuloma of the jaws. *Oral Surg Oral Med Oral Pathol* 1988;65:255-61.
- Whitaker SB, Waldron CA. Central giant cell lesions of the jaws. *Oral Surg Oral Med Oral Pathol Oral Radiol Endod* 1993;75:199-208.
- Sidhu MS, Parkash H, Sidhu SS. Central giant cell granuloma of jaws – Review of 19 cases. *Br J Oral Maxillofac Surg* 1995;33:43-6.
- Kruse-Lösler B, Diallo R, Gaertner C, Mischke KL, Joos U, Kleinheinz J, *et al.* Central giant cell granuloma of the jaws: A clinical, radiologic, and histopathologic study of 26 cases. *Oral Surg Oral Med Oral Pathol Oral Radiol Endod* 2006;101:346-54.
- Bodner L, Bar-Ziv J. Radiographic features of central giant cell granuloma of the jaws in children. *Pediatr Radiol* 1996;26:148-51.
- Katz A, Hirschl S. Giant cell reparative granuloma in the temporal bone. *Arch Otolaryngol* 1974;100:380-2.
- Üstündağ E, Iseri M, Keskin G, Müezzinoğlu B. Central giant cell granuloma. *Int J Pediatr Otorhinolaryngol* 2002;65:143-6.
- Webb DJ, Brockbank J. Combined curettage and cryosurgical treatment for the aggressive “giant cell lesion” of the mandible. *Int J Oral Maxillofac Surg* 1986;15:780-85.
- Bataineh AB, Al-Khateeb T, Rawashdeh MA. The surgical treatment of central giant cell granuloma of the mandible. *J Oral Maxillofac Surg* 2002;60:756-61.
- Harris M. Central giant cell granulomas of the jaws regress with calcitonin therapy. *Br J Oral Maxillofac Surg* 1993;31:89-94.
- de Lange J, Rosenberg AJ, van den Akker HP, Kooole R, Wirlds JJ, van den Berg H, *et al.* Treatment of central giant cell granuloma of the jaw with calcitonin. *Int J Oral Maxillofac Surg* 1999;28:372-6.
- Pogrel MA. Calcitonin therapy for central giant cell granuloma. *J Oral Maxillofac Surg* 2003;61:649-53.
- Terry BC, Jacoway JR. Management of central giant cell lesion: An alternative to surgical therapy. *Oral Maxillofac Surg Clin North Am* 1994;6:579-600.
- Carlos R, Sedano HO. Intralesional corticosteroids as an alternative treatment for central giant cell granuloma. *Oral Surg Oral Med Oral Pathol Oral Radiol Endod* 2002;93:161-6.
- Abdo EN, Alves LC, Rodrigues AS, Mesquita RA, Gomez RS. Treatment of a central giant cell granuloma with intralesional corticosteroid. *Br J Oral Maxillofac Surg* 2005;43:74-6.
- Kermer C, Millesi W, Watzke IM. Local injection of corticosteroids for central giant cell granuloma. A case report. *Int J Oral Maxillofac Surg* 1994;23:366-8.
- Nogueira RL, Teixeira RC, Cavalcante RB, Ribeiro RA, Rabenhosrt SH. Intralesional injection of triamcinolone hexacetonide as an alternative treatment for central giant-cell granuloma in 21 cases. *Int J Oral Maxillofac Surg* 2010;39:1204-10.
- Rajeevan NS, Soumithran CS. Intralesional corticosteroid injection for central giant cell granuloma. A case report. *Int J Oral Maxillofac Surg* 1998;27:303-4.
- Adornato MC, Paticoff KA. Intralesional corticosteroid injection for treatment of central giant-cell granuloma. *J Am Dent Assoc* 2001;132:186-90.
- Ferretti C, Muthray E. Management of central giant cell granuloma of mandible using intralesional corticosteroids: Case report and review of literature. *J Oral Maxillofac Surg* 2011;69:2824-9.
- Vered M, Buchner A, Dayan D. Immunohistochemical expression of glucocorticoid and calcitonin receptors as a tool for selecting therapeutic approach in central giant cell granuloma of the jawbones. *Int J Oral Maxillofac Surg* 2006;35:756-60.
- Lange J, Akker HP. Clinical and radiological features of central giant-cell lesions of the jaw. *Oral Surg Oral Med Oral Pathol Oral Radiol Endod*. 2005; 99: 464-70.
- Eckardt A, Pogrel MA, Kaban LB, Chew K, Mayall BH. Central giant cells granuloma of the jaws. *Int J Oral Maxillofac Surg* 1989;18:3-6.
- Eisenbud L, Stern M, Rothberg M, Sachs SA. Central giant cell granuloma of the jaws: Experiences in the management of thirty-seven cases. *J Oral Maxillofac Surg* 1988;46:376-84.
- O'Regan EM, Gibb DH, Odell EW. Rapid growth of giant cell granuloma in pregnancy treated with calcitonin. *Oral Surg Oral Med Oral Pathol Oral Radiol Endod* 2001;92:532-8.
- Lange J, Akker HP, Berg H, Richel DJ, Gortzak RA. Limited regression of central giant cell granuloma by interferon alpha failed calcitonin therapy: A report of 2 cases. *Int J Oral Maxillofac Surg* 2006; 35: 865-9.