

A Rare Case of Right Trigeminal Neuralgia Due to Dural Arteriovenous Fistula

Abstract

Trigeminal neuralgia (TGN) is often caused by a neurovascular conflict at the root entry zone of the fifth nerve. Dural arteriovenous fistula (DAVF) accounts for 3%–4% cases of TGN. We report a posttraumatic head injury patient, presenting with gait ataxia and right facial pain. Radiographic evidence with magnetic resonance imaging and digital subtraction angiography was suggestive of DAVF. Surgical clipping and obliteration of fistula alleviated the TGN.

Keywords: Arterialized dural petrosal vein, clipping and microvascular decompression, digital subtraction angiography, dural arteriovenous fistula, meningo-hypophyseal trunk, trigeminal neuralgia

**Sagar Ghodasara,
Rohit
Balasubramanian,
Santhosh
Poyyamoli¹**

Departments of Neurosurgery and ¹Interventional Radiology, Kovai Medical Center and Hospitals, Coimbatore, Tamil Nadu, India

Introduction

Trigeminal neuralgia (TGN) is a recurrent, unilateral, transient, and intense electric shock-like lancinating pain along the distribution of the fifth nerve. It is abrupt in onset and triggered by innocuous tactile stimuli. Studies have demonstrated that 80%–90% of primary TGN cases are induced by vascular compression of the fifth nerve at the root entry zone (REZ), especially by the superior cerebellar artery and anterior inferior cerebellar artery. Dural arteriovenous fistula (DAVFs) causing TGN are rare and only few cases have been reported in literature. For DAVFs, an endovascular approach with transvenous embolization may be a constructive strategy of treatment depending on the pattern of venous drainage. However, if endovascular embolization is technically not feasible, surgical intervention is indicated. Here, we report a rare case and its pertinent management with surgical obliteration of the venous outflow of DAVF.

Case Report

A 60-years old male presented with complaints of sudden onset right-sided facial pain for 3 days with a history of difficulty in walking, gradually worsening over a year. He had sustained severe traumatic brain injury 3 years ago, for which

he underwent a bilateral frontoparietal decompressive craniectomy followed by a cranioplasty, shortly after. However, he developed a subdural hygroma for which a tapping via a burr hole was initially done, followed by a right subduroperitoneal shunt for persistent hygroma with mass effect.

The patient complained of sudden onset, lancinating right facial pain, especially over the right lower lip and mandible, each ordeal lasting for 30 s. A detailed neurological examination revealed hypersensitivity at V2 and V3 divisions of the fifth nerve [Figure 1], along with spastic quadriparesis noted on motor examination. A magnetic resonance imaging of the brain was done which revealed multiple flow voids in the left cerebellum, along the left tentorium, and cerebellar surface of the brain stem, extending along the spinal cord. Patchy enhancement was seen along the cervical spinal cord with multiple prominent perimedullary veins up to the conus level and dilated tortuous right inferior hypophyseal trunk [Figure 2]. A digital subtraction angiography (DSA) was done which showed right DAVF surrounding the cisternal segment of the right trigeminal nerve with arterial supply from the meningo-hypophyseal trunk–single feeder branch artery and venous drainage through the superior petrosal vein into the superior petrosal sinus [Figure 3].

Address for correspondence:

Dr. Rohit Balasubramanian,
OPD No. 13, Kovai Medical
Center and Hospitals, 99
Avinash Road, Civil Aerodrome
Post, Coimbatore - 641 014,
Tamil Nadu, India.

E-mail: rohitstanley@yahoo.com

Access this article online

Website: www.asianjns.org

DOI: 10.4103/ajns.AJNS_93_20

Quick Response Code:



How to cite this article: Ghodasara S, Balasubramanian R, Poyyamoli S. A rare case of right trigeminal neuralgia due to dural arteriovenous fistula. *Asian J Neurosurg* 2021;16:174-7.

Submitted: 16-Mar-2020

Revised: 11-Apr-2020

Accepted: 06-May-2020

Published: 23-Feb-2021

This is an open access journal, and articles are distributed under the terms of the Creative Commons Attribution-NonCommercial-ShareAlike 4.0 License, which allows others to remix, tweak, and build upon the work non-commercially, as long as appropriate credit is given and the new creations are licensed under the identical terms.

For reprints contact: WKHLRPMedknow_reprints@wolterskluwer.com

Table 1: Studies showing dural arteriovenous fistulas in relation to the trigeminal nerve

Series	Lesion	Location	Relationship to trigeminal nerve	Treatment	Results
Harders <i>et al.</i> (1982)	DAVF	Transverse sigmoid sinus	Dysplastic petrosal vein compressing trigeminal nerve	MVD + surgery (coagulation of dura + isolation of lateral and sigmoid sinuses)	Anatomical and clinical cure (after 3 surgeries)
Mendelowitsch <i>et al.</i> (1990)	DAVF	Tentorial	Dysplastic draining vein compressing trigeminal REZ	Endovascular treatment (6 times) + surgery and intraoperative embolization	Clinical cure (transient trochlear nerve palsy)/residual DAVF
Ott <i>et al.</i> (1993)	DAVF	Tentorial	Dysplastic basal vein of rosenthal running along trigeminal REZ	Endovascular treatment	Clinical cure (16 months follow up)
Ito <i>et al.</i> (1996)	DAVF	Petro-tentorial	Draining vein and superior cerebellar artery compressing trigeminal REZ	Endovascular treatment + surgery 2 months	Anatomical and clinical cure (20 months follow up)
Lucas <i>et al.</i> (1997)	DAVF	Transverse-sigmoid sinus	Dysplastic petrosal vein (Dandy's vein)	Sinus skeletonization	Anatomical and clinical cure
Du <i>et al.</i> (2003)	DAVF	Superior petrosal sinus	Veins adjacent to Gasserian ganglion	Endovascular treatment	Clinical cure (but concomitant facial hypalgesia)

MVD – Microvascular decompression; DAVF – Dural arteriovenous fistula; REZ – Root entry zone

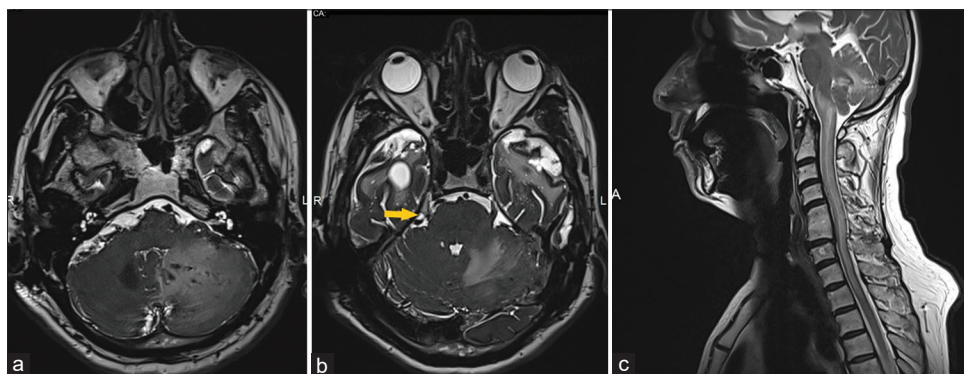


Figure 1: (a) Preoperative magnetic resonance imaging: Axial T2 SPACE image at the level of inferior pons showing ill-defined vasogenic edema with multiple microbleeds involving the left cerebellum with extension to the middle cerebellar peduncle. (b) Preoperative magnetic resonance imaging: Arrow indicates tortuous hypertrophied vascular channel at the right fifth nerve root entry zone. (c) Preoperative magnetic resonance imaging: Sagittal T2 image of the cervical spine showing long segment cord signal changes with prominent perimedullary veins

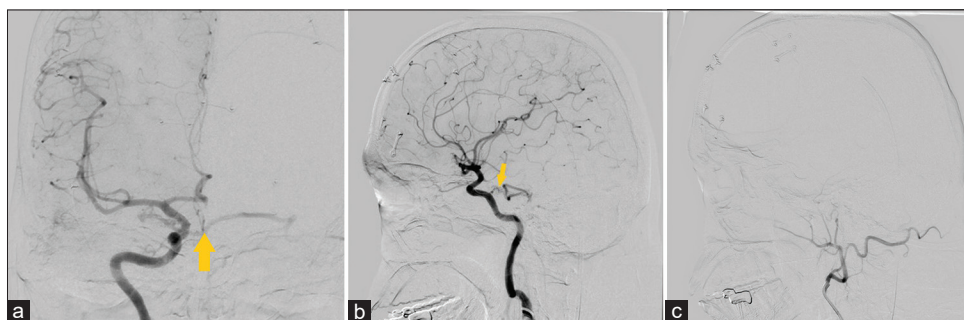


Figure 2: (a) Preoperative digital subtraction cerebral angiogram of the right internal carotid artery in anteroposterior projection shows cognard Type 5 dural arteriovenous fistula (arrow) supplied by the meningohypophyseal trunk with venous drainage into the tentorial vein and perimedullary veins. (b) Preoperative digital subtraction angiography, lateral projection of the internal carotid artery shows dural arteriovenous fistula marked by arrow. (c) Preoperative digital subtraction angiography: Right external carotid angiogram in lateral projection shows the absence of external carotid artery feeders

As the internal carotid artery was the exclusive source and the feeder vessel could not be cannulated because of its small caliber, endovascular access was not possible. The patient was taken up for surgery. He underwent right retromastoid-retrosigmoid suboccipital craniotomy and

clipping of fistulous arterialized right tentorial vein (that was indenting the cisternal segment of the fifth nerve) along with right microvascular decompression (MVD) of the fifth nerve. Postoperatively, the patient had immediate relief from facial pain. Follow-up [Figure 4] DSA after

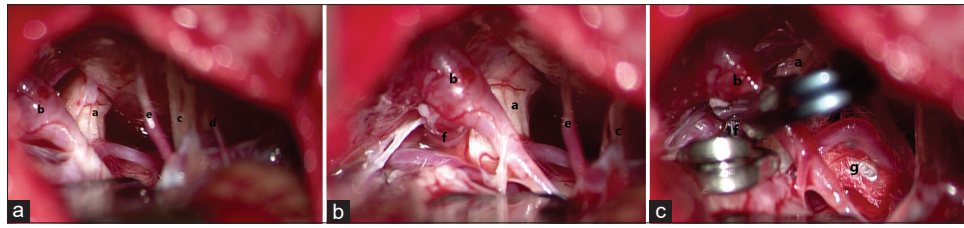


Figure 3: (a and b) Intraoperative image: (a) Trigeminal nerve. (b) Arterialized superior petrosal vein. (c) Seventh and eighth nerve complex. (d) Labyrinthine artery. (e) Subarcuate artery. (f) Fistulous vein curving around the fifth nerve. (g) Pledget between the fifth nerve and the fistulous vein. (c) Intraoperative image: (a) Trigeminal nerve. (b) Arterialized superior petrosal vein. (c) Seventh and eighth nerve complex. (d) Labyrinthine artery. (e) Subarcuate artery. (f) Fistulous vein curving around the fifth nerve. (g) Pledget between the fifth nerve and the fistulous vein. Showing clipped fistulous vein by curved sugita clip and superior petrosal vein by straight clip

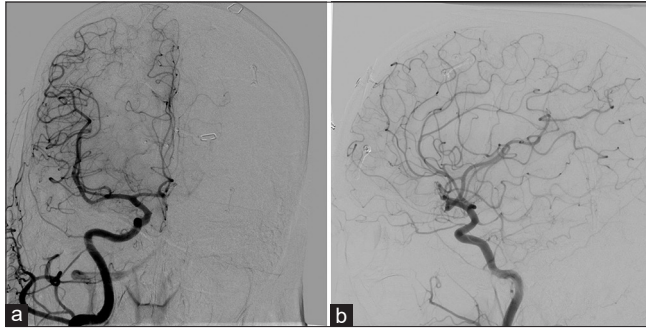


Figure 4: Postoperative digital subtraction cerebral angiogram of the right common carotid artery in anteroposterior projection shows complete obliteration of fistula. (b) Postoperative digital subtraction cerebral angiogram of the right common carotid artery in lateral projection shows complete obliteration of fistula

1 week showed complete obliteration of the fistula. On follow-up, the patient was able to walk with support with no facial pain.

Discussion

DAVFs are acquired disease. Developmental anomalies of DAVF is a rare disease, found only in pediatric group, usually associated with dural sinus malformation.^[1] Many DAVFs are usually secondary to adjacent dural venous sinus thrombosis, while others may be associated with trauma. There are three major categories of DAVFs associated with trauma – (I) those that develop at the site of the injury, (II) those that develop remote from the site of the injury, and (III) those that are incidentally observed during the evaluation of the injury.

While complete surgical resection is an ideal option for patients with a history of hemorrhage, complete surgical resection may be limited due to the risks associated with certain locations of the fistula.^[2,3] Ott *et al.*^[4] reported a case of TGN caused by a DAVF that was successfully treated with transarterial embolization. However, some other studies^[5] report a poor outcome, unless combined with surgical intervention [Table 1]. Transarterial embolization has gained popularity as the first-line treatment in DAVF, along with a transvenous or combined approach.^[6] Some have claimed that the treatment of DAVFs in the tentorial and torcular regions with transarterial embolization is

temporarily beneficial but rarely curative.^[7,8] Another study reported ten cases of DAVF associated with TGN draining into the superior petrosal vein.^[9]

In this study, transarterial embolization was used primarily as an adjunct to decrease flow to the DAVF prior to the definitive treatment. The author emphasizes that those DAVFs that drain purely through leptomeningeal veins can be safely obliterated by surgically clipping the arterialized draining vein.^[9] Occlusion of the sinus and the draining vein was attempted only if the venous flow was retrograde to avoid venous hypertension or venous infarction.^[9] Superior petrosal sinus DAVFs are technically difficult to occlude via either transarterial or transvenous methods. One series demonstrated that 22% (4 of 18) of patients were able to be treated with endovascular therapy alone. The remaining DAVFs were treated with a combination of endovascular intervention and open surgery.^[10] Although several therapeutic approaches have been described, endovascular therapy is more constantly employed in these cases. Here, the endovascular treatment produced pain remission with no recurrence. Still, the optimum treatment in Trigeminal neuralgia (TN) due to DAVF remains unclear.^[11]

Conclusion

In our case, the presence of an exclusive internal carotid artery supply precluded the safe endovascular option of closing the fistula. Hence, surgical clipping with MVD was done. Although there was an enlarged fistulous vein indenting the fifth nerve REZ, there was constant flow through the fistula. Postoperatively, the patient improved well symptomatically, with remission of pain without any recurrence on follow-up. The success of the DAVF obliteration was confirmed and documented on a postoperative DSA.

Declaration of patient consent

The authors certify that they have obtained all appropriate patients consent forms. In the form the patients have given their consent for images and other clinical information to be reported in the journal. The patients understand that their names and initials will not be published and due efforts will be made to conceal their identity, but anonymity cannot be guaranteed.

Financial support and sponsorship

Nil.

Conflicts of interest

There are no conflicts of interest.

References

1. Awad IA. Dural arteriovenous malformations. In: Spetzler RF, editor. Neurovascular Surgery. New York: McGraw-Hill; 1995. p. 905-32.
2. Yuan Y, Zhang Y, Luo QI, Yu J. Trigeminal neuralgia caused by brain arteriovenous malformations: A case report and literature review. *Exp Ther Med* 2016;12:69-80.
3. Lucas Cde P, Zabramski JM. Dural arteriovenous fistula of the transverse-sigmoid sinus causing trigeminal neuralgia. *Acta Neurochir (Wien)* 2007;149:1249-53.
4. Ott D, Bien S, Krasznai L. Embolization of a tentorial dural arterio-venous fistula presenting as atypical trigeminal neuralgia. *Headache* 1993;33:503-8.
5. Ito M, Sonokawa T, Mishina H, Iizuka Y, Sato K. Dural arteriovenous malformation manifesting as tic douloureux. *Surg Neurol* 1996;45:370-5.
6. Gandhi D, Chen J, Pearl M, Huang J, Gemmete JJ, Kathuria S. Intracranial dural arteriovenous fistulas: Classification, imaging findings, and treatment. *AJNR Am J Neuroradiol* 2012;33:1007-13.
7. Barnwell SL. Endovascular therapy of dural arteriovenous malformations. In: Barrow DL, editor. *Dural Arteriovenous Malformations*. Park Ridge: AANS Publications; 1993. p. 193-211.
8. Mullan S. Reflections upon the nature and management of intracranial and intraspinal vascular malformations and fistulae. *J Neurosurg* 1994;80:606-16.
9. Liu JK, Dogan A, Ellegala DB, Carlson J, Nesbit GM, Barnwell SL, *et al.* The role of surgery for high-grade intracranial dural arteriovenous fistulas: Importance of obliteration of venous outflow. *J Neurosurg* 2009;110:913-20.
10. Ng PP, Halbach VV, Retal Q. Endovascular treatment for dural arteriovenous fistulae of the superior petrosal sinus. *Neurosurgery* 2003;53:25-32.
11. Rodriguez M, Cano M. Tentorial dural arteriovenous malformation manifesting as trigeminal neuralgia treated by endovascular therapy: Case report. *Rev Mexicana Neurociencia* 2016;17:116-23.