

EC-IC Bypass; Our Experience of Cerebral Revascularization with Intraoperative Dual-Image Video Angiography (Diva)

Abstract

Background: Extracranial-intracranial (EC-IC) arterial bypass has been used in the treatment of various cerebrovascular ischemic disease due to atherosclerosis or Moyamoya disease, skull base tumors encasing large IC artery or complex IC aneurysms. **Aim:** The aim is to analyze surgical technique (EC-IC bypass) and its outcome with intraoperative use of dual image video angiography (DIVA) and Doppler ultrasound. **Materials and Methods:** We studied in this article a series of 23 patients operated in Banbuntane Hotokukai Hospital, Fujita Health University, for which a superficial temporal artery-middle cerebral artery anastomosis was done for steno-occlusive disease, giant IC aneurysm or Moyamoya disease. The study was conducted between 2018 and 2020. We used dual-image video angiography (DIVA) and Doppler ultrasound to assess the luminal patency of anastomosis during the procedure. **Results:** In this study, three patients presented with Moyamoya disease, 4 had aneurysm, whereas 16 patients presented with the vascular steno-occlusive disease. The patients were divided into three categories (steno-occlusive disease, Moyamoya, and flow replacement for giant aneurysm). Dual image video angiography, along with intraoperative Doppler, helped us in the assessment of luminal patency of the anastomosis. **Conclusion:** Hemodynamic recovery after cerebrovascular bypass brings about a better outcome in ischemic stroke. The result of surgery improves with proper selection of patients with hemodynamic impairment (in Stage 2). With various modalities such as intraoperative Doppler, DIVA (Dual-image Video Angiography) and improved surgical techniques may aid in the reduction of complications and improve clinical outcome.

Keywords: Cerebrovascular bypass, cerebrovascular ischemia, dual image video angiography, intraoperative Doppler ultrasound

Girish Joshi^{1,2},
Yasuhiro Yamada¹,
Binoy Damodar
Thavara^{1,3},
Riki Tanaka¹,
Kyosuke Miyatini¹,
Kazutaka Nakao¹,
Tsukasa Kawase¹,
Katsumi Takizava¹,
Yoko Kato¹

¹Department of Neurosurgery, Fujita Health University Bantane Hospital, Nagoya, Aichi, Japan, ²Department of Neurosurgery, Government Medical College, Thrissur, Kerala, ³Department of Neurosurgery, Apollo Specialty Hospital, Bengaluru, Karnataka, India

Introduction

Extracranial-intracranial (EC-IC) arterial bypass has been used in the treatment of various cerebrovascular ischemic disease due to atherosclerosis or Moyamoya disease, skull base tumors encasing large IC artery or complex IC aneurysms requiring trapping and distal revascularization. The first cerebrovascular bypass between the superficial temporal artery (STA) and cortical middle cerebral artery (MCA) was performed by Dr. Yasagil. The methods of intraoperative monitoring to check luminal patency of bypass has evolved significantly in recent times. In this review of the literature, the author will discuss the evolution of the bypass surgeries and our experience with 23 cases in the past 2 years.

Materials and Methods

Twenty-three consecutive patients who underwent STA-MCA bypass surgery during 2 years in Fujita Health University, Banbuntane Hotokukai Hospital (January 2018 to January 2020). All the data were provided by the senior author. Patients were evaluated preoperatively using computed tomography (CT) perfusion scan to establish a better analysis of cerebral blood flow (CBF) for patients who were candidates for bypass revascularization surgery. Intraoperative monitoring for bypass patency was done using Doppler ultrasound and DIVA (dual-image video angiography). Postoperative assessment of bypass patency was made with CT cerebral angiogram.

This is an open access journal, and articles are distributed under the terms of the Creative Commons Attribution-NonCommercial-ShareAlike 4.0 License, which allows others to remix, tweak, and build upon the work non-commercially, as long as appropriate credit is given and the new creations are licensed under the identical terms.

For reprints contact: WKHLRPMedknow_reprints@wolterskluwer.com

How to cite this article: Joshi G, Yamada Y, Thavara BD, Tanaka R, Miyatini K, Nakao K, et al. EC-IC Bypass; Our experience of cerebral revascularization with intraoperative Dual-Image Video Angiography (Diva). *Asian J Neurosurg* 2020;15:499-506.

Submitted: 26-Mar-2020 **Revised:** 07-Apr-2020
Accepted: 04-Jun-2020 **Published:** 28-Aug-2020

Address for correspondence:

Dr. Girish Joshi,
Department of Neurosurgery,
Apollo Specialty Hospital,
Jayanagar 3rd Block,
Near Madhavan Park,
Bengaluru - 560 011,
Karnataka, India.
E-mail: doctorgirishjoshi@gmail.com

Access this article online

Website: www.asianjns.org

DOI: 10.4103/ajns.AJNS_84_20

Quick Response Code:



Surgical technique of superficial temporal artery-middle cerebral artery bypass

Illustrative case

A 40-year-old female presented to hospital with multiple transient ischemic attacks (TIA) due to left MCA stenosis. The preoperative radiological study showed severe left MCA stenosis. Single-photon emission CT (SPECT) showed reduced CBF in the left MCA territory.

The patient was operated in the supine position with the head turned to the right with a slight extension. STA was located using a Doppler probe. Left frontotemporal curvilinear incision was done. We use handheld Doppler to identify STA donor vessels during subcutaneous dissection. It avoids inadvertent injury to the donor vessel [Figure 1].

Donor STA is mobilized from the root, long enough to reach MCA recipient branches without avulsion [Figure 2].

The temporal muscle was divided under the STA [Figure 3], dissected and retracted inferiorly to expose the frontotemporal area, and a frontotemporal bone flap was removed.

After performing the craniotomy, the duratomy was done. Cortical branches of the Left MCA exiting from the Sylvian fissure were identified [Figure 4]. Left cortical M4 branches were mobilized and their arachnoid coverings were coagulated and cut to allow mobilization. The left STA artery was clamped distally and cut for mobilization toward MCA cortical branches [Figure 5]. Before performing the anastomosis, cortical M4 MCA branches are visualized with intraoperative video indocyanine green (ICG) for luminal patency [Figures 6 and 7].

The left STA was prepared as a donor vessel, an appropriate length was mobilized after putting a temporary clip at the root of the STA and cut. The soft tissue was removed from the temporal artery on its last 1 cm. The extremity was prepared as a fish mouth and marked with methylene blue (to facilitate its identification in the operative field). Heparin was injected into the STA. Gel foam was used in both working areas (STA and MCA preparation). The recipient MCA cortical vessel was trapped with two temporary clips, and the arteriotomy was marked with methylene blue [Figure 8].

Left M4 MCA cortical vessel arteriotomy was done, and edges were stained with blue ink [Figure 9]. We used 10-0 sutures; first, we approximated donor and recipient vessels with 2 stitches. Then, an anterior wall [Figure 10] was closed with interrupted sutures. Then, the posterior wall was approximated with interrupted sutures [Figure 11].

Then we proceed to the removal of temporary clips one by one: First, the proximal temporary clip on the MCA was removed; second, we removed the distal clip-on MCA; finally, the temporary clip on the STA was released

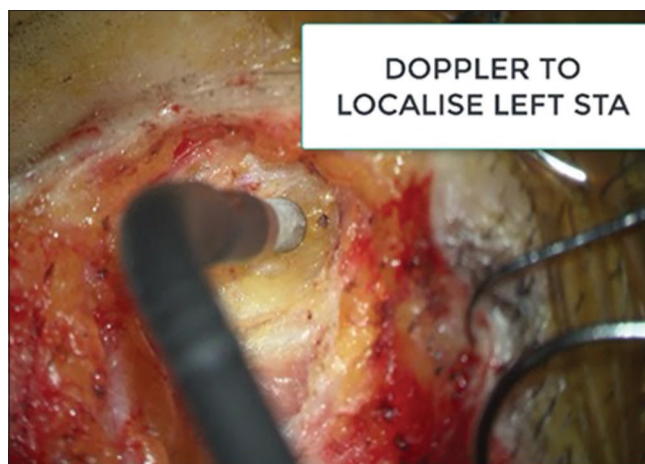

Figure 1: Intraoperative Doppler localization of Donor left superficial temporal artery from the beginning of subcutaneous dissection

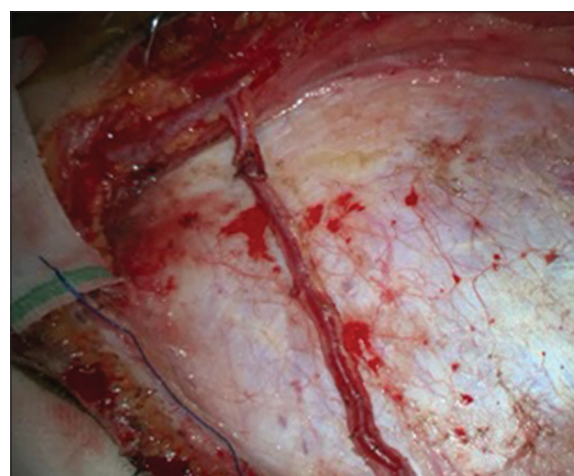


Figure 2: Left superficial temporal artery dissection from surrounding soft tissue

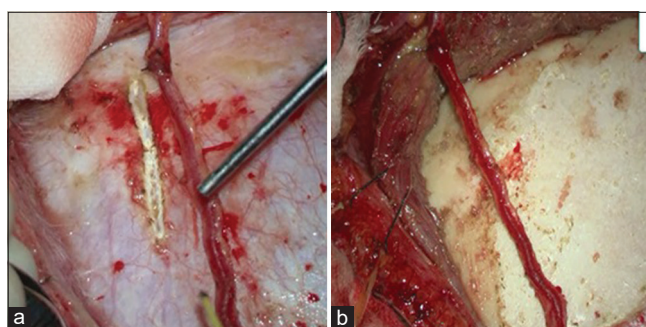


Figure 3: (a) Retraction of left temporalis muscle for craniotomy (b) mobilization of superficial temporal artery

allowing the verification of the patency of the anastomosis. We confirmed the luminal patency of anastomosis with Doppler ultrasound and DIVA. DIVA showed a good filling of blood through the anastomosis [Figure 12]. We verified the flow with a Doppler probe too [Figure 13].

The dural closure is also an important step; usually, we use the temporal muscle to ensure a good closure

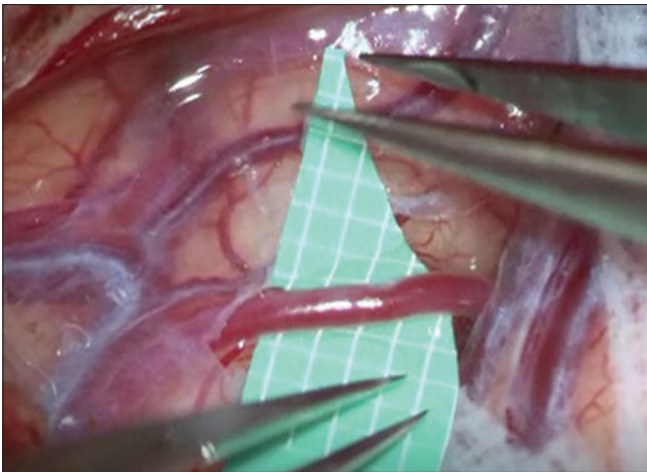


Figure 4: Mobilization of left M4 cortical branches

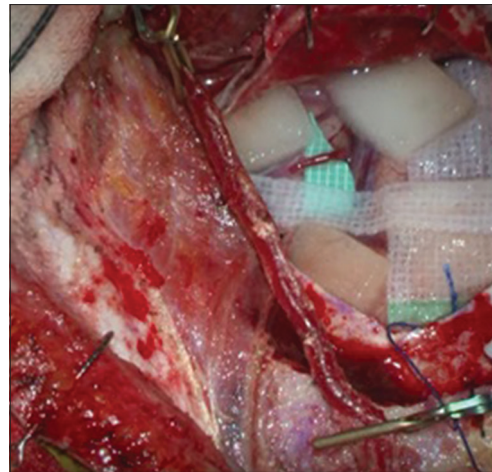


Figure 5: Clamping followed by mobilization of left superficial temporal artery

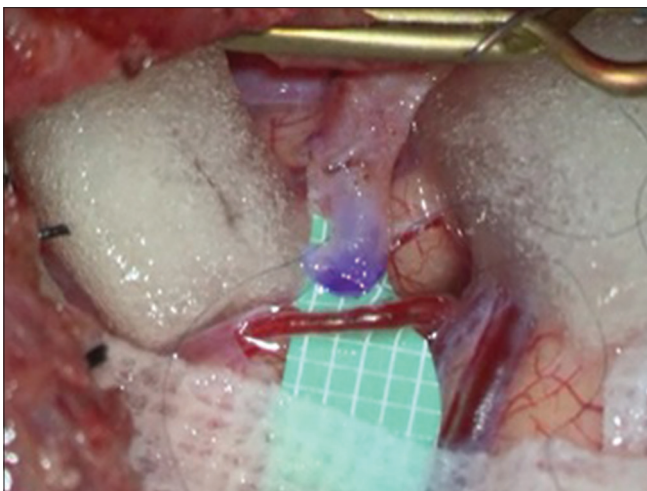


Figure 6: Preparation of left M4 middle cerebral artery for anastomosis

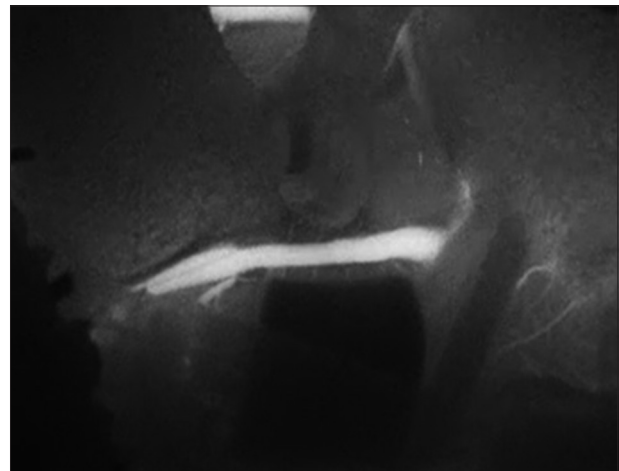


Figure 7: Intraoperative indocyanine green showing blood flow in recipient left M4 cortical branch before anastomosis

allowing a safe entrance of the STA without any compression.

Results

From 2018 to 2020, we performed 23 STA-MCA bypass surgeries. The mean age was 52 years with the youngest at 16 years and eldest at 84 years. There were 11 male and 12 female patients.

Out of 23 patients, 10 patients had associated hypertension and 4 had diabetes mellitus. In 16 patients, steno-occlusion was the indication for bypass. The goal of the bypass was flow augmentation in these 16 patients. IC Carotid artery stenosis was seen in 7 patients and MCA stenosis was seen in 9 patients. Three patients had Moyamoya disease. Low flow STA-MCA bypass was done in these 16 cases.

The most common symptom was frequent TIA presenting as hand numbness. Hemiparesis was noted in 6 patients. The visual loss (50%) was noted in one patient. Headache was noted in one patient. Handgrip weakness was seen in one patient. Facial weakness was seen in one patient.

Nine patients were asymptomatic with incidentally detected severe IC internal carotid artery (ICA) stenosis or MCA stenosis in magnetic resonance imaging (MRI) angiogram. Three patients had a giant aneurysm of ICA (cavernous segment), and one had recurrent anterior cerebral artery aneurysm (undergone coiling and clipping earlier).

SPECT analysis for baseline CBF was done in 6 patients. In 5 patients, baseline CBF was reduced (Type 1 cerebral hemodynamic impairment).

In three patients, bypass was done to achieve the flow replacement. Two patients had giant internal carotid aneurysms involving the cavernous segment. One patient had undergone multiple clipping and endovascular procedures for giant A1 aneurysm.

One case of the bypass was done on an emergency basis. There was coil migration while filling the left ICA (cavernous) aneurysm. Coil got migrated to distal MCA. An emergency STA-MCA bypass was performed. The patient recovered without any neurological deficits.

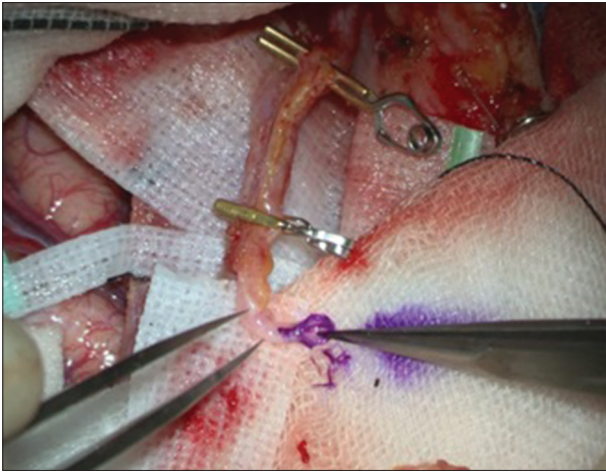


Figure 8: Fish mouth arteriotomy of superficial temporal artery and application of ethylene blue marker

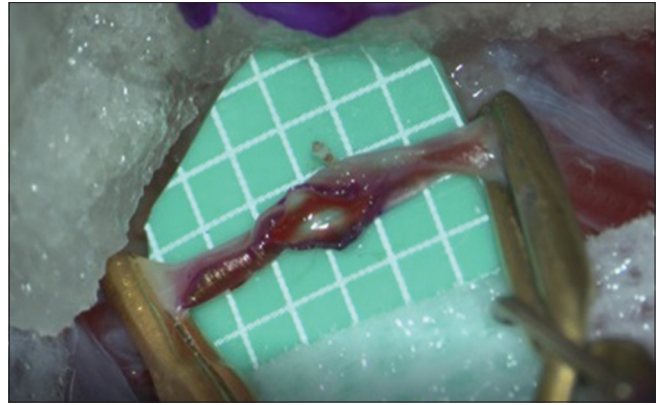


Figure 9: Arteriotomy of left M4 middle cerebral artery and application of ethylene blue marker

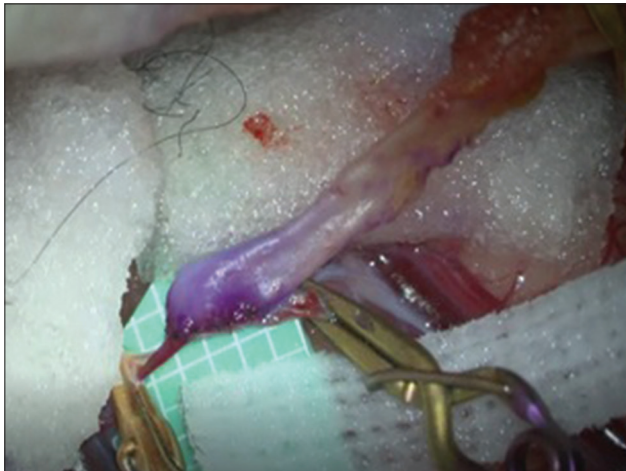


Figure 10: Closure of anterior wall anastomosis

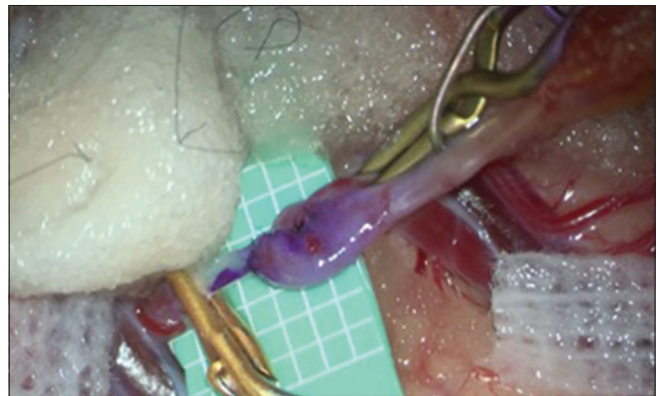

Figure 11: Closure of the dorsal wall of the anastomosis

A high flow bypass was done in all three cases explained above. Radial interposition graft waft was used in the first two cases, and saphenous venous graft was used in the latter case.

We used intraoperative Doppler before, during and after anastomosis in all patients to assess luminal patency.

Method of prediction of postoperative cerebral hyperperfusion with use of flow 800 intraoperative indocyanine green

Four regions of interest are marked in the frontal and temporal lobe. CBF at the above regions is measured with intraoperative ICG before anastomosis and after anastomosis. An increase in CBF by 2.5 times is a predictor of cerebral hyperperfusion.

There are some limitations with intraoperative ICG used for the assessment of hyperperfusion.

1. ICG injection speed, dose, and systemic hemodynamic conditions might influence ICG fluorescence configuration

2. Change in cardiac output and blood pressure would also affect maximal fluorescence intensity.

We used intraoperative video ICG with flow 800 to assess the luminal patency of anastomosis and compared with preanastomotic ICG angiogram. Intraoperative video ICG detected decreased flow through the anastomotic site in 2 patients. It helped us to revise anastomosis in the same setting, thus, decreasing perioperative morbidity and mortality.

We used to flow 800 to assess hypoperfusion and hyperperfusion after anastomosis. None of our patients had hypoperfusion or hyperperfusion after anastomosis.

Discussion

Indication

There are many trials conducted to assess the benefit of the bypass in cerebrovascular steno occlusive diseases. We will discuss the results of these trials and their limitations

International study on extracranial-intracranial bypass

Published in 1985, this prospective randomized trial investigated whether EC-IC arterial bypass, in addition to best medical therapy, was superior to best medical therapy alone in patients with ischemic cerebrovascular disease

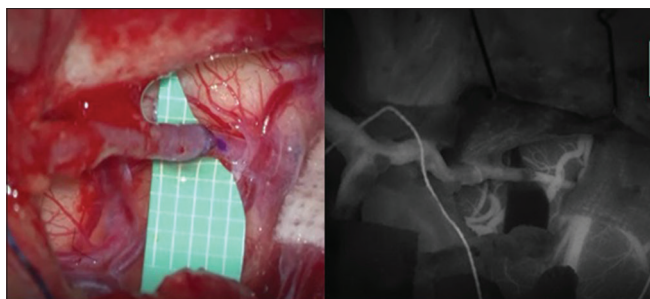


Figure 12: DIVA showing good flow across the anastomosis

including EC ICA occlusion.^[1] A total of 1377 patients were enrolled. The mean follow-up period of the study was 55.8 months. The overall risk of TIA/stroke in the medical group was 29% and bypass group was 31%. The incidence of perioperative stroke with surgery was 12.2% and overall mortality was 1.1%

There was no significant difference in outcome between the two groups. Hence, the number of bypasses performed reduced drastically after this trial.

The main criticism of this trial was cerebral hemodynamic impairment was not analyzed for case selection and randomization. Hence, carotid occlusion study (COSS) was performed to assess cerebral hemodynamic impairment in bypass surgeries.

Cerebral hemodynamic impairment

To further understand the evolution of bypass surgery, the discussion about cerebral hemodynamic impairment is necessary. It is divided into three stages.

Cerebral perfusion pressure is reduced in case of occlusion of ICA or MCA. Cerebral autoregulation maintains the CBF by compensatory vasodilatation. This is assessed by calculating baseline CBF and blood flow after acetazolamide challenge (using perfusion CT, MRI, positron emission tomography [PET] or SPECT). This is termed as stage 1 hemodynamic failure.

In Stage 2 failure, cerebral vasodilatation is insufficient to maintain CBF, and there is a compensatory increase in oxygen extraction from arteries (evidenced by increased oxygen deficit between artery and veins). This is called misery perfusion.

In Stage 3, there is complete failure to maintain adequate CBF even with vasodilatation and increased oxygen extraction. The risk of subsequent TIA and stroke are highest in Stage 2 and 3 failures. The subsequent trials were based on cerebral hemodynamic failure as a deciding factor in the selection of cases for bypass.

ST Louis carotid occlusion study

It's a prospective blinded study evaluating raised oxygen extraction factor (OEF) as a predictor of subsequent stroke. This study showed a relative risk of overall stroke in patients with raised OEF (OEF >6.0).

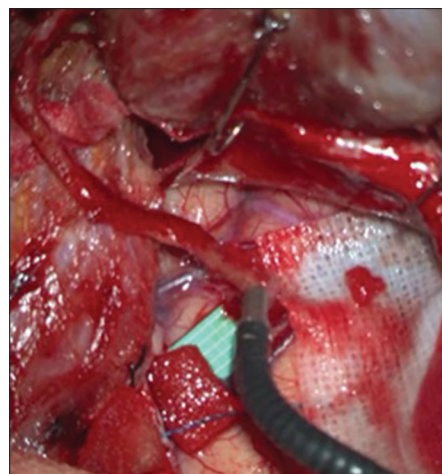


Figure 13: Doppler confirming luminal patency across superficial temporal artery middle cerebral artery bypass

The STLCOS conclusively demonstrated that symptomatic patients with EC ICA occlusion were at increased risk of subsequent ischemic stroke. Importantly, previous studies had established that EC-IC bypass surgery could improve hemispheric OEF ratios in Stage II patients back toward normal levels.^[2,3] This study was followed by COSS.

Carotid occlusion study

COSS was a prospective, parallel-group, 1:1 randomized, open-label, blinded-adjudication treatment trial designed to test the hypothesis that STA-MCA cortical branch anastomosis—added to best medical therapy—would reduce the 2-year risk of subsequent ipsilateral ischemic stroke by 40% in patients with carotid occlusion and recently symptomatic cerebral ischemia.

Total 195 patients with angiographic-proven ICA occlusion causing an ischemic stroke or TIA within 120 days and hemodynamic cerebral ischemia (indicated by an increased OEF ratio on PET) were randomized to best medical therapy or best medical therapy plus STA-MCA bypass. One hundred ninety-five patients were randomized. Ninety-seven patients were randomized to the surgical group and 98 to the medical group.

The study was halted prematurely due to futility. In the intention-to-treat analysis, the 2-year rates for ipsilateral stroke were 21% for the surgical group and 22.7% for the medical group ($P = 0.78$). Perioperative (within 30 days of surgery) ipsilateral stroke rates were 14.4% in the surgical group and 2.0% in the medical group, a significant difference of 12.4% (95% confidence interval 4.9%–19.9%). The study concluded that EC-IC bypass surgery in this patient population was not of clinical benefit.

This report was followed by a *post hoc* qualitative analysis of the mechanisms of perioperative ischemic stroke in the COSS surgical cohort. In this investigation, Reynolds *et al.*^[4] retrospectively identified patients from the COSS with an ipsilateral perioperative ischemic stroke and categorized

stroke mechanisms as bypass graft related (ischemic infarct in the territory of the recipient artery, likely related to the technical performance of the anastomosis) or nonbypass graft related (ischemic infarct attributable to embolism, hypoperfusion, or other cause). The vast majority of perioperative ischemic strokes (86% or 12 of 14) were found to be unrelated to the performance of bypass grafting, while the minority (21.4% or 3 of 14) were found to be related to the performance of bypass grafting.^[4] One patient was considered to have dual stroke mechanisms. The authors concluded that the majority of ischemic strokes were not attributable to technical problems with the anastomosis but were most likely due to the hemodynamic fragility of the patient population involved.

Thus, COSS has narrowed the indications for EC-IC bypass in the setting of ischemic cerebrovascular disease.^[5]

Hence, the relative indication for bypass in cerebral ischemia due to internal carotid or MCA occlusion are:^[5]

1. Recurrent TIA or stroke refractory to medical management
2. With impaired cerebral hemodynamic (Stage 1 or 2 failure) suggested by poor response to acetazolamide challenge in SPECT or increased OEF in PET CT scan.

Types of bypass surgeries

Depending on flow rate across anastomosis, bypass can be classified as high flow or low flow:^[6,7]

1. Standard flow-Flow rate of 20–70 ml/min
2. Intermediate flow-flow rate of 60–100 ml/min
3. High flow-flow rate of 100–200 ml/min (uses a radial artery or saphenous vein interposition graft between ECA and ICA).

Goals of extracranial-intracranial bypass surgeries

The goals of bypass either flow replacement or augmentation

1. Bypass for flow augmentation: It is performed for ischemic cerebrovascular disease due to occlusive disease of ICA above level of c2 cervical spine and MCA disease. The aim of surgery is to augment the blood flow to the brain from the external carotid artery
2. Bypass for flow replacement: Here, bypass is performed for giant IC aneurysm, which cannot be treated with clipping or by endovascular measures. In such instance, aneurysms are trapped proximally and distally and EC-IC bypasses are performed.^[8]

Thanapal *et al.*^[9] mentioned the risk factors for subsequent stroke or TIA. These risk factors for stroke include severe ICA or MCA stenosis (>70% stenosis), female gender, National Institutes of Health Stroke Scale score >1, concurrent diabetes, borderline body mass index values, hyperlipidemia, white ethnicity, and the presence of hemodynamic stenosis increases the risk for stroke.

Since the beginning of bypass surgeries by Dr. Yasargil, the perioperative management and intraoperative monitoring have evolved significantly. Here, the author will discuss the use of transcranial Doppler and intraoperative ICG (ICG angiogram) to assess the patency of anastomosis.

The introduction of intraoperative contact Doppler ultrasonography and flowmetry into clinical practice made it possible to quantify the local blood circulation in the territory of revascularization immediately after creating the bypass.

Morton *et al.*^[10] explained in his article about intraoperative use of Doppler ultrasonography in assessing luminal patency of anastomosis in the STA MCA bypass.

Balamurugan, *et al.*^[11] reported intraoperative use of ICG-video angiogram (VA) before and after anastomosis.

Even though microvascular Doppler is being used for a long time in cerebrovascular surgery, it has its own limitations. Although intraoperative DSA (digital subtraction Angiogram) is the gold standard technique, it needs additional professional experience and the table position needs to be changed. Moreover, it is time-consuming, expensive, and has radiation exposure also in the operating suite. Hence, ICG VA is replacing the above in many neurosurgical centers, because it is a simple, rapid, and reliable method, and we can get real-time images with good quality and high spatial resolution, and also, it is not an expensive one.

In EC-IC bypass, ICG VA gives exact information about the anastomotic site, so that early bypass graft failure can be avoided.

Background Intraoperative ICG video angiography (ICG-VA) shows cerebral blood vessels as white on a black background. However, other structures cannot be observed during ICG-VA. Sato *et al.*^[12] have developed a new, high-resolution intraoperative imaging system [DIVA] to simultaneously visualize both light and near-infrared fluorescence images from ICG-VA, allowing observation of blood vessels as well as other structures.

Feletti *et al.*^[13] analyzed the role of ICG VA and DIVA in cerebrovascular procedures. They opined that ICG VA provided better visual contrast between blood vessels (as white) and surrounding structures (as black). However, DIVA makes it easier to understand anatomical relations between IC structures. DIVA also gives a better vision of the depth of the field.

We revised anastomosis in two cases based on findings of DIVA (Dual Imaging Video Angiogram) and Doppler intraoperatively. Both patients recovered without perioperative morbidity or stroke. Hence, we recommend the use of intraoperative Doppler and DIVA are must in bypass procedure.

The reported side effects are very low with this DIVA technique when compared to other invasive methods. To avoid false positive findings, repeated injections of ICG within short intervals should not be given.

Even though there are certain limitations, ICG VA is widely being used in many centers, because it is simple, safe, and we can get faster results with high-resolution real-time images. The use of intraoperative Doppler and DIVA allowed graft patency of 96%.

Thines *et al.*^[14] discussed the role of perfect dural closure to prevent wound complications in the perioperative period.

It is imperative to monitor patients after bypass surgery not only for patency of anastomosis but also to predict and treat hypoperfusion or hyperperfusion. Among the various hemodynamic modalities, MRI, CT perfusion, and transcranial Doppler sonography are the most commonly used modalities. Post-stroke hypoperfusion is associated with infarct expansion, while hyperperfusion, which once was considered the hallmark of successful recanalization, is associated with hemorrhagic transformation. Either the hypo- or the hyperperfusion may result in poor clinical outcomes. Individual blood pressure target based on cerebral hemodynamic evaluation was crucial to improve the prognosis.^[15]

After revascularization surgery, a rapid and significant increase in ipsilateral CBF beyond the metabolic demand of the brain tissue may occur. Excessive blood flow directed into chronically ischemic brain through a bypass may induce a “luxury perfusion syndrome” resulting in neurological deterioration.^[16] Patients with poorer cerebrovascular reactivity are known to have a potentially higher risk for hyperperfusion syndrome.^[17]

Several methods have been proposed for the detection of cerebral hyper perfusion during operation or early after surgery.^[18] Gesang *et al.*^[19] indicated that the laser Doppler flowmeter is useful for postoperative real-time monitoring during the high-risk period. Intraoperative measurements such as thermography, infrared brain surface monitoring, and ICG fluorescence angiography predict post anastomosis cortical hemodynamic.^[18]

Conclusion

Hemodynamic recovery after bypass brings about a better outcome in ischemic stroke or TIA. The result of surgery improves with proper selection of patients with hemodynamic impairment (In Stage 2). With various modalities such as intraoperative Doppler, DIVA (dual imaging video angiography) with flow 800, improved surgical techniques, better selection of patients based on hemodynamic perfusion studies may aid in the reduction of complications and improve clinical outcome.

The outcomes of a good surgery may be complicated by hypoperfusion or hyperperfusion. The cost-effectiveness of various modalities also needs to be analyzed.

Declaration of patient consent

The authors certify that they have obtained all appropriate patient consent forms. In the form the patient(s) has/have given his/her/their consent for his/her/their images and other clinical information to be reported in the journal. The patients understand that their names and initials will not be published and due efforts will be made to conceal their identity, but anonymity cannot be guaranteed.

Acknowledgment

The study is performed with the guidance of the Department of Neurosurgery, Fujita University Bantane Hospital, Nagoya, Japan.

Financial support and sponsorship

Nil.

Conflicts of interest

There are no conflicts of interest.

References

1. EC/IC Bypass Study Group: Failure of extracranial-intracranial arterial bypass to reduce the risk of ischemic stroke. Results of an international randomized trial. *N Engl J Med* 1985;313:1191-200.
2. Samson Y, Baron JC, Boussier MG, Rey A, Derlon JM, David P, *et al.* Effects of extra-intracranial arterial bypass on cerebral blood flow and oxygen metabolism in humans. *Stroke* 1985;16:609-16.
3. Powers WJ, Martin WR, Herscovitch P, Raichle ME, Grubb RL Jr. Extracranial-intracranial bypass surgery: Hemodynamic and metabolic effects. *Neurology* 1984;34:1168-74.
4. Reynolds MR, Grubb RL Jr., Clarke WR, Powers WJ, Zipfel GJ, Adams HP Jr., *et al.* Investigating the mechanisms of perioperative ischemic stroke in the Carotid Occlusion Surgery Study. *J Neurosurg* 2013;119:988-95.
5. Reynolds MR, Derdeyn CP, Grubb RL Jr., Powers WJ, Zipfel GJ. Extracranial-intracranial bypass for ischemic cerebrovascular disease: What have we learned from the Carotid Occlusion Surgery Study? *Neurosurg Focus* 2014;36:E9.
6. Wessels L, Hecht N, Vajkoczy P. Bypass in neurosurgery-indications and techniques. *Neurosurg Rev* 2019;42:389-93.
7. Meybodi AT, Huang W, Benet A, Kola O, Lawton MT. Bypass surgery for complex middle cerebral artery aneurysms: An algorithmic approach to revascularization. *J Neurosurg* 2016;127:1.
8. Wessels L, Hecht N, Vajkoczy P. Bypass in neurosurgery-indications and techniques. *Neurosurg Rev* 2018;1:1-5.
9. Thanapal S, Duvuru S, Sae-Ngow T, Kato Y, Takizawa K. Direct cerebral revascularization: Extracranial-intracranial bypass. *Asian J Neurosurg* 2018;13:9-17.
10. Morton RP, Moore AE, Barber J, Tariq F, Hare K, Ghodke B, *et al.* Monitoring flow in extracranial-intracranial bypass grafts using duplex ultrasonography: A single-center experience in 80 grafts over 8 years. *Neurosurgery* 2014;74:62-70.
11. Balamurugan S, Agrawal A, Kato Y, Sano H. Intra operative indocyanine green video-angiography in cerebrovascular surgery: An overview with review of literature. *Asian J Neurosurg* 2011;6:88-93.

12. Sato T, Suzuki K, Sakuma J, Takatsu N, Kojima Y, Sugano T, *et al.* Development of a new high-resolution intraoperative imaging system (dual-image video angiography, DIVA) to simultaneously visualize light and near-infrared fluorescence images of indocyanine green angiography. *Acta Neurochir (Wien)* 2015;157:1295-301.
13. Feletti A, Wang X, Tanaka R, Yamada Y, Suyama D, Kawase T, *et al.* Dual-image video angiography during intracranial microvascular surgery. *World Neurosurg* 2017;99:572-9.
14. Thines L, Durand A, Penchet G, Proust F, Lenci H, Debailleul A, *et al.* Microsurgical neurovascular anastomosis: The example of superficial temporal artery to middle cerebral artery bypass. Technical principles. *Neurochirurgie* 2014;60:158-64.
15. Zhang Z, Pu Y, Mi D, Liu L. Cerebral hemodynamic evaluation after cerebral recanalization therapy for acute ischemic stroke. *Front Neurol* 2019;10:719.
16. Higashi S, Matsuda H, Fujii H, Ito H, Yamashita J. Luxury perfusion syndrome confirmed by sequential studies of regional cerebral blood flow and volume after extracranial to intracranial bypass surgery: Case report. *Neurosurgery* 1989;25:85-9.
17. Fujimura M, Mugikura S, Kaneta T, Shimizu H, Tominaga T. Incidence and risk factors for symptomatic cerebral hyperperfusion after superficial temporal artery-middle cerebral artery anastomosis in patients with moyamoya disease. *Surg Neurol* 2009;71:442-7.
18. Kawamata T, Kawashima A, Yamaguchi K, Hori T, Okada Y. Usefulness of intraoperative laser Doppler flowmetry and thermography to predict a risk of postoperative hyperperfusion after superficial temporal artery-middle cerebral artery bypass for moyamoya disease. *Neurosurg Rev* 2011;34:355-62.
19. Gesang DZ, Zhang D, Zhao JZ, Wang S, Zhao YL, Wang R, *et al.* Laser Doppler flowmeter study on regional cerebral blood flow in early stage after standard superficial temporal artery-middle cerebral artery bypass surgery for moyamoya disease. *Chin Med J (Engl)* 2009;122:2412-8.