

## Central Neurocytoma Presenting with Bleed and Obstructive Hydrocephalus: A Rare Presentation

### Abstract

Central neurocytomas (CNs) occur typically in the lateral ventricle, adjacent to the septum pellucidum and foramen of Monro. The clinical presentation varies and many are incidentally detected. Incidence of spontaneous hemorrhage at presentation is rare. We hereby report a case of the intraventricular lesion with bleed which was operated on an emergency basis as it caused obstructive hydrocephalus and the patient was in altered sensorium. The exact cause of hemorrhage in CNs is not known, and the previously discussed explanations are discussed.

**Keywords:** *Central neurocytoma, hydrocephalus, neurosurgery*

### Introduction

Central neurocytoma (CN) comprises 0.1%–0.5% of all brain tumors. It was first described by Hassoun *et al.* in 1982,<sup>[1]</sup> and it currently corresponds histologically to the World Health Organization Grade II tumors.<sup>[2]</sup> CN is classically located in the lateral ventricle and/or the third ventricle with the septum pellucidum attachment to be one the features of the tumor. However, the most common site is the anterior portion of one of the lateral ventricles followed by combined extension into the lateral and third ventricles. However, recently, they were also found in an intra-axial location (cerebral, cerebellar, brainstem, or spinal parenchyma) and termed as “extraventricular neurocytoma” (EVN). “Cerebral neurocytoma” is the term usually used to designate both CN and EVN.<sup>[3]</sup> About 70% of affected individuals are between the age group of 20 and 40 years, both sexes are almost equally affected, with a male-to-female ratio of 1.02:1.<sup>[4]</sup> We hereby report a case of the intraventricular lesion with bleed, which was operated on emergency basis.

### Case Report

A 54-year-old male presented with the complaints of headache for 1 month followed by progressively decreasing

This is an open access journal, and articles are distributed under the terms of the Creative Commons Attribution-NonCommercial-ShareAlike 4.0 License, which allows others to remix, tweak, and build upon the work non-commercially, as long as appropriate credit is given and the new creations are licensed under the identical terms.

For reprints contact: reprints@medknow.com

speech output and was in altered sensorium at presentation. The tone was increased in the right upper and lower limb with weakness of the right upper and lower limb. He was evaluated with computed tomography (CT) of the brain plain and contrast [Figure 1a and b] which showed left lateral intraventricular lesion with septal attachment with enlargement of the left lateral ventricle. The lesion was hyperdense with Hounsfield units suggestive of blood, and there was no contrast enhancement.

The patient underwent left frontal craniotomy transcortical transventricular approach and gross total resection of the septal lesion followed by an external ventricular drain (EVD) placement. Tumor was firm, reddish with blood clots and had an attachment to the septum. The surrounding tissue was gliotic and had a yellowish discoloration suggestive of remote bleed. Histopathological examination showed features of a neurocytoma with increased tumoral vascularity, large areas of hemorrhage, and early organization of hematoma. The periphery showed aggregates of numerous vessels resembling a vascular malformation. Vessels at the periphery were calcified.

Postoperative CT brain [Figure 1c] showed gross total excision of the lesion with resolving intraventricular bleed and EVD tip in situ. EVD was removed on postoperative day 3. The patient improved postsurgery and was discharged on postoperative

**How to cite this article:** Chandshah MI, Sadashiva N, Konar S, Devi BI. Central neurocytoma presenting with bleed and obstructive hydrocephalus: A rare presentation. *Asian J Neurosurg* 2019;14:919-21.

**Mustafa Iqbalahmed Chandshah, Nishanth Sadashiva, Subhas Konar<sup>1</sup>, Bhagavatula Indira Devi**

*Departments of Neurosurgery and <sup>1</sup>Neuropathology, National Institute of Mental Health and Neurosciences, Bengaluru, Karnataka, India*

**Address for correspondence:**  
Prof. Bhagavatula Indira Devi,  
Department of Neurosurgery,  
2<sup>nd</sup> Floor, Neurosciences  
Faculty Building, National  
Institute of Mental Health  
and Neurosciences,  
Bengaluru - 560 029,  
Karnataka, India.  
E-mail: bidevidr@gmail.com

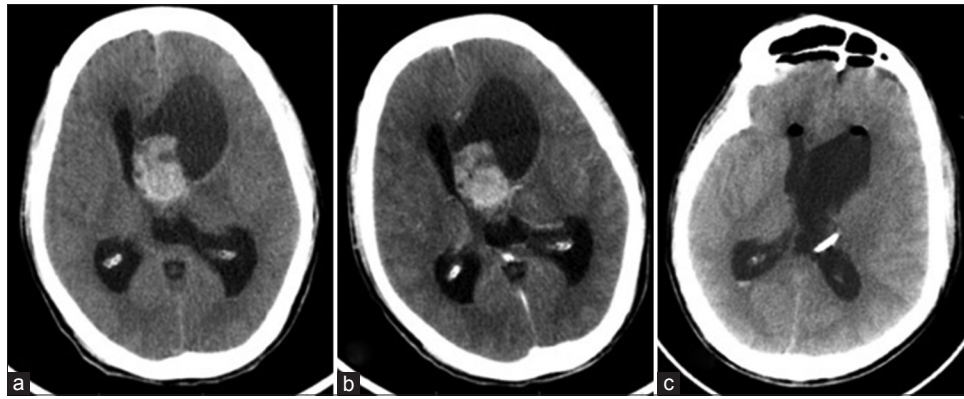
Access this article online

Website: [www.asianjns.org](http://www.asianjns.org)

DOI: 10.4103/ajns.AJNS\_84\_19

Quick Response Code:





**Figure 1:** (a) Computed tomography of the brain plain axial section showing heterogeneously hyperdense lesion in the left lateral ventricle attached to the septum with predominant areas of hyper-density suggestive of bleed with asymmetric ventriculomegaly (left > right). (b) Contrast-enhanced imaging showing no contrast enhancement. (c) Postoperative computed tomography of the brain plain showed complete resection with reduced ventricular size and external ventricular drain tip *in situ*

day 4. At 2 months, the patient had improved to normal neurological status and on latest follow-up of 3 years, the patient maintained his normal neurological status.

## Discussion

CN is rare central nervous system tumor and incidence of spontaneous hemorrhage at presentation is exquisitely rare.<sup>[5]</sup> They occur typically in the lateral ventricle, adjacent to the septum pellucidum and the foramen of Monro, and extension to the third ventricle may be seen. On CT of the brain, they are mixed density lesion with areas of cystic changes, calcifications, and rarely hemorrhage within it with mild-to-moderate contrast enhancement. On magnetic resonance imaging, it is isointense to gray matter in both T1- and T2-weighted imaging with areas of heterointensity due to calcification, cystic spaces, hemorrhage, or vascular flow voids with mild-to-moderate contrast enhancement.<sup>[6]</sup> The clinical presentation varies and one may present with headache and other features or raised intracranial pressure, memory disturbance, and weakness of extremities, of which headache is the most common symptom, rarely it may be incidentally detected.<sup>[7]</sup>

The mainstay of treatment is total resection whenever possible, which can be either performed by either transcallosal or transcortical approach; however, the approach has to be individualized. The benefits and risks of each approach such as postoperative seizures and neuropsychological outcomes should be weighed during decision-making. The use of adjuvant radiotherapy for gross total resection is not indicated; however, it can be used for residual/recurrent disease though it remains controversial.<sup>[8]</sup>

According to one of the recently published retrospective study, the incidence of hemorrhage was 5 of 63 cases (7.9%).<sup>[7]</sup> The exact cause of hemorrhage in CN is not known; however, many postulations are made as far as gliomas are concerned which includes high vascularity and hemodynamic stress caused by arteriovenous shunting, venous occlusion by tumor encasement, and

fragile tumor vessels.<sup>[9]</sup> The proposed causes for bleed in CN being associated with hypertensive heart disease, thrombocytopenia,<sup>[10]</sup> thin-walled tumor vessels,<sup>[11]</sup> and coexistent feeding artery aneurysm.<sup>[12]</sup> In the present case, thin-walled fragile tumor vessels are the possible cause of hemorrhage as other previously mentioned etiologic factors were absent.

## Conclusion

In the present case, there were both areas of remote and fresh bleed, which signifies inherent propensity to rebleed if once tumor has bled. CN has usually indolent growth, but in our case due to repeated hemorrhage within the tumor might have caused rapid increase in size leading to raised intracranial pressure due to tumor itself and also due to obstructive hydrocephalus. Clinicians should be aware of this unique clinical presentation, and emergency surgical intervention should be undertaken.

## Declaration of patient consent

The authors certify that they have obtained all appropriate patient consent forms. In the form the patient(s) has/have given his/her/their consent for his/her/their images and other clinical information to be reported in the journal. The patients understand that their names and initials will not be published and due efforts will be made to conceal their identity, but anonymity cannot be guaranteed.

## Financial support and sponsorship

Nil.

## Conflicts of interest

There are no conflicts of interest.

## References

- Hassoun J, Gambarelli D, Grisoli F, Pellet W, Salamon G, Pellissier JF, *et al.* Central neurocytoma. An electron-microscopic study of two cases. *Acta Neuropathol* 1982;56:151-6.
- Louis DN, Ohgaki H, Wiestler OD, Cavenee WK,

- Burger PC, Jouvét A, *et al.* The 2007 WHO classification of tumours of the central nervous system. *Acta Neuropathol* 2007;114:97-109.
3. Agrawal P, Gupta K, Sodhi HB. Extraventricular neurocytoma: An uncommon tumor in a young boy. A review of literature. *Neurol India* 2017;65:202-5.
  4. Lee SJ, Bui TT, Chen CH, Lagman C, Chung LK, Sidhu S, *et al.* Central neurocytoma: A review of clinical management and histopathologic features. *Brain Tumor Res Treat* 2016;4:49-57.
  5. Gunawat PV, Patil SS, Karmarkar VS, Deopujari CE. Intraventricular hemorrhage – Unusual presentation of central neurocytoma. *Neurol India* 2014;62:691-3.
  6. Chen CL, Shen CC, Wang J, Lu CH, Lee HT. Central neurocytoma: A clinical, radiological and pathological study of nine cases. *Clin Neurol Neurosurg* 2008;110:129-36.
  7. Wang M, Zhou P, Zhang S, Liu X, Lv L, Wang Z, *et al.* Clinical features, treatment, and long-term outcomes of central neurocytoma: A 20-year experience at a single center. *World Neurosurg* 2018;109:e59-66.
  8. Barani IJ, Raleigh DR, Larson D. The management of central neurocytoma: Radiotherapy. *Neurosurg Clin N Am* 2015;26:45-56.
  9. Liwnicz BH, Wu SZ, Tew JM Jr. The relationship between the capillary structure and hemorrhage in gliomas. *J Neurosurg* 1987;66:536-41.
  10. Smets K, Salgado R, Simons PJ, De Clercq R, De Smedt K, Cras P, *et al.* Central neurocytoma presenting with intraventricular hemorrhage: Case report and review of literature. *Acta Neurol Belg* 2005;105:218-25.
  11. Nishibayashi H, Uematsu Y, Terada T, Itakura T. Neurocytoma manifesting as intraventricular hemorrhage – Case report. *Neurol Med Chir (Tokyo)* 2006;46:41-5.
  12. Vates GE, Arthur KA, Ojemann SG, Williams F, Lawton MT. A neurocytoma and an associated lenticulostriate artery aneurysm presenting with intraventricular hemorrhage: Case report. *Neurosurgery* 2001;49:721-5.