

Cisplatin-related Cerebral Infarction in Carcinoma of the External Auditory Canal

Abstract

Background: Despite the known association between cisplatin and vascular toxicity, the mechanism of cisplatin-associated cerebral infarction, a relatively rare complication, remains unclear. We describe an investigation of potential biomarkers that could facilitate the early detection of this complication in a relevant case. **Case Description:** A 59-year-old male diagnosed with stage III carcinoma of the external auditory canal underwent cisplatin chemotherapy. Seven days after the last dose, he presented with a disturbance of consciousness due to basilar artery occlusion, which was associated with chemotherapy administration. The patient recovered consciousness after thrombectomy. Interestingly, an increase in serum von Willebrand factor (vWf) activity was observed. The vWf activity level gradually normalized 5 months after cisplatin administration. **Conclusions:** Endothelial injuries could be responsible for cisplatin-associated cerebral infarction. Moreover, a cisplatin-induced cerebral infarction increase in serum vWf activity, which indicates endothelial injury, suggests that this molecule might be a useful biomarker for predicting cisplatin-associated cerebral infarction.

Keywords: Cerebral infarction, cisplatin, vascular toxicity, von Willebrand factor

Introduction

Chemotherapy-associated cerebral infarction, such as that induced by cisplatin, is rare and poorly understood.^[1-3] Despite its reputation as an effective chemotherapeutic drug, cisplatin has been shown to induce vascular toxicity and be associated with cerebral infarction;^[4,5] however, its mechanism of action remains unknown. Here, we describe a case presenting with cisplatin-associated cerebral infarction.

Case Report

A 59-year-old male was diagnosed with stage III carcinoma of the external auditory canal, with no apparent brain metastases. The patient had no previous medical history of atrial fibrillation, ischemic heart disease, or stroke. After cancer was removed, the patient was treated with cisplatin to prevent cancer recurrence. Seven days after cisplatin administration, he suddenly presented with a disturbance of consciousness. Head magnetic resonance imaging showed basilar artery occlusion, which was associated with chemotherapy administration [Figure 1a]. Once diagnosed, an endovascular

stent retrieval thrombectomy was performed [Figure 1b and c]. The patient recovered consciousness after thrombectomy, although there were some ischemic lesions visible on diffusion-weighted images [Figure 1d]. The patient then began taking a direct oral anticoagulant to prevent thrombosis. Serum von Willebrand factor (vWf) activity increased during the occurrence of cerebral infarction. This vWf activity gradually decreased after the cerebral infarction and normalized 5 months after cisplatin administration [Figure 2]. The patient did not experience a recurrence of cerebral infarction after cisplatin administration.

Discussion

A previous study reported an incidence rate of 0.137% for chemotherapy-associated ischemic stroke and observed that most of the patients exhibited a latency period of ≤ 10 days after the latest chemotherapy session.^[6] Regarding cisplatin usage specifically, a previous study of 108 patients with non-small cell lung carcinoma who received cisplatin and gemcitabine treatment concluded that chemotherapy is

**Makoto Kadowaki,
Yoshinobu Kamio,
Hisaya Hiramatsu,
Hiroki Namba**

*Department of Neurosurgery,
Hamamatsu University School
of Medicine, Hamamatsu, Japan*

This is an open access journal, and articles are distributed under the terms of the Creative Commons Attribution-NonCommercial-ShareAlike 4.0 License, which allows others to remix, tweak, and build upon the work non-commercially, as long as appropriate credit is given and the new creations are licensed under the identical terms.

For reprints contact: WKHLRPMedknow_reprints@wolterskluwer.com

How to cite this article: Kadowaki M, Kamio Y, Hiramatsu H, Namba H. Cisplatin-related cerebral infarction in carcinoma of the external auditory canal. *Asian J Neurosurg* 2020;15:683-5.

Submitted: 08-Mar-2020 **Revised:** 17-Mar-2020
Accepted: 21-May-2020 **Published:** 28-Aug-2020

Address for correspondence:
Dr. Yoshinobu Kamio,
1-20-1 Handayama, Higashi-Ku,
Hamamatsu 4313192, Japan.
E-mail: ykamio@hama-med.
ac.jp

Access this article online

Website: www.asianjns.org

DOI: 10.4103/ajns.AJNS_83_20

Quick Response Code:



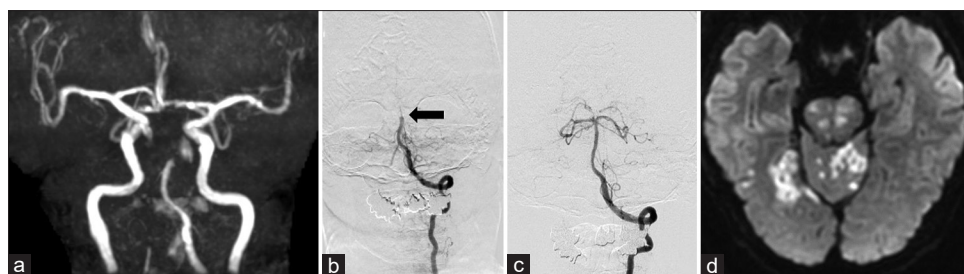


Figure 1: (a) Magnetic resonance angiography shows basilar artery occlusion (b) Preoperative cerebral angiography also shows basilar artery occlusion (black arrow) (c) Postoperative cerebral angiography shows the recanalization of the basilar artery (d) Diffusion-weighted image shows ischemic lesions on the cerebellum and brainstem

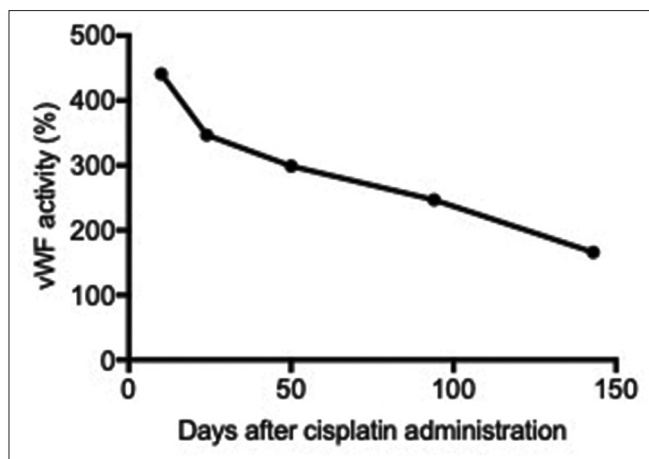


Figure 2: Time-course measurement of serum von Willebrand factor activity

a powerful risk factor for arterial thrombosis, including cerebral infarction.^[7] The findings of that and other previous studies are consistent with our findings demonstrating that one patient experienced ischemic stroke combined with the reported occurrence of cerebral infarction.^[1,4-6]

The mechanism of chemotherapy-associated cerebral infarction is multifactorial. Cancer-induced hypercoagulation can cause a thrombus. Possible mechanisms, including platelet activation, alteration of the clotting cascade (including hyperfibrinolysis), and disturbances of prostacyclin–thromboxane homeostasis, could explain the 4- to 6-fold increased risk of thrombosis in cancer patients relative to the general population.^[8] All patients in the current study exhibited increased D-dimer levels, which can indicate the presence of a thrombus.

Cisplatin-associated vascular toxicity can also increase the risk of stroke. Moore *et al.* showed that when diagnosing cisplatin-induced cerebral infarction, risk factors for thromboembolism such as atherosclerosis and preexisting cardiovascular diseases can be excluded from consideration.^[1] Lajer and Daugaard reported that cisplatin induces hypomagnesemia in 76%–87% of treated patients.^[9] Low magnesium levels increase the intracellular calcium concentration, which initiates smooth muscle contraction and causes vasospasm and tissue ischemia. Other possible mechanisms could include cisplatin-associated damage

of the endothelium and basement membrane, which could cause a thrombotic effect that leads to ischemic cerebrovascular disease. Nuver *et al.* showed that human endothelial cells exposed to cisplatin *in vitro* upregulated the production of inflammatory proteins, which are assumed to initiate vascular inflammation and endothelial dysfunction.^[10] Moreover, since vWf is produced by endothelial cells, it is considered to be a suitable biomarker of endothelial cell activation and vascular damage.^[11] Physiologically, vWf mediates the mechanisms of endothelial injury repair, which is achieved mainly through the platelet adhesion and aggregation. Furthermore, Uchiyama *et al.* reported that platelet aggregation is increased in patients with atherothrombotic stroke and transient ischemic attacks, and this event is correlated with an increase in large vWf multimers, defined as those with molecular weights of $\geq 13\text{--}14 \times 10^6$ kDa.^[12] One noteworthy aspect of the afore-mentioned case study was the increase in serum vWf activity at the onset of cerebral infarction and then normalized within several months, suggesting endothelial injury. The previous reports showed that the vWf level normalized approximately 4 months after endothelial injury.^[11,13] Taken together, these data suggest that serum vWf can be a useful biomarker for predicting cisplatin-associated cerebral infarction. However, confounding factors such as malignancy and concomitant medication cannot be excluded from the study.

Moreover, cisplatin-associated cerebral infarction is likely suspected in cases, in which this cerebrovascular event occurs shortly after chemotherapy administration. Alternative chemotherapy programs that exclude cisplatin administration may reduce the occurrence of cerebral infarction. One limitation of this study was our inability to measure the serum activity of vWf in all cases. In addition, a comparison of the baseline vWF activity before chemotherapy administration with the posttreatment level would have been ideal. Second, vWf is not specific for cisplatin-induced cerebral infarction because vWf activity may increase in noncancer patients who experienced a stroke. Some animal models have shown that serum vWf activity increased in an ischemic model.^[14] Our observations regarding serum vWf activity thus require further analysis. In conclusion, patients who underwent

cisplatin-based chemotherapy exhibit an increased risk for the rare complication of cerebral infarction. Moreover, we observed an increase in vWf activity during the onset of cerebral infarction, which was later normalized within several months. Taken together, serum vWf activity could be a potentially useful biomarker for predicting cisplatin-associated cerebrovascular diseases.

Declaration of patient consent

The authors certify that they have obtained all appropriate patient consent forms. In the form the patient(s) has/have given his/her/their consent for his/her/their images and other clinical information to be reported in the journal. The patients understand that their names and initials will not be published and due efforts will be made to conceal their identity, but anonymity cannot be guaranteed.

Financial support and sponsorship

Nil.

Conflicts of interest

There are no conflicts of interest.

References

- Moore RA, Adel N, Riedel E, Bhutani M, Feldman DR, Tabbara NE, *et al.* High incidence of thromboembolic events in patients treated with cisplatin-based chemotherapy: A large retrospective analysis. *J Clin Oncol* 2011;29:3466-73.
- Ohashi S, Yazumi S, Nishio A, Fukui T, Asada M, Chiba T. Acute cerebral infarction during combination chemotherapy with s-1 and cisplatin for a young patient with a mucin-producing adenocarcinoma of the stomach. *Intern Med* 2006;45:1049-53.
- Sato C, Okuda K, Tamiya H, Yamamoto K, Hoshina K, Narumoto O, *et al.* Acute arterial thrombosis during postoperative adjuvant cisplatin-based chemotherapy for completely resected lung adenocarcinoma. *Intern Med* 2018;57:557-61.
- Dieckmann KP, Struss WJ, Budde U. Evidence for acute vascular toxicity of cisplatin-based chemotherapy in patients with germ cell tumour. *Anticancer Res* 2011;31:4501-5.
- Lange J, Audebert HJ, Endres M, Rocco A. Cisplatin-related cerebral infarction in testicular germ cell cancer: Short report of three cases and *P* in testicular germ cell cancer: Short report of three cases and pathomechanism. *Clin Neurol Neurosurg* 2017;152:76-7.
- Li SH, Chen WH, Tang Y, Rau KM, Chen YY, Huang TL, *et al.* Incidence of ischemic stroke post-chemotherapy: A retrospective review of 10,963 patients. *Clin Neurol Neurosurg* 2006;108:150-6.
- Numico G, Garrone O, Dongiovanni V, Silvestris N, Colantonio I, Di Costanzo G, *et al.* Prospective evaluation of major vascular events in patients with nonsmall cell lung carcinoma treated with cisplatin and gemcitabine. *Cancer* 2005;103:994-9.
- Blom JW, Doggen CJ, Osanto S, Rosendaal FR. Malignancies, prothrombotic mutations, and the risk of venous thrombosis. *JAMA* 2005;293:715-22.
- Lajer H, Daugaard G. Cisplatin and hypomagnesemia. *Cancer Treat Rev* 1999;25:47-58.
- Nuver J, De Haas EC, Van Zweeden M, Gietema JA, Meijer C. Vascular damage in testicular cancer patients: A study on endothelial activation by bleomycin and cisplatin *in vitro*. *Oncol Rep* 2010;23:247-53.
- Horvath B, Hegedus D, Szapary L, Marton Z, Alexy T, Koltai K, *et al.* Measurement of von Willebrand factor as the marker of endothelial dysfunction in vascular diseases. *Exp Clin Cardiol* 2004;9:31-4.
- Uchiyama S, Yamazaki M, Maruyama S, Handa M, Ikeda Y, Fukuyama M, *et al.* Shear-induced platelet aggregation in cerebral ischemia. *Stroke* 1994;25:1547-51.
- Menih M, Križmarić M, Hojs Fabjan T. Clinical role of von Willebrand factor in acute ischemic stroke. *Wien Klin Wochenschr* 2017;129:491-6.
- Kleinschnitz C, De Meyer SF, Schwarz T, Austinat M, Vanhoorelbeke K, Nieswandt B, *et al.* Deficiency of von Willebrand factor protects mice from ischemic stroke. *Blood* 2009;113:3600-3.