

## Case Report

# Feasibility of a Fourth Ventriculopleural Shunt for Diversion of an Isolated Fourth Ventricle: A Technical Note

## Abstract

Isolated fourth ventricle syndrome is an uncommon entity due to obstruction of both inlet and outflow foramina. The resulting mass effect from the progressively expanding fourth ventricle may cause symptoms from both cerebellar and brainstem compression. Although a variety of treatment modalities have been advocated for this condition, an in-depth description of placement of a fourth ventriculopleural (VPL) shunt from a single-stage prone approach has not yet been published in the literature. We describe here a case of successful placement of a fourth VPL shunt in a 22-year-old female with a history of a prior posterior fossa pilocytic astrocytoma resection who presented with symptomatic isolated fourth ventricular hydrocephalus.

**Keywords:** Fourth ventricle, hydrocephalus, ventriculoperitoneal shunt, ventriculopleural shunt

## Introduction

Isolated fourth ventricle syndrome is an uncommon entity caused by a variety of pathologic and congenital lesions that obstruct the fourth ventricular flow of cerebrospinal fluid (CSF) both at its inlet and outlet foramina. The resultant enlargement of the fourth ventricle causes direct pressure to both the cerebellum posteriorly and brainstem anteriorly.<sup>[1]</sup> Various surgical treatments have been advocated and described in the literature and have included ventriculoperitoneal (VP) shunts, open surgical and endoscopic fenestrations, and transaqueductal stenting.<sup>[2-6]</sup>

The use of ventriculopleural (VPL) shunts has been well described to be a safe and effective treatment option for the management of hydrocephalus.<sup>[7]</sup> However, to the best of our knowledge, an in-depth technical description of a fourth VPL shunt for CSF diversion from a single-stage prone position has not yet been described in the literature. We describe here a case of successful placement of a fourth VPL shunt in a 22-year-old female with a history of a prior posterior fossa pilocytic astrocytoma resection who presented with symptomatic isolated fourth ventricular hydrocephalus.

This is an open access journal, and articles are distributed under the terms of the Creative Commons Attribution-NonCommercial-ShareAlike 4.0 License, which allows others to remix, tweak, and build upon the work non-commercially, as long as appropriate credit is given and the new creations are licensed under the identical terms.

For reprints contact: reprints@medknow.com

## Case Report

### Presentation

A 22-year-old female with a distant history of a resected posterior fossa pilocytic astrocytoma and a right occipital VP shunt presented to our hospital with new onset of headaches, nausea, vomiting, and 6<sup>th</sup> nerve palsy. On both computed tomography (CT) and magnetic resonance (MR) imaging, she had isolated dilatation of her fourth ventricle likely due to adhesions from her prior surgery [Figure 1]. Her history included a prior attempt several years ago of a suboccipital craniotomy for lysis of adhesions when she presented with similar symptoms at another hospital, which did resolve her symptoms for sometime. After a multidisciplinary discussion, it was believed that a repeat lysis of adhesions this time would not be sufficient for definitive management due to the present recurrence both of her symptoms and the robust adhesions around her brainstem. Therefore, in addition to adhesiolysis, a fourth VPL shunt was placed from a single-stage prone approach given her symptoms and the magnitude of brainstem compression.

### Surgical technique

She was positioned prone with her head fixated a Mayfield three-pronged head clamp in a chin-tucked flexed position. Her neck and upper back were prepped

**How to cite this article:** Lewis CS, Chang KE, Bakhsheshian J, Strickland BA, Pham MH. Feasibility of a fourth ventriculopleural shunt for diversion of an isolated fourth ventricle: A technical note. Asian J Neurosurg 2018;13:897-900.

**Courtney Suzanne Lewis,  
Ki-Eun Chang,  
Joshua Bakhsheshian, Ben Allen Strickland,  
Martin Huy Pham**

Department of Neurosurgery,  
Keck School of Medicine,  
University of Southern  
California, Los Angeles,  
California, USA

### Address for correspondence:

Dr. Martin H. Pham,  
LAC + USC Medical Center,  
1200 North State Street, Suite  
3300, Los Angeles, CA 90089,  
USA.

E-mail: martinpham@gmail.com

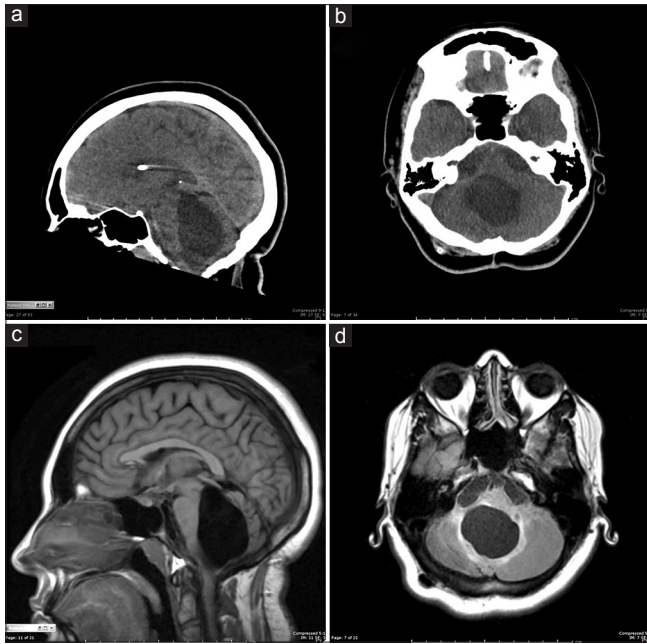
### Access this article online

Website: www.asianjns.org

DOI: 10.4103/ajns.AJNS\_82\_18

### Quick Response Code:





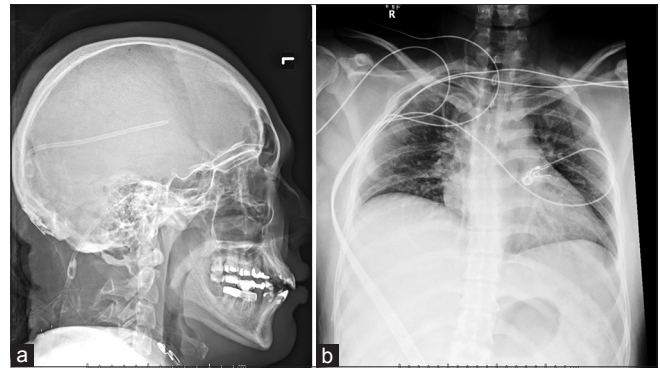
**Figure 1:** Sagittal (a) and axial (b) computed tomography imaging as well as sagittal (c) and axial (d) fluid-attenuated inversion recovery magnetic resonance imaging demonstrating dilatation of this patient's isolated fourth ventricle causing both cerebellar and brainstem compression

widely from theinion down to the inferior angle of the scapula.

For the cranial portion of the case, a linear incision was made down her prior scar from theinion to the C2 spinous process. The tissues were dissected in usual fashion down through her prior scar past her craniotomy site until her dura was identified and opened. The arachnoid adhesions from her prior tumor resection were carefully released and fenestrated widely for access into her fourth ventricle, under which clear CSF came out under moderate pressure.

For the posterior chest portion of the case, the 5<sup>th</sup> rib was estimated anatomically through both palpations and as being under the medial border of the scapular spine. A transverse incision was made on its superior border 4.5 cm off the midline to be lateral to the thoracic spine transverse process and rib tubercle. Monopolar electrocautery was used to carry the muscle dissection down to the posterior superior surface of the rib. The intercostal muscles were then atraumatically spread over the superior surface of the rib until the posterior parietal pleura was identified.

A shunt passer was tunneled subcutaneously from the cranial suboccipital incision to the posterior chest incision, and a shortened distal catheter was passed upward and secured to a Delta 0.5 valve (Medtronic Sofamor Danek, TN, USA). This was subsequently secured to a premeasured 5 cm proximal catheter that was laid inside the fourth ventricle. Catheter depth was planned to anticipate that once the posterior fossa contents collapse on decompression of the ventricular system, the catheter would not protrude into brainstem parenchyma. A posterior neck musculature



**Figure 2:** (a) Lateral skull X-ray showing appropriate positioning of the fourth ventriculopleural proximal catheter and valve. (b) Chest X-ray showing appropriate positioning of the right-sided distal shunt catheter in the pleural space without pneumothorax

pocket was then bluntly created to secure the valve so that closure of the suboccipital wound would not move the proximal catheter further intracranially as well.

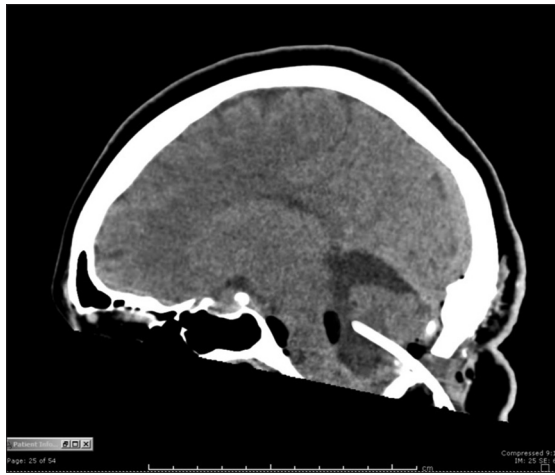At the posterior chest wound, a small hemostat was used to bluntly enter the intrapleural space, and the distal catheter was inserted inside. A pursestring stitch was placed around the catheter, the wound was filled with antibiotic irrigation and on a Valsalva maneuver to 40 mmHg; the suture was tightened to reduce the likelihood of a postoperative pneumothorax. Both cranial and posterior chest incisions were then closed in usual standard fashion.

### Postoperative course

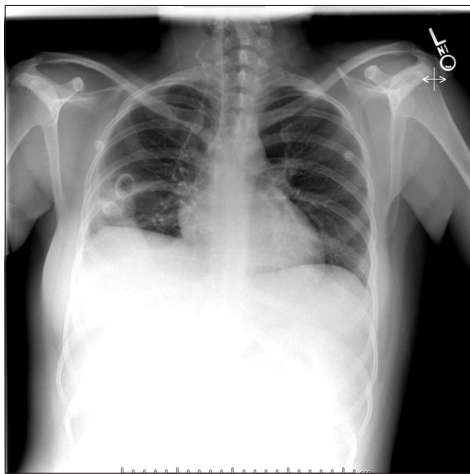
Postoperatively, the patient experienced immediate relief of her headaches and mild improvement with her 6<sup>th</sup> nerve palsy as well. Postoperative shunt series X-rays and CT imaging demonstrated good positioning of her shunt hardware without intracranial complications or pneumothorax [Figures 2 and 3]. She was discharged on postoperative day 2 without issues. At 1-year follow-up, she was clinically doing well with complete resolution of her 6<sup>th</sup> nerve palsy and routine shunt series, and MR imaging showed appropriate positioning of her hardware, continued decompression of her fourth ventricle, and no signs of hydrothorax or pleural effusion [Figures 4 and 5]. She did not experience any neurologic or pulmonary complications during this follow-up period.

### Discussion

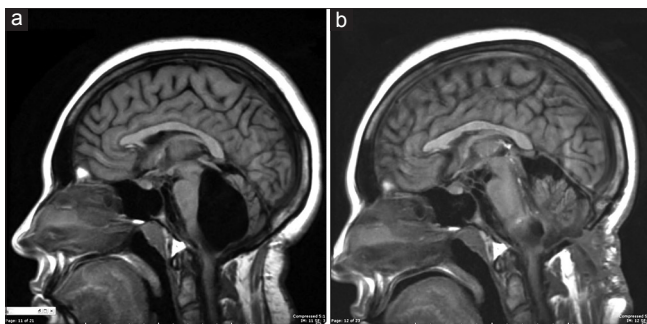
The isolated fourth ventricle was first described by Dandy, in 1921, and can be a rare late complication of lateral ventricular shunting for hydrocephalus.<sup>[4,8-11]</sup> Its occurrence in association with VP shunting has been reported to be at around 2.5% in several series.<sup>[12,13]</sup> A functional collapse occurs at the walls of the cerebral aqueduct due to the pressure gradient caused by the lateral ventricular shunt across the tentorium, and further closure of the outflow foramina of Luschka and foramen of Magendie isolates the fourth ventricle from the rest of the ventricular



**Figure 3:** Postoperative sagittal computed tomography imaging showing appropriate positioning of the fourth ventriculopleural proximal catheter within the fourth ventricle without impingement anteriorly against the brainstem



**Figure 4:** Chest X-ray at 1-year follow-up showing appropriate positioning of the right-sided distal shunt catheter in the pleural space without hydrothorax or pleural effusion. There has been interval movement of the catheter within the pleural space as compared to prior chest X-rays which would be expected with normal respiratory excursion



**Figure 5:** Preoperative (a) and routine postoperative (b) fluid-attenuated inversion recovery magnetic resonance imaging at 1-year comparing the difference after the placement of the fourth ventriculopleural shunt. At 1-year follow-up, the fourth ventricle is still decompressed without any further compression of the posterior fossa contents

system.<sup>[8]</sup> Subsequent dilatation of the fourth ventricle as its choroid plexus continues to produce CSF will

progressively compress its adjacent neural structures and causes symptoms of ataxia, nystagmus, dysarthria, cranial nerve palsies, eye movement disorders, and intracranial hypertension.<sup>[8,9,14]</sup> Because our patient had a history of prior posterior fossa surgery with resection of a pilocytic astrocytoma, she was at increased risk for the development of arachnoid adhesive scars that would change her CSF dynamics and ultimately obstruct her fourth ventricular CSF outflow tracts. Other risk factors that have been described include prematurity, intraventricular hemorrhage, and postinfectious hydrocephalus, conditions which can cause ependymal inflammation and closure of the fourth ventricular outlet as well.<sup>[4]</sup>

Indications for surgical intervention to decompress the dilated fourth ventricle usually revolve around symptomatology. This may be controversial, however, in the setting of infants or younger children with developmental delay in which symptoms may be harder to detect until later stages.<sup>[14-17]</sup> In those situations, some authors have advocated for operative treatment when there is persistent dilatation of the fourth ventricle in the setting of significant brainstem compression.<sup>[1]</sup>

Mohanty *et al.* recently conducted an excellent review of the various surgical options for isolated fourth ventricles.<sup>[1]</sup> They broadly classified the options into (a) suboccipital craniectomy and outlet fenestration, (b) fourth ventricular shunting procedures, and (c) endoscopic procedures. Although the fourth ventricular shunts have remained the mainstay of the treatment for decades,<sup>[12,15,18]</sup> the authors commented on the risks of brainstem injury through the burr hole trans cerebellar approach or the tediousness of the open midline transforaminal approach which requires repositioning from prone to supine for the peritoneal portion of the surgery. Not yet described, however, is placement of a VPL shunt for this condition in which case no repositioning is required.

Although VP shunts are the procedure of choice for hydrocephalus due to the large absorptive capacity of the peritoneal lining, the pleural space remains an acceptable alternative in select patients.<sup>[19,20]</sup> The most common long-term complication associated with VPL shunting is pleural effusion and hydrothorax.<sup>[21,22]</sup> In our patient, the decision to proceed with a VPL shunt was made under the assumption that the likelihood of hydrothorax was reduced because her VPL shunt would only be draining the CSF made from her fourth ventricle as opposed to her entire ventricular system.

For those surgeons familiar with the placement of frontal or occipital VPL shunts for hydrocephalus, surgical access to the pleural space is similar. Technical considerations include being far enough off the midline so that the surgeon is beyond the transverse process of the thoracic spine, but not so far that the surgeon is adjacent to the medial border of the scapula. Otherwise, placement of

the pleural catheter proceeds in standard fashion and the technique focuses on avoiding violation of the visceral pleura and obtaining a watertight closure to reduce the risk of postoperative pneumothorax. With regard to positioning, the patient's head should be positioned for the usual suboccipital approach, and this flexed forward position will also facilitate passing of the shunt passer subcutaneously from the cranial to the posterior chest incision. There were no unexpected difficulties with the shunt portion of our case, and it proceeded as would be expected in any supine frontal VPL shunt placement.

To the best of our knowledge, our case represents the first report of a fourth VPL shunt placed for a symptomatic isolated fourth ventricle from a single-stage prone position. Approaching the pleural space from the prone position for CSF diversion is feasible without any additional morbidity. At 1-year follow-up, our patient was still doing well without any shunt-related issues or complications.

#### Declaration of patient consent

The authors certify that they have obtained all appropriate patient consent forms. In the form the patient(s) has/have given his/her/their consent for his/her/their images and other clinical information to be reported in the journal. The patients understand that their names and initials will not be published and due efforts will be made to conceal their identity, but anonymity cannot be guaranteed.

#### Financial support and sponsorship

Nil.

#### Conflicts of interest

There are no conflicts of interest.

#### References

- Mohanty A, Manwaring K. Isolated fourth ventricle: To shunt or stent. *Oper Neurosurg (Hagerstown)* 2018;14:483-93.
- Harter DH. Management strategies for treatment of the trapped fourth ventricle. *Childs Nerv Syst* 2004;20:710-6.
- Teo C, Burson T, Misra S. Endoscopic treatment of the trapped fourth ventricle. *Neurosurgery* 1999;44:1257-61.
- Fritsch MJ, Kienke S, Manwaring KH, Mehdorn HM. Endoscopic aqueductoplasty and interventriculostomy for the treatment of isolated fourth ventricle in children. *Neurosurgery* 2004;55:372-7.
- Mohanty A. Endoscopic options in the management of isolated fourth ventricles. Case report. *J Neurosurg* 2005;103:73-8.
- Schulz M, Goelz L, Spors B, Haberl H, Thomale UW. Endoscopic treatment of isolated fourth ventricle: Clinical and radiological outcome. *Neurosurgery* 2012;70:847-58.
- Küpeli E, Yilmaz C, Akçay S. Pleural effusion following ventriculopleural shunt: Case reports and review of the literature. *Ann Thorac Med* 2010;5:166-70.
- Ali K, Nannapaneni R, Hamandi K. The isolated fourth ventricle. *BMJ Case Rep* 2013;2013. pii: bcr2013008791.
- Montgomery CT, Winfield JA. Fourth ventricular entrapment caused by rostrocaudal herniation following shunt malfunction. *Pediatr Neurosurg* 1993;19:209-14.
- Little AS, Zabramski JM, Nakaji P. Simplified aqueductal stenting for isolated fourth ventricle using a small-caliber flexible endoscope in a patient with neurococcidiomycosis: Technical case report. *Neurosurgery* 2010;66:373-4.
- Shin M, Morita A, Asano S, Ueki K, Kirino T. Neuroendoscopic aqueductal stent placement procedure for isolated fourth ventricle after ventricular shunt placement. Case report. *J Neurosurg* 2000;92:1036-9.
- Eder HG, Leber KA, Gruber W. Complications after shunting isolated IV ventricles. *Childs Nerv Syst* 1997;13:13-6.
- Kojima N, Tamaki N, Matsumoto S. Clinical evaluation of an isolated fourth ventricle. *No To Shinkei* 1988;40:679-87.
- Cinalli G, Spennato P, Savarese L, Ruggiero C, Aliberti F, Cuomo L, *et al.* Endoscopic aqueductoplasty and placement of a stent in the cerebral aqueduct in the management of isolated fourth ventricle in children. *J Neurosurg* 2006;104:21-7.
- Sagan LM, Kojder I, Poncyjusz W. Endoscopic aqueductal stent placement for the treatment of a trapped fourth ventricle. *J Neurosurg* 2006;105:275-80.
- Udayakumaran S, Biyani N, Rosenbaum DP, Ben-Sira L, Constantini S, Beni-Adani L, *et al.* Posterior fossa craniotomy for trapped fourth ventricle in shunt-treated hydrocephalic children: Long-term outcome. *J Neurosurg Pediatr* 2011;7:52-63.
- Gallo P, Szathmari A, Simon E, Ricci-Franchi AC, Rousselle C, Hermier M, *et al.* The endoscopic trans-fourth ventricle aqueductoplasty and stent placement for the treatment of trapped fourth ventricle: Long-term results in a series of 18 consecutive patients. *Neurol India* 2012;60:271-7.
- Lee M, Leahu D, Weiner HL, Abbott R, Wisoff JH, Epstein FJ, *et al.* Complications of fourth-ventricular shunts. *Pediatr Neurosurg* 1995;22:309-13.
- Ratliff M, Unterberg A, Bächli H. Ventriculo-bipleural shunt as last resort in a 4-year-old child in whom a VP and VA shunt failed. *J Neurosurg Pediatr* 2016;17:285-8.
- Ransohoff J. Ventriculo-pleural anastomosis in treatment of midline obstructive neoplasms. *J Neurosurg* 1954;11:295-8.
- Venes JL. Pleural fluid effusion and eosinophilia following ventriculo-pleural shunting. *Dev Med Child Neurol* 1974;16:72-6.
- Venes JL, Shaw RK. Ventriculopleural shunting in the management of hydrocephalus. *Childs Brain* 1979;5:45-50.