

## Pneumorrhachis following Chest Injury: A Rare Entity

### Abstract

Pneumorrhachis (PR) – the phenomenon of intraspinal air – is a rare radiological finding. The presence of intraspinal air is usually after epidural injections, spinal manipulations, synovial cysts, degenerative disc disease, and epidural abscess. PR is mostly asymptomatic but can also be symptomatic. We report a case with PR after chest trauma and attempt to explain its development.

**Keywords:** Extradural, intradural, intraspinal, pneumorrhachis

### Introduction

Pneumorrhachis (PR) – the phenomenon of intraspinal air – is a rare radiological finding. The presence of intraspinal air is usually after epidural injections, spinal manipulations, synovial cysts, degenerative disc disease, and epidural abscess. PR is mostly asymptomatic but can also be symptomatic. We report a case with PR after chest trauma and attempt to explain its development.

### Case Report

A 20-year-old male patient was brought to the emergency room with a history of assault. The patient was conscious and oriented. He had tachypnea. Rest vitals were stable. He had subcutaneous emphysema in the neck and thorax. Glasgow Coma Scale was E4V5M6 and had no neurological deficit. He had lacerated wounds over the posterior and lateral aspect of neck, face, and upper part of the left side chest. Chest X-ray revealed the presence of subcutaneous emphysema. Computed tomography (CT) chest was performed which showed the left side pneumothorax with air in superior mediastinum (along with great vessels), subcutaneous tissue emphysema in the left side chest wall with air in the lower cervical spine and upper dorsal spine. Chest tube inserted on left side. He was managed with intravenous fluids, antibiotics, and oxygen inhalation. His condition improved gradually. Repeat chest X-ray was performed which showed resolution of

pneumothorax and subsequently chest tube was removed and he was discharged in a satisfactory condition. Magnetic resonance imaging of the cervico-thoracic spine was performed at follow-up which showed resolution of air in cervico-thoracic spine.

### Discussion

The term PR was coined in 1987.<sup>[1]</sup> In the literature, intraspinal air has been described secondary to basal skull fracture, instrumentation, epidural abscess, synovial cysts, or disc degeneration.<sup>[2]</sup> However, intraspinal air occurring in association with a chest trauma is extremely rare and only few cases have been reported. Scialdone and Wagle have reported one patient developing intraspinal air following a blunt chest trauma.<sup>[3]</sup> Review performed by Chaichana *et al.* reported fifty cases of PR in literature.<sup>[4]</sup>

PR can be intradural/internal or extradural/external. Extradural PR is usually not dangerous while intradural PR is believed to be a marker of severe injury.<sup>[5]</sup> PR is usually asymptomatic, but radiculopathy and myelopathy occur depending on air quantity. One possible mechanism in blunt thoracic injury can be the rupture of alveoli after hyperpressure of thorax with glottis closed.<sup>[2]</sup> Sudden intrapleural compression leads to rupture of the lung alveoles. Probably, it is followed by pneumo-dissection through the vascular sheath and leading to accumulation in the mediastinum, pericardium and retroperitoneum, and more rarely into the spinal canal.<sup>[2]</sup>

**Shivender Sobti,  
S. Bhaskar<sup>1</sup>,  
Rajesh K. Sharma<sup>1</sup>,  
Ajay Choudhary<sup>1</sup>**

Department of Neurosurgery,  
Christian Medical College and  
Hospital, Ludhiana, Punjab,  
<sup>1</sup>Department of Neurosurgery,  
Postgraduate Institute of  
Medical Education and  
Research, Dr. RML Hospital,  
New Delhi, India

#### Address for correspondence:

Dr. Shivender Sobti,  
11/12B, Opposite BCM  
School, Basant Avenue, Dugri  
Phase II, Ludhiana - 141 013,  
Punjab, India.  
E-mail: sobtish@gmail.com

#### Access this article online

Website: [www.asianjns.org](http://www.asianjns.org)

DOI: 10.4103/ajns.AJNS\_81\_16

#### Quick Response Code:



**How to cite this article:** Sobti S, Bhaskar S, Sharma RK, Choudhary A. Pneumorrhachis following chest injury: A rare entity. Asian J Neurosurg 2018;13:440-1.

This is an open access journal, and articles are distributed under the terms of the Creative Commons Attribution-NonCommercial-ShareAlike 4.0 License, which allows others to remix, tweak, and build upon the work non-commercially, as long as appropriate credit is given and the new creations are licensed under the identical terms.

For reprints contact: [reprints@medknow.com](mailto:reprints@medknow.com)

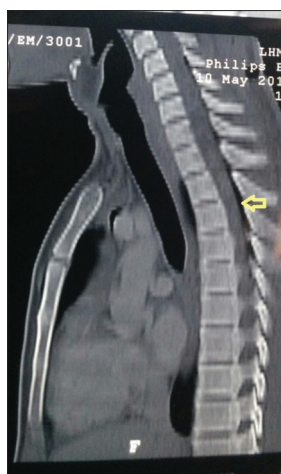


Figure 1: Computed tomography showing air in the cervicodorsal region

The absence of a fascial barrier between the posterior mediastinum and neck also leads the air to migrate from these spaces into the spinal canal through the intervertebral foramina.<sup>[3,6]</sup> In external PR, epidural air usually collects in the posterior epidural space due to lower resistance from the loose connective tissue as compared with rich vascular network anteriorly.<sup>[5]</sup> In our case, we think, epidural spinal air may have migrated from subcutaneous emphysema in the neck through the neural foramina. As air inside the canal did not produce any neurological deficit by pressure on the cord. Hence, the patient was managed conservatively.

Figure 1 shows CT of cervicodorsal spine depicting intraspinal air in the cervical and dorsal region. Figure 2 is of CT thorax shows pneumothorax and pneumomediastinum.

The treatment of patients with PR involves management of other injuries. PR is usually asymptomatic and resorbs spontaneously<sup>[5]</sup> and is mostly managed conservatively. PR which is associated with cerebrospinal fluid leakage is associated with decreased intraspinal pressure, and has got benign course. Tension PR may develop when intraspinal air under pressure enters the cranio-spinal compartment, in combination with a one-way valve mechanism causes pneumocephalous with nervous tissue compression requiring intervention. Prophylactic antibiotics are not recommended in cases of external PR and patients with internal PR without signs and symptoms of meningitis.<sup>[5]</sup>

Chest X-ray for diagnosing pneumothorax and cervical subcutaneous emphysema is important in the suspicion of intraspinal air. CT scan should be performed in the

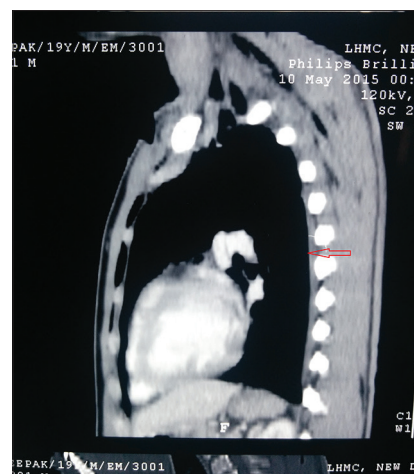

Figure 2: Computed tomography thorax showing pneumothorax and pneumomediastinum

diagnosing intraspinal air in the patients with traumatic pneumothorax/subcutaneous emphysema.<sup>[2]</sup>

## Conclusion

PR is a rare entity. High index of suspicion should be kept in patients with chest, neck, and head trauma. It is usually self-limiting. Management is directed to the associated pathologies. Intradural PR is usually a predictor of severe injury.

## Financial support and sponsorship

Nil.

## Conflicts of interest

There are no conflicts of interest.

## References

1. Newbold RG, Wiener MD, Vogler JB 3<sup>rd</sup>, Martinez S. Traumatic pneumorrhachis. *AJR Am J Roentgenol* 1987;148:615-6.
2. Krasoudakis A, Marathianos S, Tsiminikakis N, Chavredakis E, Arhontakis G. Intraspinial air after blunt thoracic trauma. *J Indian Assoc Pediatr Surg* 2006;11:248-9.
3. Scialdone CJ, Wagle W. Intraspinial air: An unusual manifestation of blunt chest trauma. *Clin Imaging* 1990;14:59-60.
4. Chaichana KL, Pradilla G, Witham TF, Gokaslan ZL, Bydon A. The clinical significance of pneumorachis: A case report and review of the literature. *J Trauma* 2010;68:736-44.
5. Dwarkanath S, Banerji A, Chandramouli BA. Post-traumatic intradural pneumorrhachis: A rare entity. *Indian J Neurotrauma* 2009;6:151-2.
6. Defouilloy C, Galy C, Lobjoie E, Strunski V, Ossart M. Epidural pneumatosis: A benign complication of benign pneumomediastinum. *Eur Respir J* 1995;8:1806-7.