

Giant Spinal Intradural Metastatic Adenocarcinoma of Unknown Primary: A Rare Case Report

Abstract

Giant intradural metastases of nonneurogenic origin involving multiple segments represent an extremely rare manifestation of an unknown primary. The respective literature is very scarce. We present a 45-year-old female with complaints of low back pain for 4 years, involuntary urination for 2 years, and difficulty in using both lower limbs for 1 month. Examination revealed paraparesis with hypotonia. Imaging of lumbosacral spine revealed that expansile lytic destruction of vertebral bodies and posterior elements was noted from D8 to S2 vertebra and a large-sized patchy enhancing heterogeneous intradural extramedullary lesion was noted in D8–S2 level. Decompressive laminectomy from D11 to L4 vertebra and subtotal excision of the lesion were done. There was a marked improvement in the lower limb weakness and low back pain postoperatively. Histopathology revealed metastatic adenocarcinoma. Immunohistochemistry showed epithelial membrane antigen positivity. Accordingly, the aim of the surgery is strictly palliative. The majority of patients benefit with respect to neurological deficit/pain independent of the extent of resection. Thus, decompressive surgery is recommended to increase the quality of life. The occurrence of intradural spinal metastasis is rare. Only few cases of intra dural spinal metastasis involving multiple cord segments and osteolytic bony erosions have been documented. Hence this case is being presented here for its rarity and its uniqueness.

Keywords: *Giant intradural metastasis, posterior decompression, unknown primary*

Introduction

Giant intradural metastases of nonneurogenic origin involving multiple segments represent an extremely rare manifestation of an unknown primary. The respective literature is very scarce.

Case Report

A 45-year-old female patient presented with complaints of low back pain for 4 years, involuntary urination for 2 years, and difficulty in using both lower limbs for 1 month. Examination revealed paraparesis with hypotonia, absent lower limb reflexes, and decreased anal tone. All sensory modalities decreased from L1. Computed tomography (CT) lumbosacral spine revealed expansile lytic destruction of vertebral bodies and posterior elements from D8 to S2 vertebra [Figures 1 and 2]. Magnetic resonance imaging (MRI) Lumbo-sacral spine revealed a large patchy hetero intense lesion noted from D8–S2 level (Intra

Dural Extra Medullary - IDEM) with erosion of D11–S2 and enhances with contrast [Figures 3 and 4]. Decompressive laminectomy was carried out from D11 to L4 vertebra, and a highly vascular IDEM exophytic lesion from D8 to S2 grayish-white was noted pushing the cord laterally [Figure 5]. The cord was found to be thinned out, and bony erosions were noted intraoperatively [Figure 6]. Subtotal excision of the lesion was done [Figure 7]. There was a marked improvement in the lower limb weakness and low back pain postoperatively. Histopathology revealed metastatic adenocarcinoma. Immunohistochemistry showed epithelial membrane antigen positivity. CT chest and abdomen was normal. Panendoscopy and colonoscopy were also negative. The patient has completed radiotherapy.

Discussion

Spinal metastases can be anatomically classified into (i) intramedullary, (ii) IDEM, and (iii) extradural. Although spinal metastases are common, almost 95% of these are extradural lesions.^[1]

How to cite this article: Meenakshisundaram N, Dhandapani B. Giant spinal intradural metastatic adenocarcinoma of unknown primary: A rare case report. *Asian J Neurosurg* 2019;14:949-51.

**Natarajan
Meenakshisundaram,
Balasubramanian
Dhandapani**

*Department of Neurosurgery,
Institute of Neurosurgery,
Madras Medical College,
Chennai, Tamil Nadu, India*

Address for correspondence:

*Dr. Natarajan
Meenakshisundaram,
Room No. 16, PG Men's
Hostel, Superspeciality Block,
Chennai - 600 003, Tamil Nadu,
India.
E-mail: nats12031985@gmail.
com*

Access this article online

Website: www.asianjns.org

DOI: 10.4103/ajns.AJNS_65_18

Quick Response Code:



This is an open access journal, and articles are distributed under the terms of the Creative Commons Attribution-NonCommercial-ShareAlike 4.0 License, which allows others to remix, tweak, and build upon the work non-commercially, as long as appropriate credit is given and the new creations are licensed under the identical terms.

For reprints contact: reprints@medknow.com



Figure 1: CT LS Spine showing expansile lytic destruction of vertebral bodies and posterior elements from D8 to S2 vertebra

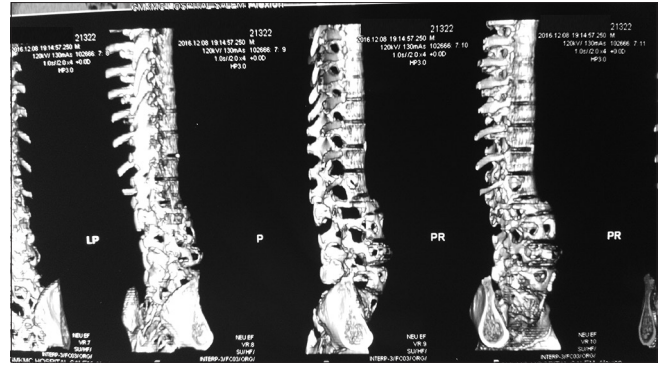


Figure 2: Computed tomography lumbosacral spine with three-dimensional reconstruction

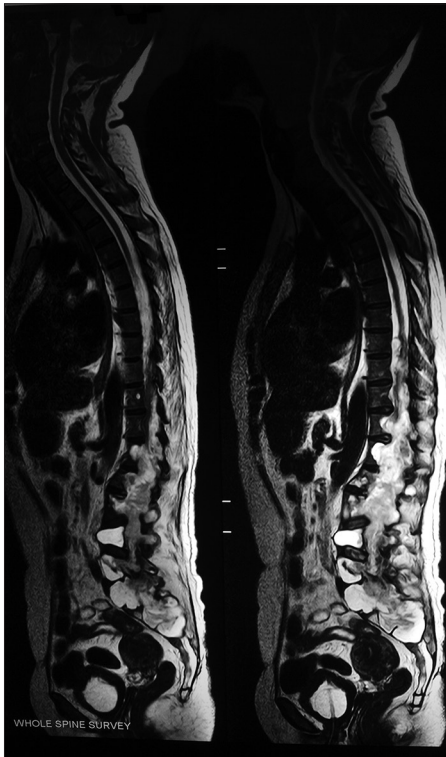

Figure 3: MRI LS Spine T2 Sagittal section showing the extent of the lesion from D8 to S2

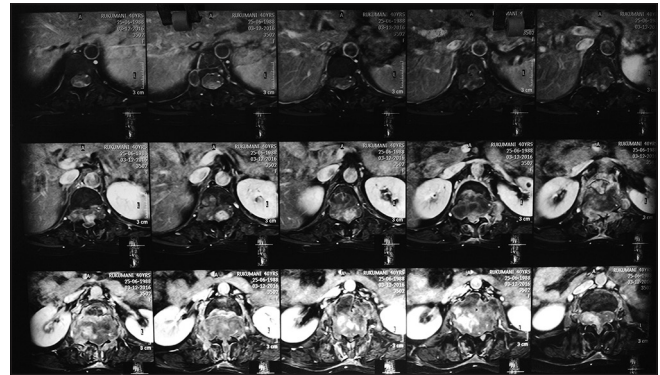


Figure 4: MRI LS Spine axial section showing the invasive nature of the lesion

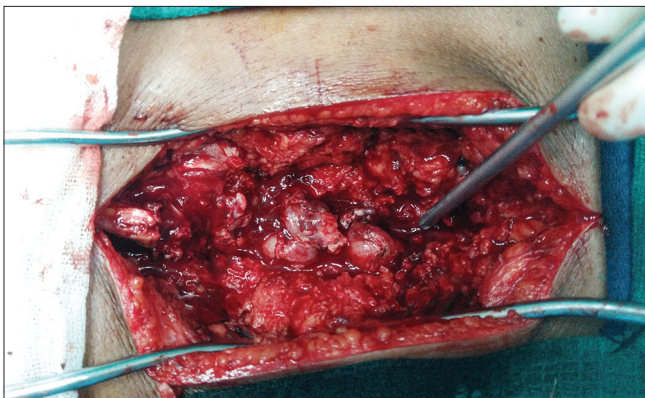


Figure 5: Intra operative image showing the extensive metastatic lesion

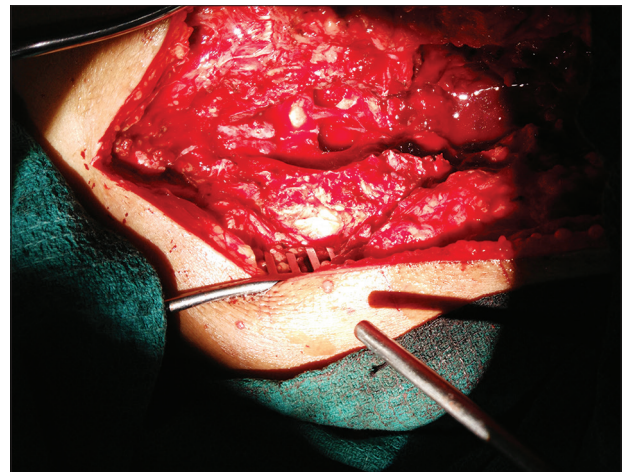


Figure 6: Intra operative image showing the osteolytic lesions in the vertebra after subtotal excision of the metastatic lesion

Although vertebral and epidural metastases are commonly seen to occur in malignancies, intradural metastases are very rare. Intradural lesions occur within the dural sac and can be anatomically classified into (a) IDEM and (b) intradural intramedullary. Extramedullary lesions are most commonly nonneoplastic. The differential diagnoses for IDEM spinal lesions include meningiomas, neurofibromas, and nerve sheath tumors.^[2]

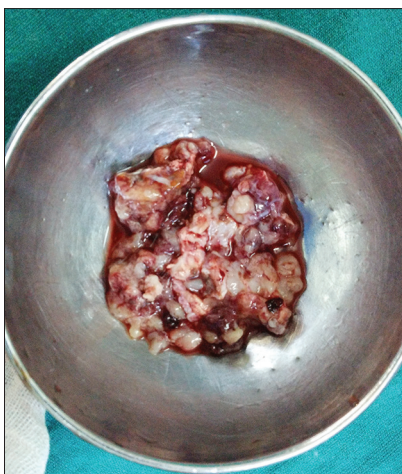

Figure 7: Excised specimen

Pain is the most common symptom in 90% of cases.^[3] Associated neurological deficits manifest based on the location of the lesion. Gadolinium-enhanced MRI is the preferred imaging modality to assess the lesion.

Five possible routes of spread, for the development of intradural spinal metastases from outside the central nervous system, include: (1) through the rich venous plexus, (2) perineural lymphatics, (3) seeding from involved osseous structures to the cerebrospinal fluid (CSF) through the dura, (4) spreading through subarachnoid space, and (5) hematogenous spreading through the arterial system.

IDEM metastases are commonly thought to originate from CSF seeding. Initially, tumor cells are transferred to the brain, and then, they enter the CSF and are transported throughout the nervous system by CSF flow. This can result in either multifocal or diffuse infiltration of the leptomeninges. Finally, metastatic tumors arise as IDEM lesions (drop metastasis).

Decompressive laminectomy was once the primary treatment for malignant spinal cord compression. Although laminectomy allows for a larger posterior space for the spinal cord, most metastatic impingement originates from the vertebral body and leads to primarily ventral pressure.^[4,5]

With the availability of radiation therapy (RT), laminectomy was combined with adjuvant radiation. With the addition of RT, improved results were obtained with approximately 30%–50% of patients remaining ambulatory after treatment.^[6-9] However, retrospective studies suggested that radiation alone was as effective as laminectomy plus postoperative RT in the treatment of malignant spinal cord compression.^[10,11] Nevertheless, combined treatment remained the standard until 1980 when a small randomized trial^[12] suggested that RT alone was as effective as laminectomy with adjuvant radiation in the treatment of spinal cord compression.

Conclusions

Intradural metastases are associated with limited survival time. Accordingly, the aim of the surgery is strictly palliative.

The majority of patients benefit with respect to neurological deficit/pain independent of the extent of resection. Thus, decompressive surgery is recommended to increase the quality of life. The occurrence of intradural spinal metastasis is rare and that there is insufficient literature to document the involvement of multiple segments of the cord incontinuity and bony erosions from D11 to S2 by the metastatic lesion. Hence, we report a rare case of giant intradural spinal metastatic adenocarcinoma of unknown origin.

Declaration of patient consent

The authors certify that they have obtained all appropriate patient consent forms. In the form the patient(s) has/have given his/her/their consent for his/her/their images and other clinical information to be reported in the journal. The patients understand that their names and initials will not be published and due efforts will be made to conceal their identity, but anonymity cannot be guaranteed.

Financial support and sponsorship

Nil.

Conflicts of interest

There are no conflicts of interest.

References

- Schick U, Marquardt G, Lorenz R. Intradural and extradural spinal metastases. *Neurosurg Rev* 2001;24:1-5.
- Chamberlain MC, Tredway TL. Adult primary intradural spinal cord tumors: A review. *Curr Neurol Neurosci Rep* 2011;11:320-8.
- Jacobs WB, Perrin RG. Evaluation and treatment of spinal metastases: An overview. *Neurosurg Focus* 2001;11:e10.
- Hirabayashi H, Ebara S, Kinoshita T, Yuzawa Y, Nakamura I, Takahashi J, *et al*. Clinical outcome and survival after palliative surgery for spinal metastases: Palliative surgery in spinal metastases. *Cancer* 2003;97:476-84.
- Levi M, Dale J, Stein M, Ben-Shahar M, Ben-Arush M, Milstein D, *et al*. The management of metastatic spinal cord compression: A radiotherapeutic success ceiling. *Int J Radiat Oncol Biol Phys* 1993;27:231-4.
- Akeyson EW, McCutcheon IE. Single-stage posterior vertebrectomy and replacement combined with posterior instrumentation for spinal metastasis. *J Neurosurg* 1996;85:211-20.
- Byrne TN. Spinal cord compression from epidural metastases. *N Engl J Med* 1992;327:614-9.
- Loblaw DA, Perry J, Chambers A, Laperriere NJ. Systematic review of the diagnosis and management of malignant extradural spinal cord compression: The cancer care Ontario practice guidelines initiative's neuro-oncology disease site group. *J Clin Oncol* 2005;23:2028-37.
- Marshall LF, Langfitt TW. Combined therapy for metastatic extradural tumors of the spine. *Cancer* 1977;40:2067-70.
- Wright RL. Malignant tumors in the spinal extradural space: Results of surgical treatment. *Ann Surg* 1963;157:227-31.
- Gilbert RW, Kim JH, Posner JB. Epidural spinal cord compression from metastatic tumor: Diagnosis and treatment. *Ann Neurol* 1978;3:40-51.
- Young RF, Post EM, King GA. Treatment of spinal epidural metastases. Randomized prospective comparison of laminectomy and radiotherapy. *J Neurosurg* 1980;53:741-8.