

Performing Awake Surgeries in Times of COVID-19 – A Singapore Experience

Abstract

Introduction: It has been 17 years since the severe acute respiratory syndrome outbreak and Singapore is facing yet another daunting pandemic – the novel coronavirus (COVID-19). To date, there are 57,607 cases and 27 casualties. This deadly pandemic requires significant changes especially in the field of awake surgeries for intra-axial tumors that routinely involve long clinic consults, significant interactions between patient and multiple other team members pre, intra, and postoperatively. **Materials and Methods:** A retrospective review of all awake cases done during the COVID-19 pandemic from February to June 2020 was done. In this article, we outline the rigorous measures adopted during the COVID-19 pandemic that has allowed us to proceed with awake surgeries and intraoperative mapping at our institution. **Results and Discussion:** We have divided the protocol into various phases of care of patients planned for an awake craniotomy. Preoperatively, teleconsults have been used where possible thereby limiting multiple hospital visits and interaction. Intraoperatively, safety nets have been established during asleep-awake-asleep phases of awake craniotomy for all the team members. Postoperatively, early discharge and teleconsult are being employed for rehabilitation and follow-ups. **Conclusions:** Multiple studies have shown that with intraoperative mapping, we can improve neurological outcomes. As the future of the pandemic remains unknown, the authors believe that surgical treatment should not be delayed for intracranial tumors. Awake craniotomies and intraoperative mapping can be safely carried out by adopting the described protocols with combination of multiple checkpoints and usage of telecommunication.

Keywords: Awake surgeries, COVID-19, glioma, protocols

Introduction

Singapore experienced the outbreak of severe acute respiratory syndrome (SARS) in 2003 which led to a total of 238 cases with 33 fatalities. Multiple chains of transmissions were identified, and after aggressive implementation of stringent measures with surveillance, isolation, and quarantine policy, the disease was eventually contained.^[1] It has been 17 years since the SARS outbreak, and Singapore is facing yet another daunting pandemic, novel coronavirus (COVID-19). The first case was reported on January 23, 2020, and at the time of writing this article, we have confirmed 57,607 cases with 27 mortalities.^[2] A government multiministry taskforce was assembled on January 22, 2020, to direct and coordinate the nation's efforts in response to the outbreak.^[3]

The government escalated the risk assessment from DOSCORN from yellow

to orange on February 7, 2020, in view of the increasing number of unlinked cases in the community.^[4] A series of “circuit breaker” (a local term for lockdowns) measures have been introduced at regular intervals with aim to contain the disease in the community.^[4] The Ministry of Health published guidelines for the health-care sector on April 4, 2020,^[5] detailing a list of essential and nonessential procedures, the latter is the ones which must be postponed until the circuit breaker measures have been removed. Excision of primary and secondary intracranial tumors is allowed. Various hospitals have placed strict guidelines about patient assessment, availability of adequate protective gear for all health-care staff involved, and early discharge to prevent any potential transmission.

Latest developments in the understanding of eloquence of the brain neuronal networks and neuronal plasticity have

**Swati Jain,
Will Loh¹,
Hui-Minn Chan²,
Calvin Lam³,
Tseng Tsai Yeo,
Lwin Sein,
Vincent Nga,
Kejia Teo**

*Division of Neurosurgery,
University Surgical Cluster,
National University Health
System, Departments of
¹Anaesthesia, ²Psychological
Medicine and ³Rehabilitation,
National University Health
System, Singapore*

Address for correspondence:

*Dr. Swati Jain,
Division of Neurosurgery,
University Surgical Cluster,
National University Health
System, 1E, Kent Ridge
Road, 119 228, Singapore.
E-mail: swati_jain@nuhs.edu.sg*

Access this article online

Website: www.asianjns.org

DOI: 10.4103/ajns.AJNS_61_21

Quick Response Code:



How to cite this article: Jain S, Loh W, Chan HM, Lam C, Yeo TT, Sein L, *et al.* Performing awake surgeries in times of COVID-19 – A Singapore experience. *Asian J Neurosurg* 2021;16:685-91.

Submitted: 14-Feb-2021

Revised: 11-Mar-2021

Accepted: 12-Jun-2021

Published: 18-Dec-2021

This is an open access journal, and articles are distributed under the terms of the Creative Commons Attribution-NonCommercial-ShareAlike 4.0 License, which allows others to remix, tweak, and build upon the work non-commercially, as long as appropriate credit is given and the new creations are licensed under the identical terms.

For reprints contact: WKHLRPMedknow_reprints@wolterskluwer.com

allowed us to perform resection of primary and secondary tumors located in the eloquent cortex without causing significant neurological deficits.^[6-8] For the past 5 years, our institution has developed our own local protocol for awake surgery and asleep mapping in the resection of intra-axial supratentorial tumors. We have recently shown that systematic and individually tailored multimodal workflow to cortico-subcortical mapping and monitoring allows for safe resection of both primary and secondary brain tumors.^[9] A multidisciplinary team consisting of a neurosurgeon, neuroanesthetist, neuropsychologist, speech therapist, and neurophysiologist is involved in the care of the patient right from the first encounter. The patient will be evaluated by the anesthetist for anesthetic risks and suitability for awake surgery. Our neuropsychologist performs a baseline neuropsychological assessment and a rehearsal of expected intraoperative evaluation if surgery is being done awake. As our institution does not have an inhouse neurophysiologist, we engage the services of a commercial neuromonitoring company to assist with the intraoperative electromyographies and somatosensory evoked potentials/motor evoked potentials recordings. The average duration of an awake surgery commonly lasts around 6 h (skin to skin), depending on the size of tumor. Postoperatively, the patients will be seen by a team of rehabilitation doctors and allied health (speech, occupational, and physiotherapists), whereby they will undergo aggressive speech and general rehabilitation. The measures introduced during COVID-19 pandemic require significant changes to the described protocol. In this article, we have outlined the various stages in the preparation of patients undergoing resection of intra-axial tumors and postoperative management among the COVID-19 pandemic in our institution. We also present our own experience in utilizing this protocol during this period.

Materials and Methods

Preoperative evaluation and timing of surgery

Since the onset of the “circuit breaker,” all health-care workers in our institution are divided into 2 separate teams (inpatient and outpatient team) to mitigate cross infections. Clinic cases are screened by the neurosurgery senior resident rostered to the outpatient team. Conditions such as tumors are given priority for clinic visits. A few days before the clinic consultation, a special COVID-19 advisory in the form of an automated text message is forwarded to patients. In this way, patients and their accompanying family member (restricted to one per patient) are preevaluated for the presence of any respiratory symptoms before their review in the clinic. In addition, they are required to declare if they have been contact traced by the Ministry of Health due to potential exposure to the virus. On the day of the appointment, all patients and only 1 accompanying person will undergo a temperature screen and symptom check as well as are asked about

recent travel history. Clinic waiting rooms have been transformed to enable adherence to safe distancing requirements. It is mandatory that all patients wear a mask during the consultation. Due to limitation in the availability of COVID-19 tests, screening tests such as nasal swabs are not conducted for patients before surgery.

In the spirit of minimizing nonessential surgical procedures during the worst of the COVID-19 outbreak, patients who are “asymptomatic” and have been incidentally found on magnetic resonance imaging (MRI) to have a likely low-grade glial tumor were counseled for consideration of delay in their surgery with repeat surveillance imaging planned in 6 weeks. Although this “wait and see” approach is not ideal and even contrary to the recommendations of early excision for low-grade gliomas,^[6,10,11] it is deemed a necessary step to be taken during the pandemic. However, if they have symptoms of uncontrolled seizures, new neurological deficits (for the case of high-grade gliomas), or even rapid radiological progression, early surgery is planned. Multidisciplinary tumor board has now been moved to an online platform in spirit of minimizing interactions among different specialties.

Patients are then reviewed by the neuropsychologist. The assessment continues to be conducted face-to-face in the clinic due to the complexity of tests involved. Additional efforts are made to schedule the assessment on the same day as their visit to the neuroanesthetist to reduce unnecessary travel for the patient. On the day of the appointment, as detailed in the above section, the patient (and accompanying family member, if any) will be screened for possible COVID-19 symptoms. Should there be a need, the neuropsychologist will use recommended protective equipment as per hospital guidelines to allow for a safe and complete evaluation. In addition to the usage of compulsory face mask, a further adjustment made during the COVID-19 period is to have patients who report feeling “under the weather” (but who do not have any of the main symptoms of COVID-19) don gloves while interacting with neuropsychological test materials. Special care is made to ensure the clinic room, and test materials are disinfected with alcohol wipes before and after the session. Patients are also reviewed by a dedicated anesthesiologist through a teleconsult system and counseled for awake surgery. Routine airway assessment is performed by video. If a patient is unable to attend a teleconsultation, a routine clinic assessment is performed.

All cases are also presented to the head of department before their listing in the elective theaters.

Intraoperative protocols

Our institution follows a sedation protocol for awake craniotomies.^[12,13] Patients scheduled for surgery have been classified as low risk, and hence, standard droplet precautions are taken during anesthesia with minimal

personnel in occupational therapy. Patients are sedated with dexmedetomidine and propofol to avoid airway manipulation and risk of aerosolizing potential virus particles. Techniques such as total intravenous anesthesia and airway devices are avoided to minimize airway manipulation. Patient is positioned by the neurosurgeon, and all electrodes are placed by the neurophysiologist.

For the surgery, surgeons wear adequate protective equipment including face shield (and N95 mask) or protective eye equipment if loupes or microscope is not being used. Minimal staff is present in theater during the craniotomy to reduce exposure from the bone dust created.

If airway manipulation is required during the surgery such as during the conversion to general anesthesia, requiring laryngeal mask insertion or removal, the anesthesiologist dons airborne PPE due to the risk of aerosolization from bagging and airway manipulation. The neurophysiologist and neuropsychologist are then allowed to enter the operative theater, again both donning adequate PPE. This set up is maintained throughout the awake phase.

Patient is given a microphone to allow clarity during verbalization of language tasks. Due to the nature of the neuropsychologist's involvement in the awake phase (i.e., needing to interact with the patient up close to be able to assess response quality as well as to maintain motivation and boost morale), it is difficult to adhere to recommended safe distancing measures of 1 m. Nevertheless, the risk of potential transmission of COVID-19 is assessed to be low given the vigorous patient screening and usage of personal protective equipment.

When the awake phase is completed, the patient is then re-sedated but kept breathing spontaneously, and surgery is completed following similar protocols as per initial sleep phase of the surgery.

Postoperative management

All COVID-19-positive patients or COVID-19 suspect are admitted to designate COVID-19/pneumonia wards. Furthermore, significant number of high dependency and intensive care beds has been allocated to potential COVID-19 patients. Due to the limitations in high dependency and intensive care beds, postoperatively patients are monitored in "make-shift neurosurgery high dependency wards." This refers to the management of patients in general wards with heightened nursing vigilance (ratio of 1 trained neuro nurse to 2 patients). Patients undergo early rehabilitation the following day. This practice has not changed since pre-COVID-19 times. However, the usual rehabilitation pathway involves step down care to rehabilitation hospitals for the patients. Instead, patients are sent home around 4 days postoperatively. The physiotherapist will conduct a functional assessment of their mobility, while the occupational therapist will assess a patient's ability to perform day-to-day tasks across various

activities of daily living. The speech therapist will conduct a basic screen of a patient's language and cognitive function while communicating to both patient and family about the patient's recovery trajectory and goals of care within the first few sessions. If the rehabilitative physicians deem postoperative rehabilitation necessary, they would be transferred to an adjunct facility for a short course of their rehab.

Depending on their level of deficits, further outpatient speech therapy services may be provided through telepractice. This allows for service delivery at a distance in real time with interactive audio and video connection.^[14] Communication treatments are well suited for telepractice given their audiovisual nature.^[15] Patients are chosen based on a set of predetermined criteria, including their availability and access to technology, their willingness to receive services online, appropriate cognitive function, and good hearing and visual ability.

Postoperative neuropsychological assessment is typically conducted at 3 months. Some patients may be recalled earlier. For instance, if the patient is returning to study or employment (i.e., regaining their premorbid societal roles), they will be offered an appointment to characterize their postsurgical neuropsychological status and for profile-specific recommendations to their school or workplace. All other patients will receive a follow-up phone call and have their assessment deferred for the time being.

Results and Discussion

Since the start of the circuit breaker measures over from February to June 2020, 10 patients have undergone resection of tumors with mapping. In 2019, number of patients who required awake or asleep mapping was 10 as well. Intuitively, we expected that there would be a decrease in number of patients due to the measures introduced. With no disruption of emergency services and primary care centers continuing to refer patients to tertiary centers if deemed urgent, it did not have an impact on overall volume. The data were derived from departmental audit that has already been deidentified.

Preoperative characteristics and evaluation

Table 1 illustrates the characteristics of ten patients who underwent surgery during this period. Fifty percent of the patients had low-grade tumors on final histology. Three of these patients had shown recurrence of tumor on follow-up imaging. The other two patients presented with signs and symptoms of decompensation in the form of new-onset seizures and progressive neurology. Hence, after discussion with the patients, decision was made to proceed with surgical resection of these tumors.

Except for two patients who presented to the emergency department, all other patients only had a 2–3 visits

Table 1: Characteristics of 10 patients who underwent surgery during coronavirus-19 at National University Hospital, Singapore

Patient No.	Age	Number of pre-operative visits	Type of Mapping	Final Histology	Location	Presenting Neurological Deficit	Immediate post-operative Neurology	Complications	Neurology on day of follow up	Days to rehab review
1	54	3	Awake	Grade II Diffuse Astrocytoma	Right insula	Seizures (Generalised Tonic-Clonic)	Left hemiparesis, left gaze preference	None	Near complete resolution of left hemiparesis	2
2	33	Presented to ED*	Asleep	Grade III High Grade Glioma	Right frontal lobe	Griddiness with unstead gait	Mild left hemiparesis	None	Baseline left hemiparesis	2
3	35	2	Awake	Grade II Diffuse Astrocytoma	Left parietal lobe	Headaches, right upper limb numbness	Agraphia, finger agnosia	None	Apraxia resolved, no other neurological deficit	2
4	45	2	Asleep	Grade II oligodendroglioma	Right frontal lobe	Persistent seizures	Persistent poorly controlled seizures	Persistent seizures	Back to baseline neurology with well controlled seizures	10
5	73	Presented to ED*	Asleep	Grade IV Glioblastoma	Right temporal lobe	Unsteady gait	Acute lobar haematoma	Acute lobar haematoma	Returned to baseline	6
6	40	2	Awake	Grade II astrocytoma	Left insula	Abnormal tongue movement	No neurological deficit	None	No neurological deficit	2
7	65	2	Asleep	Radiation Necrosis (lung)	Right pre-central gyrus (right frontal lobe)	Left lower limb weakness, left lower limb focal seizures	Left lower limb plegia	None	Left lower limb weakness back to baseline	1
8	52	2	Asleep	Metastatic breast cancer	Right pre-central gyrus (right frontal lobe)	Left upper limb weakness	Left upper limb weakness	None	At baseline as per discharge	2
9	34	3	Awake	Grade III Astrocytoma	Right parietal lobe	Seizures (Generalised Tonic-Clonic)	No neurological deficit	None	No neurological deficit	2
10	31	2	Awake	Grade II astrocytoma	Left frontal lobe	Worsening headaches	Speech latency	None	Back to baseline	2

*ED – Emergency Department

before their admission for surgery. These included one visit with the neurosurgeon for evaluation and consent, one visit where they were evaluated by the anesthetist and neuropsychologist. If patient was unable to make a decision during the clinic visit, they e-mailed the consultant neurosurgeon if they agreed to proceed with the operation. Any further clarifications were made through phone consults before their admission. Additional cooperation from our medical oncology colleagues allowed us to review the two cases of metastatic tumors in the same clinic visit with the oncologist, thus minimizing recurrent trips to the hospital. This contrasts with the pre-COVID-19 era, where each patient was expected to have at least 4–5 visits. Any internal referrals from medical oncology required scheduling of visit on a separate clinic day and repeat of the process illustrated prior.

Reduction of clinic visits during these times has allowed us to now streamline the processes as we enter the post-COVID-19 era in preoperative evaluation. The clinic managers now aim at coordinating the anesthesia and neuropsychologist review on the same day. Feasibility of online communicating platforms has allowed early review of cases at the multidisciplinary board to reduce the lead time to treatment.

Intraoperative protocols and experience

Five patients underwent awake craniotomy and resection of the tumors. Other five patients underwent asleep mapping. Patients undergoing awake craniotomy completed all tasks without any issues intraoperatively despite the changes in protocols and decrease number of personnel in the operating theater. Any procedures required for airway manipulation intraoperatively required the surgeon to leave the theater.

The surgical team would then remain in the adjoining scrub room until all airway manipulation has been completed.

With the assistance of a microphone, language tasks were completed and did not require the neuropsychologist to be in close proximity with the patient. The usage of microphone was implemented as part of COVID-19 measures. We realized that the microphone provided clarity of the sound under the drapes and ability of the surgeon to hear the exchange clearly. Henceforth, we have made the usage of microphone compulsory for all awake procedures.

Although asleep mapping did not require significant personnel interaction or manipulation of airway, strict protocols were still followed to minimize the number of people in the operating theater to prevent any cross contamination. Overall, the risks of aerosolization were considered low due to the rigorous screening preoperatively as described in the protocol.

Postoperative outcomes and rehabilitation

Barring the two patients who suffered postoperative complications, all patients were transferred to the “make-shift neurosurgery high dependency wards.” This required training of the nursing staff to assess for possible complications in the first 24 h in a general ward setting with closer monitoring. All patients remained stable in these wards with no requirement of escalation of monitoring or transfer to intensive care unit.

One patient developed intractable seizures that required prolonged intubation and was transferred to intensive care unit postoperatively. He was extubated on postoperative day 3 and transferred to the general ward on day 5. The other patient was found to be intermittently drowsy in

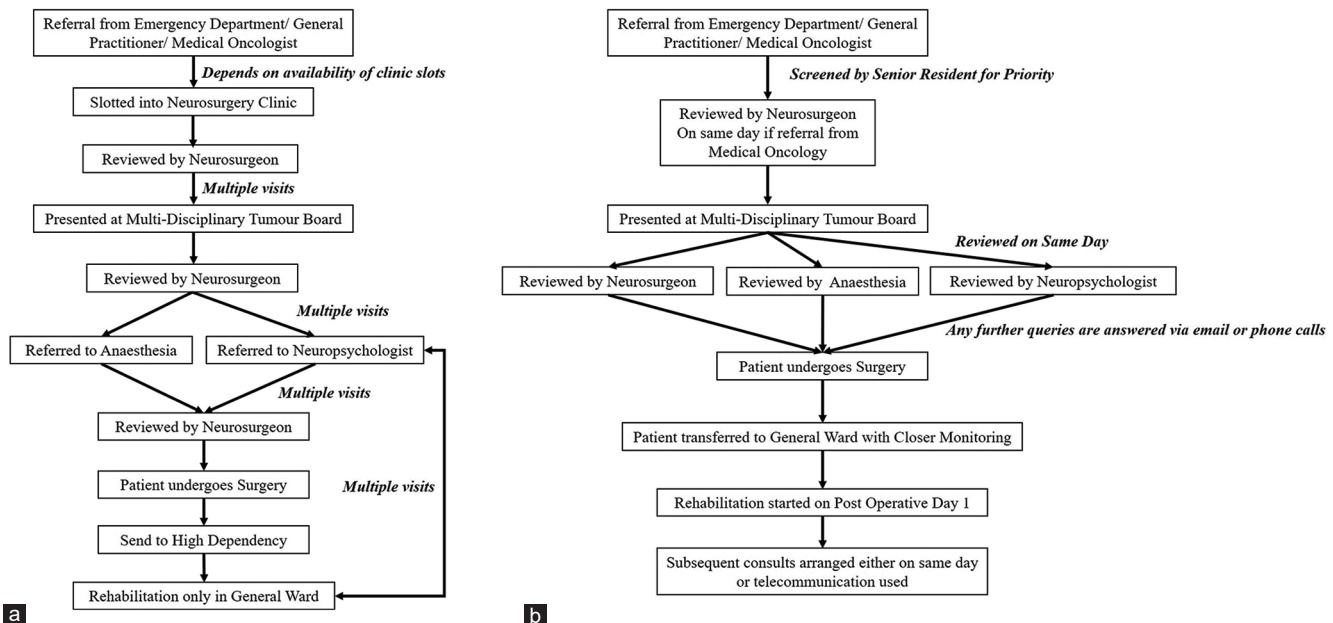


Figure 1: (a) General workflow after referral for supratentorial brain tumor. Significant multiple visits were involved at various stages of the counseling (b) New workflow after implementation of changes due to COVID-19

the postoperative anesthesia care unit with uncontrolled hypertension. A repeat scan showed the presence of a lobar hematoma which was evacuated. Subsequently, his postoperative recovery was uneventful.

Before the implementation of this protocol, surgeries were occasionally canceled in the event; no high dependency bed was available. With the availability of nursing personnel and monitoring equipment in a general ward setting, the presence of a high dependency bed is no longer a requirement to proceed with an elective procedure.

On postoperative day 1, all patients underwent an early MRI. The “clean cases” were imaged first in our hospital to prevent any cross contamination from the suspect cases from other specialized. They were immediately assessed by the physiotherapist and speech therapist after completion of any scheduled imaging or procedures. Formal physiotherapy was then started on postoperative day 2. Speech therapy assessment and rehabilitation were started on postoperative day 1 including swallowing and language assessment.

Apart from the 2 patients with postoperative complications, all patients were discharged within 5 days postoperatively. Speech therapy visits were done through online telecommunication platform. A follow-up phone consult was conducted by the neuropsychologist while awaiting formal 3-month assessment. Surgical wound review, postoperative evaluation, and assessment for further adjuvant chemo and radiotherapy were done in a single clinic visit.

Pre-COVID-19, no formal assessment was done by the physiotherapist until the patient was transferred to the general ward, usually on postoperative day 2. This led to a delay in initiation of rehabilitation to day 3 or 4 depending on the timing of the first assessment. While in the high dependency, speech therapy assessment was only limited to swallowing. Speech rehabilitation was initiated in general ward once patient was deemed medically fit for discharge or for transfer to rehabilitation hospital. The culmination of these small temporal delays resulted in significant overall postponement of discharge, rehabilitation, and follow-ups. Learning from this experience that required a time-sensitive decision-making, several discussions are being carried out between neurosurgery and the department of rehabilitation to allow early assessment and initiation of rehabilitation in these patients.

Figure 1 shows the differences between the workflows after the implementation of changes during COVID-19.

Conclusions

Since the implementation of the circuit breaker, our local transmitted cases have dropped to single digit in the community. With gradual opening of economy and movement of Singapore to “Phase 2,” an increase in community numbers are expected with possible larger

clusters unfolding. Being part of the National University Cancer Institute, we continue to see a significant number of patients with brain tumors. The straightforward answer to the management of intra-axial tumors during COVID-19 pandemic would require reverting to standard craniotomy and performing a conservative resection without mapping. However, multiple studies have shown that with intraoperative mapping, we can improve neurological outcomes and subsequent quality of life by maximizing the extent of resection and limiting damage to eloquent brain. Since the beginning of circuit breaker measures, we have safely performed awake craniotomies with no evidence of COVID-19 transmission among the health-care professionals involved. We believe by adopting the described protocols with combination of multiple checkpoints, and usage of telecommunication allows us to proceed with safe intraoperative mapping during this pandemic.

Financial support and sponsorship

Nil.

Conflicts of interest

There are no conflicts of interest.

References

1. Tan CC. SARS in Singapore – key lessons from an epidemic. *Ann Acad Med Singap* 2006;35:345-9.
2. Singapore Reports 31 New COVID-19 Cases, Including 9 Imported. Available from: <https://www.channelnewsasia.com/news/singapore/covid-19-new-cases-singapore-community-imported-moh-sep-21-13128676>. Last accessed on 2021 May 03]
3. Baker JA. Singapore Forms Wuhan Virus Ministerial Task Force, Imported Case ‘Inevitable’: Gan Kim Yong; 2020.<https://www.channelnewsasia.com/news/singapore/wuhan-virus-singapore-ministerial-task-force-inevitable-12301610>. [Last accessed on 2021 May 23].
4. Mohan M. Coronavirus Outbreak: Singapore Raises DORSCON Level to Orange; Schools to Suspend Inter-School, External Activities; 2020. <https://www.channelnewsasia.com/news/singapore/wuhan-coronavirus-dorscon-orange-singapore-risk-assessment-1240518asd0>. [Last accessed on 2021 May 23].
5. Singapore MoH. Continuation of Essential Healthcare Services during Period of Heightened Safe Distancing Measures. Available from: <https://www.moh.gov.sg/news-highlights/details/continuation-of-essential-healthcare-services-during-period-of-heightened-safe-distancing-measures>. Last accessed on 2021 May 03]
6. Duffau H. Long-term outcomes after supratotal resection of diffuse low-grade gliomas: A consecutive series with 11-year follow-up. *Acta Neurochir (Wien)* 2016;158:51-8.
7. Straathof M, Sinke MR, Dijkhuizen RM, Otte WM. A systematic review on the quantitative relationship between structural and functional network connectivity strength in mammalian brains. *J Cereb Blood Flow Metab* 2019;39:189-209.
8. Yordanova YN, Duffau H. Supratotal resection of diffuse gliomas – An overview of its multifaceted implications. *Neurochirurgie* 2017;63:243-9.
9. Hamer RP, Jain S, Teo C, Loh WN, Chan HM, Yeo TT, *et al.*

- Optimizing the onco-functional balance in supratentorial brain tumour surgery: A single institution's initial experience with intraoperative cortico-subcortical mapping and monitoring in Singapore. *J Clin Neurosci* 2020;79:224-30.
10. Duffau H. A new philosophy in surgery for diffuse low-grade glioma (DLGG): Oncological and functional outcomes. *Neuro Chir* 2013;59:2-8.
 11. Duffau H. Resecting diffuse low-grade gliomas to the boundaries of brain functions: A new concept in surgical neuro-oncology. *J Neurosurg Sci* 2015;59:361-71.
 12. Dilmen OK, Akcil EF, Oguz A, Vehid H, Tunali Y. Comparison of conscious sedation and asleep-awake-asleep techniques for awake craniotomy. *J Clin Neurosci* 2017;35:30-4.
 13. Rajan S, Cata JP, Nada E, Weil R, Pal R, Avitsian R. Asleep-awake-asleep craniotomy: A comparison with general anesthesia for resection of supratentorial tumors. *J Clin Neurosci* 2013;20:1068-73.
 14. Ashaweb. Telepractice: Overview. 2020; Available from: <https://www.asha.org/PRPSpecificTopic.aspx?folderid=8589934956>. Last accessed on 2021 May 03]
 15. Brennan D, Georgeadis A, Baron C. Telerehabilitation tools for the provision of remote speech-language treatment. *Top Stroke Rehabil* 2002;8:71-8.