

Dural Arteriovenous Fistula Arising after Intracranial Surgery in Posterior Fossa of Nondominant Sinus: Two Cases and Literature Review

Abstract

The results of recent clinical and experimental studies suggest that the most important factor associated with the pathogenesis of dural arteriovenous fistula (AVF) is sinus thrombosis and subsequent venous or intrasinus hypertension. Here, we describe two patients who each developed a dural AVF after a posterior fossa craniotomy on the side of the nondominant or hypoplastic transverse (TS)-sigmoid (SS) sinuses. A 63-year-old female underwent surgical resection of a meningioma in the left cerebellopontine angle. Preoperative subtraction digital angiography (DSA) revealed a hypoplastic, ipsilateral left TS-SS and the sinus occlusion was revealed after surgery. Sixteen months later, she presented with a progressive left retroauricular, pulse-synchronous bruit. An AVF in the left TS-SS region was diagnosed by DSA and treated with transvenous coil embolization. The patient recovered without neurological deterioration. A 56-year-old female underwent surgical removal of an epidermoid tumor in the right cerebellopontine angle. Preoperative DSA revealed severe, ipsilateral right TS stenosis and the sinus occlusion was revealed after surgery. Two years later, she presented with the progressive right retroauricular, pulse-synchronous bruit, which was diagnosed by DSA as dural AVF in the right TS-SS region. She was treated with transvenous coil embolization and recovered without neurological deterioration. Sinus manipulation during intracranial surgery carries a potential risk of dural AVF development and this should be carefully considered, even when the ipsilateral TS-SS is nondominant or appears hypoplastic.

Keywords: *Development hypoplastic sinus, dural arteriovenous fistulae, postoperative outcome*

Introduction

Intracranial dural arteriovenous fistulae (AVF) are defined as abnormal arteriovenous shunts or connections that occur within the dura mater. Unlike arteriovenous malformations, the development of dural AVF seems more similar to that of acquired lesions.^[1] Sinus thrombosis after trauma, infection, and surgery can cause venous outflow obstruction and venous hypertension and frequently arises in patients with dural AVF.^[1-4] However, the pathophysiology of dural AVF development has not been elucidated. This report describes two patients who developed a dural AVF in the nondominant or hypoplastic transverse (TS)-sigmoid (SS) sinuses after the sinus occlusion during intracranial surgery. Both patients were evaluated by angiography just before the original surgery and when a dural AVF was diagnosed. We discuss the pathogenesis of dural AVF after the sinus occlusion

during intracranial surgery in the posterior fossa based on our experience with these patients.

Case Reports

Case 1

A benign meningioma was surgically resected from the left cerebellopontine angle of a 63-year-old female using a left lateral suboccipital approach [Figure 1a and b]. Preoperative DSA revealed that the ipsilateral left TS-SS was hypoplastic, and the contralateral right TS-SS was dominant [Figure 1c]. The sinus occlusion was revealed after surgery and 6 months after craniotomy, three-dimensional enhanced computed tomography angiography (3D-CTA) showed venous reflux in the left TS-SS region [Figure 1d and e]. Sixteen months after craniotomy, she presented with the progressive left retroauricular pulse-synchronous bruit. Recurrent meningioma was not found using

**Shohei Yokoyama,
Ichiro Nakagawa,
Masashi Kotsugi,
Daisuke Wajima,
Takeshi Wada¹,
Kimihiko
Kichikawa¹,
Hiroyuki Nakase**

*Departments of Neurosurgery
and ¹Radiology, Nara Medical
University, Nara Prefecture,
Japan*

Address for correspondence:

*Dr. Ichiro Nakagawa,
Department of Neurosurgery,
Nara Medical University,
840 Shijo-cho, Kashihara,
Nara 634-8522, Japan.
E-mail: nakagawa@naramed-u.
ac.jp*

Access this article online

Website: www.asianjns.org

DOI: 10.4103/ajns.AJNS_5_19

Quick Response Code:



How to cite this article: Yokoyama S, Nakagawa I, Kotsugi M, Wajima D, Wada T, Kichikawa K, *et al.* Dural arteriovenous fistula arising after intracranial surgery in posterior fossa of nondominant sinus: Two cases and literature review. *Asian J Neurosurg* 2019;14:602-6.

This is an open access journal, and articles are distributed under the terms of the Creative Commons Attribution-NonCommercial-ShareAlike 4.0 License, which allows others to remix, tweak, and build upon the work non-commercially, as long as appropriate credit is given and the new creations are licensed under the identical terms.

For reprints contact: reprints@medknow.com

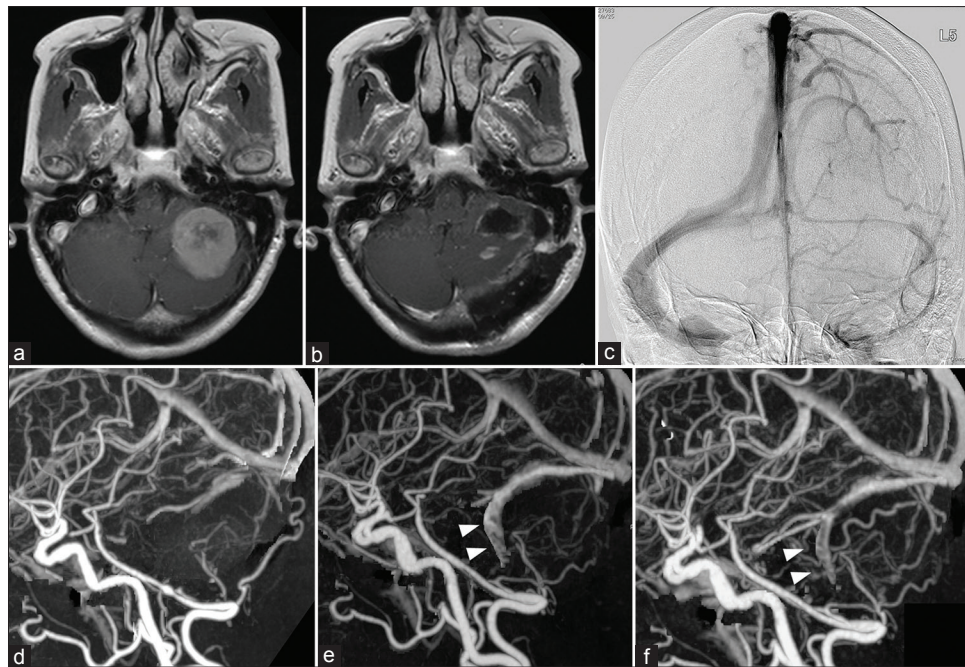


Figure 1: Surgical resection of a left cerebellar brain tumor in a 53-year-old female. Resection of the left cerebellar brain tumor (a) proceeded via the lateral suboccipital approach (b). Preoperative digital subtraction angiography shows hypoplastic left, compared with the right transverse sinus (c). Preoperative three-dimensional-computed tomography angiography shows no abnormalities (d). Slight cerebral venous reflux evident on a three-dimensional-computed tomography angiography image at 6 months after surgery (e; arrowhead) became symptomatic (left retro-auricular bruit) at 16 months after surgery (f; arrowhead)

magnetic resonance imaging (MRI) and angiography, but 3D-CTA showed worsening venous reflux [Figure 1f]. Dural AVF in the left TS-SS fed by the left ascending pharyngeal and occipital (OA) arteries with retrograde drainage to the left inferior petrosal sinus with SS occlusion was confirmed by DSA [Figure 2a]. She was treated with transvenous coil embolization through a transconfluence approach, and she recovered without neurological deterioration [Figure 2b-d]. The patient has remained free of recurrent dural AVF for 5 years.

Case 2

An epidermoid tumor in the right cerebellopontine angle of a 56-year-old female was surgically resected through a right presigmoid, transpetrosal, and retrosigmoid approach [Figure 3a and b]. Preoperative 3D-CTA and DSA revealed severe ipsilateral right TS stenosis and dominant contralateral left TS-SS, [Figure 3c and d] and the sinus occlusion was revealed after surgery. Two years after intracranial surgery, she presented with the progressive right retroauricular pulse-synchronous bruit. Dural AVF in the right TS-SS region fed by the right OA was diagnosed by DSA, and the isolated sinus appearance with retrograde drainage to the right vein of Labbe and an inferior temporal vein was shown [Figure 4a]. She underwent transvenous coil embolization through a transconfluence approach, without neurological deterioration [Figure 4b-d]. The patient has remained free of recurrent dural AVF for 5 years.

Discussion

The etiology of dural AVF in the posterior fossa remains uncertain. Clinical observations and serial angiographic findings have indicated that many dural AVF are acquired and that sinus thrombosis,^[1] sinus hypertension,^[1] intracranial abscess,^[2] and trauma^[3] might contribute to their formation. The notion that this condition is acquired is supported by the finding that they frequently develop after trauma, craniotomy, and sinus thrombosis. Clinical observations indicate that pathological changes in the intracranial sinus, including sinus thrombosis, can lead to dural AVF formation.^[4] Notably, 39%–80% of dural AVF are associated with intracranial sinus thrombosis, and 78% of patients without thrombosis have sinus dysplasia, stenosis, septation, or distortion.^[5-11]

Table 1 shows published case series of dural AVF developing after intracranial surgery.^[12-15] Most of them occurred at the site of a prior intracranial surgery, regardless of the dominance or stenosis of venous or occluded sinuses before intracranial surgery. These authors speculated that venous thrombosis after sinus occlusion due to intracranial surgery might cause a fistula by opening the physiological shunts in the dura mater, which would consequently redirect arterial blood into the cortical veins, followed by the eventual development of a dural AVF at the site of the original intracranial surgery. On the other hand, experimental studies that have investigated the mechanisms or pathogenesis of dural AVF have found that they can be induced by venous hypertension without sinus or venous

Table 1: Summary of reports regarding dural arteriovenous fistula after intracranial surgery

Authors	Age	Sex	Disease for intracranial surgery	Precraniotomy sinus findings of DSA	Craniotomy side	Development duration for DAVF	Location of DAVF
Sakaki <i>et al.</i> ^[12]	50	Male	Right mandible ameloblastoma	No abnormality	Right	6 months	Right TS-SS
	59	Female	Left retromastoid meningioma	Left SS occlusion by the tumor	Left	42 months	Left TS-SS
	65	Male	Right neurinoma meningioma	No abnormality	Right	60 months	Right TS-SS
	56	Male	Right hypoglossal neurinoma	Right SS occlusion by the tumor	Right	54 months	Right TS-SS
	31	Female	Left glomus jugulare tumor	No abnormality	Left	22 months	Left TS-SS
Convers <i>et al.</i> ^[13]	N/A	N/A	Right tentorial meningioma	SSS and right TS occlusion	Right	4 months	Right TS-SS
Nabors <i>et al.</i> ^[14]	70	Female	Right trigeminal neuralgia	Not mentioned	Right	4 months	Right TS-SS
	62	Male	Left hemifacial spasm	Not mentioned	Left	24 months	Left TS-SS
Sasaki <i>et al.</i> ^[15]	58	Male	Right trigeminal neurinoma	No abnormality	Right	24 months	Right TS-SS
Present cases	63	Female	Left CP angle meningioma	Left hypoplastic TS-SS	Left	6 months	Left TS-SS
	56	Female	Right CP angle epidermoid tumor	Right TS severe stenosis	Right	24 months	Right TS-SS

DAVF – Dural arteriovenous fistulae; CP – Cerebellopontine; TS – Transverse sinus; SS – Sigmoid sinus; SSS – Superior sagittal sinus; DSA – Digital subtraction angiography; N/A – Not applicable

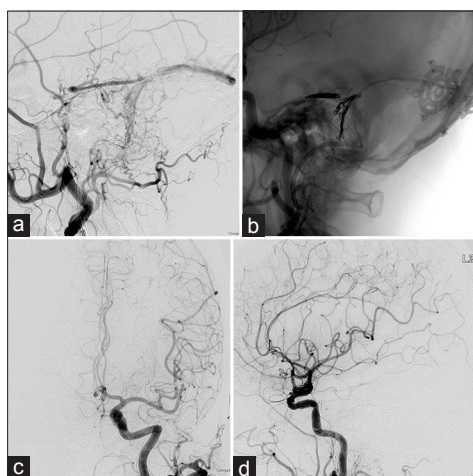


Figure 2: Postoperative arterio-venous shunt in the patient described in Figure 1. digital subtraction angiography shows arterio-venous shunt, fed by the occipital artery and stylomastoid branch, and drained into the left transverse (TS) and left superior petrosal sinuses (a, left common carotid angiography lateral [Lat] view) of the transverse sinus/sigmoid sinus dural arteriovenous fistula (Cognard type 2a + b). Under local anesthesia, a 6 Fr Envoy MPD 90-cm sheath catheter (Cordis, Miami Lakes, FL, USA) was inserted via the right femoral artery for digital subtraction angiography. An Excelsior 1018 microcatheter was introduced with Cerulean G and 5 Fr ENVOY (Cordis) catheters into the right jugular vein. A shunt point was transvenously coil embolized using an Echelon-14 microcatheter (MicroTherapeutics, Natick, MA, USA) via the transconfluence approach (b, left common carotid angiography Lat live image; c, left common carotid angiography AP view; d, left common carotid angiography Lat view). Symptoms of left retroauricular bruit immediately disappeared thereafter

thrombosis.^[16,17] Therefore, an exposure of the vessels to venous hypertension and subsequent local hypoperfusion might cause vessel dilation and the loss of sphincter control in arterioles. Increased intraluminal pressure in the vessels stimulates angiogenesis, and the subsequent

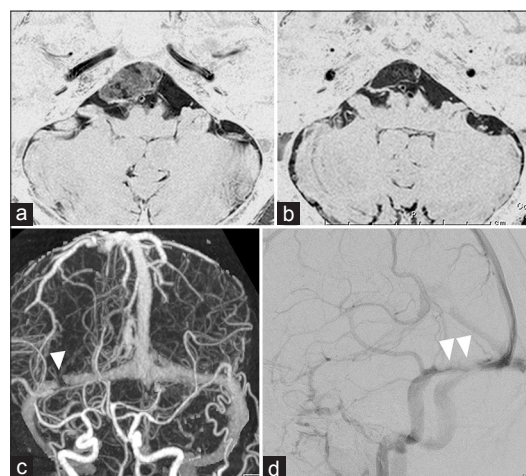


Figure 3: Brain tumor at the right cerebellopontine angle and temporal middle fossa of a 54-year-old female. Constructive interference in steady state magnetic resonance image shows a tumor at the right cerebellopontine angle and temporal middle fossa (a). Tumor resection via the presigmoid transpetrosal and retrosigmoid approach on magnetic resonance image constructive interference in steady state image (b). Preoperative three-dimensional enhanced computed tomography angiography (c) and digital subtraction angiography (d) images show right transverse sinus stenosis (arrowhead)

formation of direct connections to a sinus or vein results in the development of dural AVF. Shin *et al.* suggested that venous sinus hypertension increases the production of vascular endothelial growth factor (VEGF),^[18] which might help to increase the angiogenesis and lead to an AVF. Matrix metalloproteinase-9 (MMP-9) is closely associated with neovascularization and it might synergistically work with VEGF.^[19] Furthermore, cerebral venous sinus thrombosis induces MMP-9 upregulation and inflammatory activation.^[19] Dural AVF developed in our patients

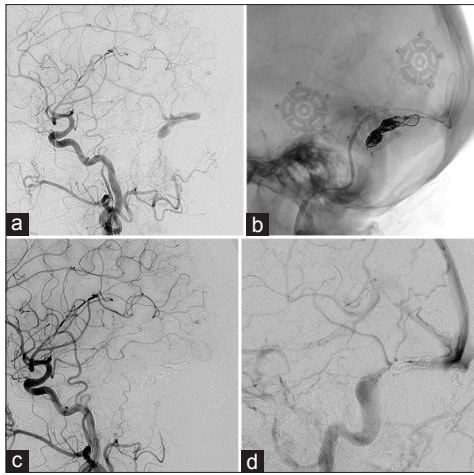


Figure 4: Postoperative arterio-venous shunt in the patient described in Figure 3. The patient presented with right retroauricular bruit 2 years after surgery and digital subtraction angiography revealed cerebral venous reflux and arterio-venous shunt in the right transverse sinus region. The shunt was fed by occipital artery and drained by the right vein of Labbe and inferior temporal vein (a, left common carotid angiography Lat view). This was diagnosed as transverse sinus/sigmoid sinus dural arteriovenous fistula (Cognard type 2a + b). Under local anesthesia, a 6 Fr Envoy MPD 90-cm sheath catheter was inserted via the right femoral artery for digital subtraction angiography. Then, an Excelsior 1018 microcatheter was introduced together with Tempo 4 and 5 Fr ENVOY catheters into the left jugular vein. A shunt point was transvenously coil embolized using a microcatheter via transconfluence approach (b, right common carotid angiography Lat live view). Symptoms and arterio-venous shunt immediately disappeared (c, right common carotid angiography Lat view arterial phase; d, right common carotid angiography Lat view venophase)

after posterior fossa craniotomy of the nondominant or hypoplastic TS-SS side. We speculate that the nondominant or hypoplastic sinus became occluded after posterior fossa craniotomy in our patients and that subsequent local intrasinus hypertension and local hypoperfusion induced the opening of a physiological shunt that stimulated angiogenesis, which subsequently resulted in a dural AVF.

The transverse and sigmoid sinuses are exposed and manipulated during presigmoid, transpetrosal and retrosigmoid approaches to the skull base, but there are a scant data available on the incidence of venous sinus occlusion after surgery. Jean *et al.* reported that 10% of patients were discovered asymptomatic sinus occlusion after posterior fossa craniotomy.^[20,21] The sigmoid and transverse sinuses can be occluded during presigmoid, transpetrosal approaches to the skull base tumor.^[22] It is important to follow-up MRI because there is a possibility of occurrence of dural AVF if asymptomatic sinus occlusion is observed after posterior fossa surgery.

Transfemoral embolization of the feeding arteries, embolization of the affected sinus or complete surgical excision is recommended to treat dural AVF.^[4] We believe that all of these procedures, including surgical excision, are valuable in the appropriate setting. Transvenous embolization of venous channels appears to be the first choice because to penetrate a fistulous point using glue injected via transarterial embolization

is difficult.^[4-23] Shunts in our patients were completely occluded after transvenous sinus embolization through a transconfluence approach because these affected sinuses were not associated with normal cerebral venous drainage. Embolization using Onyx (eV3 Neurovascular, Inc., Irvine, CA, USA), which penetrates better and allows for robust injections, is a new and promising modality for treating dural AVF.^[24-28] However, Onyx has the same disadvantage as other embolic materials in that its ability to penetrate small dangerous anastomoses to cranial nerves or vessels supplying the brain cannot be controlled.^[29] Findings from long-term follow-up are awaited to establish the value of embolization with Onyx for dural AVF.^[30]

Conclusion

Sinus manipulation during intracranial surgery of the posterior fossa carries a risk of sinus occlusion and developing postoperative dural AVF. This should be considered even if the ipsilateral TS-SS is nondominant or appears hypoplastic.

Informed consent

Informed consent was obtained from all individual participants included in the study.

Declaration of patient consent

The authors certify that they have obtained all appropriate patient consent forms. In the form, the patient has given her consent for her images and other clinical information to be reported in the journal. The patient understands that name and initials will not be published and due efforts will be made to conceal identity, but anonymity cannot be guaranteed.

Financial support and sponsorship

Nil.

Conflicts of interest

There are no conflicts of interest.

References

1. Padgett DH. The development of the cranial venous system in man, from the viewpoint of comparative anatomy. *Contrib Embryol* 1957;36:79-140.
2. Streeter GL. The developmental alterations in the vascular system of the brain of the human embryo. *Contrib Embryol* 1918;8:5-38.
3. Herman JM, Spetzler RF, Bederson JB, Kurbat JM, Zabramski JM. Genesis of a dural arteriovenous malformation in a rat model. *J Neurosurg* 1995;83:539-45.
4. Brainin M, Haddad K. Meningeal arteriovenous fistula associated with an intracerebral abscess. *Neurochirurgia (Stuttg)* 1982;25:108-10.
5. Awad IA, Little JR, Akarawi WP, Ahl J. Intracranial dural arteriovenous malformations: Factors predisposing to an aggressive neurological course. *J Neurosurg* 1990;72:839-50.
6. Bink A, Berkefeld J, Kraus L, Senft C, Ziemann U, du Mesnil de Rochemont R, *et al.* Long-term outcome in patients treated for benign dural arteriovenous fistulas of the posterior fossa. *Neuroradiology* 2011;53:493-500.

7. Houser OW, Campbell JK, Campbell RJ, Sundt TM Jr. Arteriovenous malformation affecting the transverse dural venous sinus – An acquired lesion. *Mayo Clin Proc* 1979;54:651-61.
8. Mironov A. Pathogenetical consideration of spontaneous dural arteriovenous fistulas (DAVFs). *Acta Neurochir (Wien)* 1994;131:45-58.
9. Sundt TM Jr., Piepgras DG. The surgical approach to arteriovenous malformations of the lateral and sigmoid dural sinuses. *J Neurosurg* 1983;59:32-9.
10. Troffkin NA, Graham CB 3rd, Berkmen T, Wakhloo AK. Combined transvenous and transarterial embolization of a tentorial-incisural dural arteriovenous malformation followed by primary stent placement in the associated stenotic straight sinus. Case report. *J Neurosurg* 2003;99:579-83.
11. Tsai LK, Jeng JS, Liu HM, Wang HJ, Yip PK. Intracranial dural arteriovenous fistulas with or without cerebral sinus thrombosis: Analysis of 69 patients. *J Neurol Neurosurg Psychiatry* 2004;75:1639-41.
12. Sakaki T, Morimoto T, Nakase H, Kakizaki T, Nagata K. Dural arteriovenous fistula of the posterior fossa developing after surgical occlusion of the sigmoid sinus. Report of five cases. *J Neurosurg* 1996;84:113-8.
13. Convers P, Michel D, Brunon J, Sindou M. Dural arteriovenous fistulas of the posterior cerebral fossa and thrombosis of the lateral sinus. Discussion of their relations and treatment apropos of 2 cases. *Neurochirurgie* 1986;32:495-500.
14. Nabors MW, Azzam CJ, Albanna FJ, Gulya AJ, Davis DO, Kobrine AI, *et al.* Delayed postoperative dural arteriovenous malformations. Report of two cases. *J Neurosurg* 1987;66:768-72.
15. Sasaki T, Hoya K, Kinone K, Kirino T. Postsurgical development of dural arteriovenous malformations after transpetrosal and transtentorial operations: Case report. *Neurosurgery* 1995;37:820-4.
16. Uranishi R, Nakase H, Sakaki T. Expression of angiogenic growth factors in dural arteriovenous fistula. *J Neurosurg* 1999;91:781-6.
17. Terada T, Higashida RT, Halbach VV, Dowd CF, Tsuura M, Komai N, *et al.* Development of acquired arteriovenous fistulas in rats due to venous hypertension. *J Neurosurg* 1994;80:884-9.
18. Shin Y, Nakase H, Nakamura M, Shimada K, Konishi N, Sakaki T, *et al.* Expression of angiogenic growth factor in the rat DAVF model. *Neurol Res* 2007;29:727-33.
19. Chen L, Mao Y, Zhou LF. Local chronic hypoperfusion secondary to sinus high pressure seems to be mainly responsible for the formation of intracranial dural arteriovenous fistula. *Neurosurgery* 2009;64:973-83.
20. Jean WC, Felbaum DR, Stemer AB, Hoa M, Kim HJ. Venous sinus compromise after pre-sigmoid, transpetrosal approach for skull base tumors: A study on the asymptomatic incidence and report of a rare dural arteriovenous fistula as symptomatic manifestation. *J Clin Neurosci* 2017;39:114-7.
21. Moore J, Thomas P, Cousins V, Rosenfeld JV. Diagnosis and management of dural sinus thrombosis following resection of cerebellopontine angle tumors. *Neurol Surg B* 2014;75:402-8.
22. Kim MS, Han DH, Kwon OK, Oh CW, Han MH. Clinical characteristics of dural arteriovenous fistula. *J Clin Neurosci* 2001;9:147-55.
23. Cognard C, Januel AC, Silva NA Jr., Tall P. Endovascular treatment of intracranial dural arteriovenous fistulas with cortical venous drainage: New management using onyx. *AJNR Am J Neuroradiol* 2008;29:235-41.
24. Panagiotopoulos V, Möller-Hartmann W, Asgari S, Sandalcioglu IE, Forsting M, Wanke I, *et al.* Onyx embolization as a first line treatment for intracranial dural arteriovenous fistulas with cortical venous reflux. *Rofo* 2009;181:129-38.
25. Saraf R, Shrivastava M, Siddhartha W, Limaye U. Evolution of endovascular management of intracranial dural arteriovenous fistulas: Single center experience. *Neurol India* 2010;58:62-8.
26. Stiefel MF, Albuquerque FC, Park MS, Dashti SR, McDougall CG. Endovascular treatment of intracranial dural arteriovenous fistulae using onyx: A case series. *Neurosurgery* 2009;65:132-9.
27. Jankowitz BT, Vora N, Jovin T, Horowitz M. Ear necrosis resulting from the endovascular onyx-18 embolization of a dural arteriovenous fistula fed by the posterior auricular artery. *J Neuroimaging* 2009;19:259-62.
28. Lv X, Jiang C, Zhang J, Li Y, Wu Z. Complications related to percutaneous transarterial embolization of intracranial dural arteriovenous fistulas in 40 patients. *AJNR Am J Neuroradiol* 2009;30:462-8.
29. Papalambros E, Sigala F, Georgopoulos S, Panou N, Kavatzas N, Agapitos M, *et al.* Vascular endothelial growth factor and matrix metalloproteinase 9 expression in human carotid atherosclerotic plaques: Relationship with plaque destabilization via neovascularization. *Cerebrovasc Dis* 2004;18:160-5.
30. Rashad S, Niizuma K, Sato-Maeda M, Fujimura M, Mansour A, Endo H, *et al.* Early BBB breakdown and subacute inflammasome activation and pyroptosis as a result of cerebral venous thrombosis. *Brain Res* 2018;1699:54-68.