

# Comparative Analysis of Long-Term Outcome of Anterior Reconstruction in Thoracic Tuberculosis by Direct Anterior Approach versus Posterior Approach

## Abstract

**Study Design:** Retrospective study. **Aim:** To retrospectively evaluate and compare the long-term outcome of anterior vertebral body reconstruction in tuberculosis (TB) of the dorsal spine by direct anterior-versus-posterior approach. **Materials and Methods:** A total of 127 patients operated by posterior approach, 118 by anterior for TB-thoracic spine with at least 1-year follow-up were included and retrospectively analyzed. Patients were assessed clinically, radiologically and data regarding age, sex, levels involved, surgical approach, operative time, blood loss, neurological recovery using Frankel grade, pre- and post-operative kyphosis, % correction of kyphosis, time for fusion, fusion grading using Bridwell criteria, % loss of correction, mobilization time and complications if any were collected, analyzed, compared in anterior-v/s-posterior approaches. **Results:** The mean age in anterior-approach was 36.03 and 39.83 years in posterior. Mean operative time in anterior-approach was 6.11 and 5 h in posterior. Mean blood loss of 1.6 L in anterior approach and 1.11 L in posterior. Mean preoperative kyphosis angle in posterior-approach was 34.803° and 11.286° ( $P < 0.001$ ) at 3 months postopandtotal correction of 67.216%. Mean preoperative kyphosis angle in anterior-approach was 41.154° and 9.498° at 3 months postopandtotal correction of 77.467% ( $P < 0.001$ ). Mean loss of correction at 1 year was 4.186° in posterior-approach and 6.184° in anterior. The mean time for fusion was 4.69 months in anterior-approach while 6.34 months in posterior as per Bridwell criteria. Meantime for mobilization in posterior-approach was 1.18 and 2.51 weeks in anterior. Significant improvement in neurology was seen in patients operated by either approach, slightly better in anterior. Complications were more in posterior-approach. **Conclusions:** Anterior-approach allows for thorough debridement, neural decompression, better anterior column reconstruction, and deformity correction under direct vision than posterior. Direct cord visualization while correcting kyphosis reduces the chances of neurological complications significantly. Both approaches have unique advantages and limitations. Though the posterior approach is easy to master, results shown by the anterior cannot be overseen. To conclude, better functional outcome and significantly better kyphosis correction are seen with anterior-approach, which are strong pointers favoring it.

**Keywords:** Anterior column reconstruction, bridwell criteria, frankel grade, kyphosis, thoracic spine, tuberculosis

## Introduction

First described by Sir Percival Pott, Tuberculosis (TB) is an age-old problem affecting millions and millions worldwide. Developing countries are affected the most. TB in the past was considered to be a dead-end for the patient but with the advent of anti-tubercular chemotherapy and surgical advancements, millions of lives were saved. The thoracic spine is the most common site affected. Affects more commonly the anterior part of the

vertebra and causes collapse leading to kyphotic deformity and neural compression. The goals of surgery in Pott's spine are adequate debridement and decompression, maintenance and reinforcement of stability, prevention, and correction of deformity if any.<sup>[1-5]</sup> The selection of whether anterior or the posterior approach for surgical treatment of thoracolumbar TB is still a matter of debate. Anterior approach was popularized by Hodgson in 1960. Throughout the past anterior-approach has always been favored

**Sudhir K  
Srivastava,  
Manojkumar  
Gaddikeri,  
Aditya Raj,  
Sunil Bhosle,  
Atif Naseem,  
Ankit Amin,  
Harsh Agrawal**

*Department of Orthopaedics,  
Seth GS Medical College and  
KEM Hospital, Parel, Mumbai,  
Maharashtra, India*

**Address for correspondence:**  
Dr. Manojkumar Gaddikeri,  
Department of Orthopaedics,  
Seth GS Medical College  
and KEM Hospital, Parel,  
Mumbai, Maharashtra, India.  
E-mail: mmano394@gmail.com

### Access this article online

**Website:** www.asianjns.org

**DOI:** 10.4103/ajns.AJNS\_519\_20

### Quick Response Code:



This is an open access journal, and articles are distributed under the terms of the Creative Commons Attribution-NonCommercial-ShareAlike 4.0 License, which allows others to remix, tweak, and build upon the work non-commercially, as long as appropriate credit is given and the new creations are licensed under the identical terms.

For reprints contact: WKHLRPMedknow\_reprints@wolterskluwer.com

**How to cite this article:** Srivastava SK, Gaddikeri M, Raj A, Bhosle S, Naseem A, Amin A, *et al.* Comparative analysis of long-term outcome of anterior reconstruction in thoracic tuberculosis by direct anterior approach versus posterior approach. Asian J Neurosurg 2021;16:745-51.

**Submitted:** 29-Nov-2020

**Revised:** 06-May-2021

**Accepted:** 12-Jun-2021

**Published:** 18-Dec-2021

because of involvement of the anterior part of the vertebra being more common and anterior-approach allows for thorough debridement of disease and decompression of cord. Reconstruction of the vertebral body by anterior approach looks far more promising and easy. But with time posterior-approach has gained more attention because of the complexity and morbidity associated with anterior-approach. Anterior reconstruction by posterior approach is now favored because of familiarity with the approach and ease of doing surgery. The anterior and posterior approach used for reconstruction have their own pros and cons. But are the results of reconstruction the same in both these approaches?? There are various studies showing variable results.<sup>[6-9]</sup> The above study was conducted to see and compare the long-term outcome of reconstruction by direct anterior versus posterior approach using clinical and radiological methods and conclude so that it becomes a standard of care in the management of TB.

**Aims and objectives**

To retrospectively evaluate and compare the long-term outcome of anterior reconstruction of the vertebral body in TB of the dorsal spine by direct anterior versus posterolateral approach.

**Materials and Methods**

The above study was conducted over 245 patients of confirmed cases of TB of the thoracic spine who met the criteria for anterior vertebral body reconstruction and were operated by either direct anterior transthoracic approach or posterior approach. Patients are managed in our institute by the Middle path regimen of Tuli.<sup>[10]</sup> Patients with Frankel grade A and B are considered for immediate surgery whereas Frankel grade C, D, and E are put on bed rest and anti-TB chemotherapy. If no improvement is seen in 3–6 weeks then they are considered for surgical intervention. Of them, 118 patients were operated by anterior approach and 127 patients by posterior approach. Comparison was done between the two approaches using various factors like surgical time, blood loss, length of hospital stay, neurological recovery, correction of kyphosis, maintenance of correction, time for fusion, grading of fusion using Bridwell’s grade and complications if any. All the patients were assessed clinically and their neurology was recorded using the Frankel grading system [Figure 1] preoperatively and were serially assessed at immediate

Frankel Grade	Definition
Grade A	Absent motor and sensory function
Grade B	Absent motor function; sensation present
Grade C	Motor function present but not useful (2/5 or 3/5 power); sensation present
Grade D	Motor function present and useful (4/5 power); sensation present
Grade E	Normal motor and sensory function

Figure 1: Frankel Grading of neurology

postoperative, 1, 3, 6 months, and at 1 year. All the patients were assessed radiologically using X-ray, Magnetic Resonance Imaging, and computed tomography (CT) scan which were taken preoperatively and X-rays were repeated immediately postoperative, at 1, 3, 6 months, and at 1 year. CT scan was done in few patients to look for fusion in whom X-rays were not helpful. Radiological parameters taken into account were the number of vertebrae involved, level of instrumentation, correction, and maintenance of kyphosis as measured by Cobb’s method [Figure 2], fusion grading as per Bridwell criteria. All patients were started on anti-tubercular therapy as per standard protocol immediately after surgery and was continued for a period as per the resistance of the organism. Patients with confirmed cases of TB of the dorsal spine with neurological deficit and vertebral body collapse with localized kyphosis were considered for surgery and anterior reconstruction was done in all of them. Patients with maintained records and with regular follow-up were selected for the study. Patients with vertebral body collapse due to causes other than TB, those with no maintained records and those lost to follow-up were excluded from the study. The above study has been conducted after attaining due consent from all patients and after approval from institutional ethics committee.

**Bridwell criteria: Anterior fusion grades**

- Grade I: Fused with remodeling and trabeculae
- Grade II: Graft intact, not fully remodeled or incorporated, though no lucencies
- Grade III: Graft intact, but definite lucency at the top or bottom of the graft
- Grade IV: Definitely not fused with resorption of the graft and with collapse.

**Surgical technique**

*Anterior approach*

Patients operated by this technique were placed in the right or left lateral decubitus position based on the position

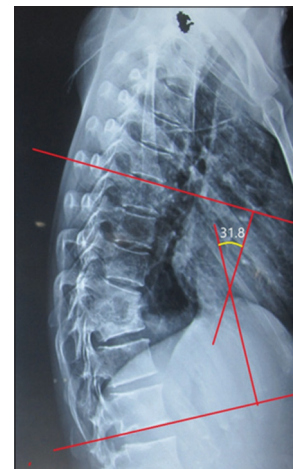

Figure 2: Cobb’s method of measurement of kyphosis

of prevertebral abscess, the preferred approach was from left by placing the patient in the right lateral position. Transthoracic intrapleural approach was made via versatile approach technique [Figure 3] of Srivastava *et al.* Thorough debridement of pus and necrotic tissue until the healthy bleeding bone was reached. Neural decompression was carried out with subtotal or complete corpectomy of the involved vertebrae. Anterior reconstruction and kyphosis correction was done using either strut graft obtained from ribs or iliac crest or titanium mesh cage filled with morselized cancellous graft.<sup>[11-13]</sup> It is supplemented by posterior instrumented stabilization by pedicular screws or Hartshill rectangle and sublaminar wires in the same stage using the same incision.

### Posterior approach

Patients were operated on by using standard midline posterior incision. The posterolateral approach included

transfacetal, transpedicular and costo-transversectomy routes as per the requirement of the case. The above approaches were used to reach the anterior aspect of the vertebrae. The transfacetal approach was considered in cases with single vertebral body collapse with Cobb's angle  $\leq 30^\circ$ . Transpedicular and costo-transversectomy approaches were considered in cases with  $\geq 2$  vertebral body collapse with severe kyphosis. The last two approaches are very helpful in the correction of rigid kyphosis. Debridement of all necrotic material was done until bleeding healthy bone was seen. Cord was decompressed, paraspinal abscess was drained and anterior vertebral body reconstruction was done using strut graft obtained by iliac crest or ribs or titanium cage filled with morselized cancellous graft. Pedicular screw and rod system was used to stabilize the spine<sup>[14-17]</sup> [Figure 4]. Indications and summary regarding

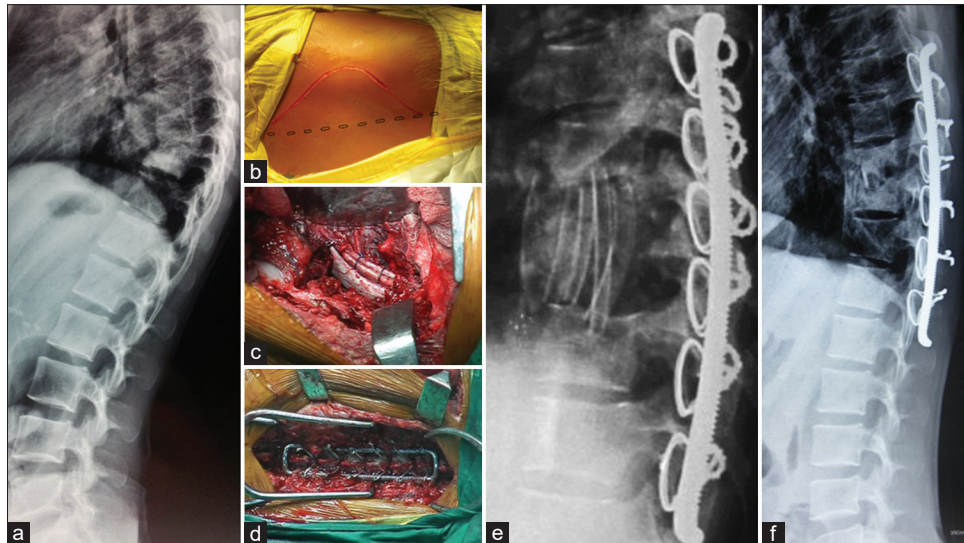


Figure 3: (a) Preoperative X-ray showing dorsal Kochæ With collapse. (b) Versatile approach technique. (c) Thorough decompression and rib graft insertion. (d) Hartshill rectangle and sublaminar wire. (e) Immediate postoperative X-ray. (f) X-ray at 3 months postoperative

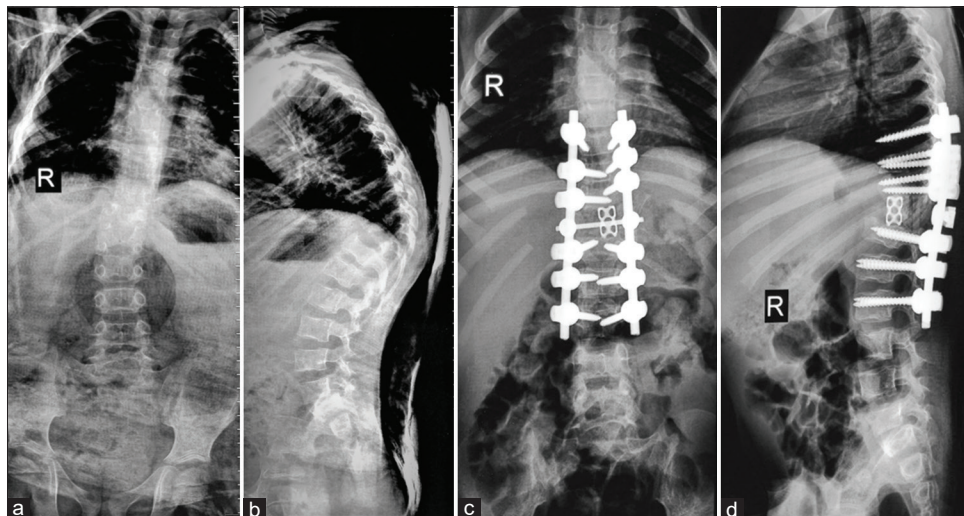


Figure 4: (a) X-ray AP view showing Tuberculosis of dorsal spine. (b) X-ray lateral view showing tuberculous of dorsal spine. (c) Postoperative X-ray at 3 months. (d) Postoperative X-ray at 3 months

the two approaches have been mentioned in the table below [Table 1].

### Correction of rigid kyphosis

It is not uncommon to encounter rigid kyphosis in cases of TB spine. There are various techniques to correct rigid kyphosis, which can be done as a single or multi-stage procedure. Steps in any kyphosis correction involve thorough soft tissue release, anterior debridement and anterior column reconstruction, cord and root decompression, instrumented stabilization and posterior column shortening.<sup>[18]</sup> All of this can be done either by anterior or posterior approaches. Various techniques of kyphosis correction mentioned in the literature include transpedicular decancellation osteotomy by Bezer *et al.*,<sup>[19]</sup> pedicle subtraction osteotomy, direct internal kyphectomy, vertebral column resection, closing-opening wedge osteotomy by Rajasekaran.<sup>[20]</sup> Our preferred method of kyphosis correction in patients operated by posterior approach was closing-opening wedge osteotomy using extra-pleural costo-transversectomy approach and transthoracic intra-pleural route<sup>[21]</sup> for patients operated by anterior approach.

### Results

Out of 245 patients, 118 were operated by anterior-approach via versatile approach technique and 127 by posterior-approach. The mean age in the anterior approach was 36.03 and 39.83 years in the posterior-approach. Anterior approach was preferred in younger patients and posterior approach preferred in older age group due to comorbidities which prevented the anterior approach. Anterior approach was preferred in patients with the higher number of vertebral body involvement. Out of 118 patients, 61% had involvement of two vertebral body, 22.9% had three or more vertebral body involvement and 16.1% had one body involvement. Out of 128 patients operated by posterior approach, 47.2% had involvement of two vertebral body, 16.5% had three or more vertebral body involvement and 36.3% had one body involvement. The mean operative time in the anterior approach was 6.11 and 5 h in the posterior approach. The mean blood loss in the anterior approach was 1.6 L which is higher compared to the posterior approach where mean blood loss is 1.1 L.

The mean preoperative kyphosis angle in the posterior approach was 34.803° and the mean postoperative kyphosis

angle was 11.286° at 3 months. The correction achieved was 67.216% which is statistically significant ( $P < 0.001$ ). However in subsequent follow-up it was noted that there was mean loss of 4.186° of correction when compared with kyphosis angle at 1 year. Fusion was graded as per Bridwell criteria and time for fusion was calculated only when fusion was noted to be of Grade I. Mean time taken for fusion was 6.34 months with values ranging from 5 to 9 months.

The mean preoperative kyphosis angle in the anterior approach was 41.154° and mean postoperative kyphosis angle at 3 months was 9.498° with a correction of 77.467% which was statistically significant ( $P < 0.001$ ). In subsequent follow-ups, the loss of correction noted was 6.184° at 1 year. The meantime taken for fusion was 4.69 months with values ranging from 3 to 6 months.

The mean time taken for mobilization in the posterior approach was 1.18 weeks which is usually done after drain removal on day 3 postoperative as per our protocol, whereas in the anterior approach the patients are mobilized after a mean duration of 2.51 weeks [Table 2].

Neurology was graded using the Frankel grading system. Among 127 patients operated by posterior approach, there were 8 patients with Frankel-A, 34 with Frankel-B, 57 with Frankel-C, 27 with Frankel-D, and 1 patient with Frankel-E. Postoperatively the neurology improved in most of the patients and by the end of 1 year there were 4 with Frankel-A, 10 with Frankel-B, 16 with Frankel-C, 30 with Frankel-D, and 67 patients with Frankel-E. Significant improvement in neurology was noticed. Unfortunately, there were 7 patients in whom worsening of neurology was seen postoperative which slightly improved by the end of 1 year.

Among 118 patients operated by anterior approach, there were 28 patients with Frankel-A, 27 with Frankel-B, 39 with Frankel-C, 14 with Frankel-D, and 10 with Frankel-E. By the end of 1 year postoperative there were 7 patients with Frankel-A, 8 with Frankel-B, 6 with Frankel-C, 42 with Frankel-D, and 55 with Frankel-E. There was a significant improvement in neurology noticed by the end of 1 year. There was worsening of neurology in 3 patients which occurred postoperative and gradual improvement in neurology was noticed by the end of 1 year.

**Table 1: Anterior Vs Posterior Approach**

Anterior approach	Posterior approach
Indications	
Young patients	Older patients
≥2 vertebral bodies involved	<2 vertebral bodies involved
Absence of co-morbidities	Co-morbidities
Surgical technique	
Versatile approach technique	Posterolateral approach - Transfacetal/transpedicular/cost-transversectomy
Cage, rib graft±iliac crest	Cage, iliac crest±rib graft
Hartshill rectangle with sublaminar wire for fixation	Pedicular screw system for fixation

**Table 2: Results**

Mean values	Anterior approach	Posterior approach	Results
Age (years)	36.03	39.83	
Operative time (h)	6.11	5	
Preoperative kyphosis (°)	41.15	34.8	
Postoperative kyphosis (°)	9.5	11.286	<i>P</i> <0.05
<i>P</i>	<0.001	<0.001	
Percentage correction (%)	77.46	67.2	<i>P</i> <0.05
Time to fusion (months)	4.69	6.34	<i>P</i> <0.01
Loss of correction (°)	6.184	4.186	
Time to mobilization (weeks)	2.51	1.18	
Complications (patients)	17	35	

Out of 127 patients operated by posterior approach 35 patients had one or the other complications. Of 35 patients 11 had dural-tear, pseudoarthrosis, and implant failure was seen in 10 patients, 3 patients got operative site infection, 7 had suture complications, 4 had neurological deterioration with no subsequent improvement. Out of 118 patients operated by anterior approach 17 had complications. Of 17 patients 7 patients had suture site complications, 3 had pneumothorax, 2 had dural-tear, 3 had neurological deterioration, 1 had implant failure and 1 had graft slippage.

## Discussion

TB of the spine has been a worldwide problem for ages and lot of research work has been done and continues to be done. There are some groundbreaking research articles which changed the course of management. After Oga *et al.*<sup>[22]</sup> in their study proved the safety of implants in regions with active TB, the treatment of TB of spine has drastically improved. Anterior approach was popularised by Hodgson in 1960<sup>[23]</sup> and since then it was commonly used in the anterior reconstruction of the vertebral body in TB and fractured spine. Hodgson and Stock advocated anterior arthrodesis as the treatment of choice for TB of the spine. They also advocated posterior instrumentation to correct unfixed kyphus with the prior anterior release.<sup>[23]</sup> Direct approach to the pathology and the ability to thoroughly debride the diseased vertebra and place a large strut graft made the approach obviously favorably. Since transthoracic approach was hard to master on and due to the slightly higher risk involved, anterior approach started losing its significance. Posterior approach via trans-facet, trans-pedicular or costo-transversectomy slowly started gaining popularity and the results obtained were comparable to the anterior approach. Rajasekaran and Soundarapandian<sup>[24]</sup> suggested a strong correlation between the initial loss of the vertebral body and the final gibbus. They suggested the formula  $Y = a + bx$  which on calculation suggests that a loss of every whole vertebra,  $30^\circ \pm 3.58^\circ$  of gibbus deformity occurred.

Louw<sup>[25]</sup> advocated the “Kalafong procedure” for the treatment of spinal TB with neurological deficit. Which

consists of anterior debridement, cord decompression, and grafting followed by single or two-stage posterior osteotomies and instrumentation. They were able to achieve good results with this.

The mean age among the anterior group is 36 years as compared to 39.83 years in the posterior group as the anterior approach is slightly more morbid than the posterior approach and not preferred in the older age group with comorbidities which preclude its use. The mean blood loss in the anterior approach was 1.6 L as compared to 1.1 L in the posterior approach. The anterior approach allows for thorough debridement and since the area is highly vascular more blood loss was expected. There were no complications related to blood loss during surgery. Laheri *et al.*<sup>[26]</sup> in their study showed a mean operative blood loss of 850 ml (range 2000 ± 400 ml) in postero-lateral approach. Jain *et al.*<sup>[27]</sup> have shown a mean blood loss of 1170 ml via antero-lateral approach in their study.

Correction of kyphosis via anterior approach in our study was 77.467% as compared to 67.216% via posterior approach which turned out to be statistically significant (*P* < 0.001). This shows that anterior approach allows for better correction of kyphosis which is very essential to maintain spinal balance and for restoration of anterior weight-bearing column. Louw<sup>[25]</sup> in his study has shown an improvement in kyphosis angle from  $56^\circ$  to  $27^\circ$  via anterior approach. Yilmaz *et al.*<sup>[28]</sup> in their study showed a correction of 64% in kyphosis when operated via anterior approach. There are very few studies which actually compare correction of kyphosis by anterior and posterior approach. Laheri *et al.*<sup>[26]</sup> in their study showed a correction of 62.5% when operated through postero-lateral approach. Jain *et al.*<sup>[27]</sup> in their study have shown correction from  $49.08^\circ$  to  $25^\circ$  when operated via anterolateral approach.

The mean duration for fusion was 4–9 months. Mean time for fusion in the anterior approach group was 4.69 months as compared to posterior approach which was 6.34 months which is statistically significant (*P* < 0.01). The anterior approach group showed early fusion compared to the posterior group. Those operated by anterior approach had 100% fusion rate with few graft-related complications

like graft slippage in 1 patient and implant failure in 1 patient. Those operated by posterior approach showed fusion rate of 93.7% with pseudoarthrosis in 8 patients and implant failure in 10 patients who were re-operated and subsequently fusion was seen. Ozdemir *et al.*<sup>[29]</sup> achieved a fusion rate of 96% via the anterior approach in their study. Ma *et al.*<sup>[30]</sup> in their study showed a fusion rate of 92.5% and 91% in anterior and posterior approach respectively. Laheri *et al.*<sup>[26]</sup> had shown a fusion rate of 100% in the posterior approach. Kemp *et al.*<sup>[31]</sup> reported 94.5% fusion rate of iliac crest grafting. The anterior approach allows for thorough debridement of necrotic tissue and use of large iliac crest and rib strut grafts which ensure high fusion rates. Debridement in posterior approach is limited by the anatomy and limited length of strut grafts can be used. Time to fusion depends on multiple factors starting from age of the patient to the technique of fusion.

The mean loss of correction in the posterior approach was 4.186° and in the anterior approach was 6.184° at 1-year postoperative. There is a higher loss of correction in the anterior approach. Laheri *et al.*<sup>[26]</sup> had a loss of 3.2° of correction in the posterior approach and Jain *et al.*<sup>[27]</sup> had a loss of 2.5° of correction in patients operated by anterior approach. Yilmaz *et al.*<sup>[28]</sup> had a loss of 3° of correction at 1 year. Ozdemir *et al.*<sup>[29]</sup> has showed a correction loss of 3° in the anterior approach. There are various studies showing results ranging from no loss of correction to loss of up to 30% of total correction achieved. It was noted in our study that the time taken to fusion and loss of correction are directly proportional. The longer the time for fusion, larger is the loss of correction.

Neurology was graded using the Frankel grading system. Among 127 patients operated by posterior approach, there were 8 patients with Frankel-A, 34 with Frankel-B, 57 with Frankel-C, 27 with Frankel-D and 1 with Frankel-E. Postoperatively, the neurology improved in most of the patients and by the end of 1 year, there were 4 with Frankel-A, 10 with Frankel-B, 16 with Frankel-C, 30 with Frankel-D, and 67 patients with Frankel-E. Significant improvement in neurology was noticed. Unfortunately, there were 7 patients in whom worsening of neurology was seen postoperative which slightly improved by the end of 1 year.

Among 118 patients operated by anterior approach, there were 28 patients with Frankel-A, 27 with Frankel-B, 39 with Frankel-C, 14 with Frankel-D and 10 with Frankel-E. By the end of 1-year postoperative there were 7 patients with Frankel-A, 8 with Frankel-B, 6 with Frankel-C, 42 with Frankel-D and 55 with Frankel-E. There was a significant improvement in neurology noticed by the end of 1 year. There was worsening of neurology in 3 patients which occurred postoperative and gradual improvement in neurology was noticed by the end of 1 year. The neurological improvement was slightly better in patients operated by the anterior approach. Laheri *et al.*<sup>[26]</sup> in their

study had a 91.3% neurological recovery by the end of 15 months with worsening of neurology in 4.3%. Similar results were seen by Christodoulou *et al.*<sup>[28]</sup> in their study of anterior stabilization in TB spine. Garg *et al.*<sup>[32]</sup> in their study had results showing almost the same neurological improvement in anterior and posterior approaches.

Mobilization of patients was done as per our institutional protocol. Patients were mobilized after drain removal and after obtaining post-X-ray. Patients operated by posterior approach were mobilized after a mean duration of 1.18 weeks and those operated by anterior approach after 2.51 weeks. All patients were mobilized using suitable brace.<sup>[33]</sup>

Patients operated by posterior approach had a slightly higher rate of complications of some type as compared to anterior approach. Out of 127 patients operated by posterior approach 35 had one or the other complications. Of 35 patients, 11 had dural-tear, pseudoarthrosis and implant failure was seen in 10 patients, 3 patients got operative site infection, 7 patients had suture complications, 4 patients had neurological deterioration with no subsequent improvement. Out of 118 patients operated by anterior approach, 17 had complications. Of 17 patients, 7 patients had suture site complications, 3 had pneumothorax, 2 had dural tear, 3 had neurological deterioration, 1 had implant failure and 1 had graft slippage. The incidence of complications varies in different studies and is not comparable.

Single-stage anterior reconstruction and posterior stabilization via anterior approach allows reduction of longstanding rigid kyphosis. An important feature of the reduction of kyphosis is the restoration of normal spinal balance. The most feared complication of spinal cord damage is avoided by meticulous attention to the total release of all anterior and lateral adhesions allowing the spinal cord to move forward unhindered during reduction of kyphosis. Segmental instrumentation is preferred as it provides a very effective three-point fixation and immediate stability. Posterior instrumentation also helps to maintain correction of kyphosis till fusion is solid.

## Conclusions

Decompression and deformity correction are the only answer to prevent the progression of neurological deficit, kyphosis, and late-onset paraplegia in these complex cases. Single-stage anterior reconstruction and posterior stabilization via anterior approach allow for thorough debridement, neural decompression, and much better anterior column reconstruction and deformity correction under direct vision than posterior approach. Direct visualization of the cord while correcting kyphosis reduces the chances of neurological complications significantly. Both approaches have their own unique advantages and limitations. The age-old saying of increased morbidity and poor results with the anterior approach have been proven wrong in this study. Though the posterior approach is

easy to master, the results shown by the anterior approach cannot be overseen. We would like to conclude that better functional outcomes and significantly better kyphosis correction by the anterior approach are strong pointers favoring the anterior approach.

### Financial support and sponsorship

Nil.

### Conflicts of interest

There are no conflicts of interest.

### References

- Upadhyay SS, Sell P, Saji MJ, Sell B, Hsu LC. Surgical management of spinal tuberculosis in adults. Hong Kong operation compared with debridement surgery for short and long term outcome of deformity. *Clin Orthop Relat Res* 1994;303:173-82.
- Mehta JS, Bhojraj SY. Tuberculosis of the thoracic spine. A classification based on the selection of surgical strategies. *J Bone Joint Surg Br* 2001;83:859-63.
- Kandwal P, Vijayaraghavan G, Jayaswal A. Management of tuberculous infection of the spine. *Asian Spine J* 2016;10:792-800.
- Nene A, Bhojraj S. Results of nonsurgical treatment of thoracic spinal tuberculosis in adults. *Spine J* 2005;5:79-84.
- Pola E, Rossi B, Nasto LA, Colangelo D, Logroscino CA. Surgical treatment of tuberculous spondylodiscitis. *Eur Rev Med Pharmacol Sci* 2012;16 Suppl 2:79-85.
- Cui X, Li LT, Ma YZ. Anterior and posterior instrumentation with different debridement and grafting procedures for multi-level contiguous thoracic spinal tuberculosis. *Orthop Surg* 2016;8:454-61.
- Bian Z, Gui Y, Feng F, Shen H, Lao L. Comparison of anterior, posterior, and anterior combined with posterior surgical treatment of thoracic and lumbar spinal tuberculosis: A systematic review. *J Int Med Res* 2020;48:300060519830827.p 1–21.
- Yang P, Zang Q, Kang J, Li H, He X. Comparison of clinical efficacy and safety among three surgical approaches for the treatment of spinal tuberculosis: A meta-analysis. *Eur Spine J* 2016;25:3862-74.
- Upadhyay SS, Sell P, Saji MJ, Sell B, Yau AC, Leong JC. 17-year prospective study of surgical management of spinal tuberculosis in children. Hong Kong operation compared with debridement surgery for short- and long-term outcome of deformity. *Spine (Phila Pa 1976)* 1993;18:1704-11.
- Tuli SM. Tuberculosis of the spine: A historical review. *Clin Orthop Relat Res* 2007;460:29-38.
- Christodoulou AG, Givissis P, Karataglis D, Symeonidis PD, Pournaras J. Treatment of tuberculous spondylitis with anterior stabilization and titanium cage. *Clin Orthop Relat Res* 2006;444:60-5.
- Benli IT, Kaya A, Acaroğlu E. Anterior instrumentation in tuberculous spondylitis: Is it effective and safe? *Clin Orthop Relat Res* 2007;460:108-16.
- Lim JK, Kim SM, Jo DJ, Lee TO. Anterior interbody grafting and instrumentation for advanced spondylodiscitis. *J Korean Neurosurg Soc* 2008;43:5-10.
- Bridwell KH, Lenke LG, McEnery KW, Baldus C, Blanke K. Anterior fresh frozen structural allografts in the thoracic and lumbar spine. Do they work if combined with posterior fusion and instrumentation in adult patients with kyphosis or anterior column defects? *Spine (Phila Pa 1976)* 1995;20:1410-8.
- Chen WJ, Wu CC, Jung CH, Chen LH, Niu CC, Lai PL. Combined anterior and posterior surgeries in the treatment of spinal tuberculous spondylitis. *Clin Orthop Relat Res* 2002;398:p 50-59
- Sahoo MM, Mahapatra SK, Sethi GC, Dash SK. Posterior-only approach surgery for fixation and decompression of thoracolumbar spinal tuberculosis: A retrospective study. *J Spinal Disord Tech* 2012;25:E217-23.
- Luo C, Wang X, Wu P, Ge L, Zhang H, Hu J. Single-stage transpedicular decompression, debridement, posterior instrumentation, and fusion for thoracic tuberculosis with kyphosis and spinal cord compression in aged individuals. *Spine J* 2016;16:154-62.
- Jain AK. Tuberculosis of the spine: A fresh look at an old disease. *J Bone Joint Surg Br* 2010;92:905-13.
- Bezer M, Kucukdurmaz F, Guven O. Transpedicular decancellation osteotomy in the treatment of posttuberculous kyphosis. *J Spinal Disord Tech* 2007;20:209-15.
- Rajasekaran S. Kyphotic deformity in spinal tuberculosis and its management. *Int Orthop* 2012;36:359-65.
- Moon MS, Woo YK, Lee KS, Ha KY, Kim SS, Sun DH. Posterior instrumentation and anterior interbody fusion for tuberculous kyphosis of dorsal and lumbar spines. *Spine (Phila Pa 1976)* 1995;20:1910-6.
- Oga M, Arizono T, Takasita M, Sugioka Y. Evaluation of the risk of instrumentation as a foreign body in spinal tuberculosis. Clinical and biologic study. *Spine (Phila Pa 1976)* 1993;18:1890-4.
- Hodgson AR, Stock FE. The Classic: Anterior spinal fusion: A preliminary communication on the radical treatment of Pott's disease and Pott's paraplegia. 1956. *Clin Orthop Relat Res* 2006;444:10-5.
- Rajasekaran S, Soundarapandian S. Progression of kyphosis in tuberculosis of the spine treated by anterior arthrodesis. *J Bone Joint Surg Am* 1989;71:1314-23.
- Louw JA. Spinal tuberculosis with neurological deficit. Treatment with anterior vascularised rib grafts, posterior osteotomies and fusion. *J Bone Joint Surg Br* 1990;72:686-93.
- Laheri VJ, Badhe NP, Dewnany GT. Single stage decompression, anterior interbody fusion and posterior instrumentation for tuberculous kyphosis of the dorso-lumbar spine. *Spinal Cord* 2001;39:429-36.
- Jain AK, Dhammi IK, Prashad B, Sinha S, Mishra P. Simultaneous anterior decompression and posterior instrumentation of the tuberculous spine using an anterolateral extrapleural approach. *J Bone Joint Surg Br* 2008;90:1477-81.
- Yilmaz C, Selek HY, Gürkan I, Erdemli B, Korkusuz Z. Anterior instrumentation for the treatment of spinal tuberculosis. *J Bone Joint Surg Am* 1999;81:1261-7.
- Ozdemir HM, Us AK, Oğün T. The role of anterior spinal instrumentation and allograft fibula for the treatment of pott disease. *Spine (Phila Pa 1976)* 2003;28:474-9.
- Ma YZ, Cui X, Li HW, Chen X, Cai XJ, Bai YB. Outcomes of anterior and posterior instrumentation under different surgical procedures for treating thoracic and lumbar spinal tuberculosis in adults. *Int Orthop* 2012;36:299-305.
- Kemp HB, Jackson JW, Jeremiah JD, Cook J. Anterior fusion of the spine for infective lesions in adults. *J Bone Joint Surg Br* 1973;55:715-34.
- Garg B, Kandwal P, Nagaraja UB, Goswami A, Jayaswal A. Anterior versus posterior procedure for surgical treatment of thoracolumbar tuberculosis: A retrospective analysis. *Indian J Orthop* 2012;46:165-70.
- Alwali AA. Spinal brace in tuberculosis of spine. *Saudi Med J* 2002;23:1483-8.