

Is only Anterior Stabilization Enough in Three-Column Injury of Subaxial Cervical Spine? – A Long-Term Retrospective Analysis of 78 Patients

Abstract

Study Design: This was a retrospective study. **Purpose:** The purpose was to retrospectively evaluate long-term outcome of anterior stabilization in three-column injury of the subaxial cervical spine. **Overview of Literature:** Literature shows varied results regarding the approach to be chosen. Most studies prefer a combined approach since biomechanically forms more stable construct. The isolated posterior approach is preferred by many as it is easy to reduce and fix three-column injuries. There are very few studies which show the isolated anterior approach to be better than the other two. **Materials and Methods:** Seventy-eight patients of three-column injury operated by anterior approach with follow-up of at least 2 years were included and retrospectively analyzed. Clinical data included age, sex, time to surgery, methods of reduction, postoperative mobilization, and neurological evaluation using the ASIA scale. Radiological data included pre- and postreduction X-ray, computed tomography, and magnetic resonance imaging (MRI). X-rays taken post-operatively at 1,3, 6 months, 1yr and 2yrs. Variables like fracture type (AO Classification), overall alignment, localized kyphosis, time for fusion and grade of fusion mass were noted. **Results:** Of 78 patients, 61 had bifacetel dislocation and 17 unifacetel. The most common site was C5-6, followed by C3-4 and C6-7. The mean patient age was 35.98 years with 60 males and 18 females. The mean time to surgery was 4.4 days. Forty dislocations were reduced by closed method and 38 by open anterior approach. Fifty-six percent of patients had traumatic disc injury on MRI. All are managed by single-level anterior cervical discectomy and fusion with iliac crest autograft for fusion. The mean preoperative lordosis: 4.44° (range -13.4° to 25°) and mean postoperative lordosis: 28.57° ($P < 0.0001$) mean loss of alignment: 2.59° by 2 years, 100% fusion with mean time – 22.82 weeks, neurological recovery in 34.6% with at least one grade improvement in ASIA scale. No neurological worsening or need for revision surgery was observed. **Conclusion:** The goal of surgery in cervical injury is bony stabilization and fusion using a least morbid approach and one with good long-term outcome. Above study concludes that only anterior stabilization after reduction of three-column injury would suffice with good long-term outcome, thereby obviating need for global fusion.

Keywords: Anterior approach, AO fracture classification, ASIA scale, subaxial cervical spine, three-column injury

Introduction

The cervical spine is functionally the most important region of the spine. The subaxial region of the cervical spine accounts for about 65% of all cervical spine injuries. Subaxial cervical spine fractures are classified according to AO classification [Figure 1]. All three-column injuries come under AO type C. Dislocations can be unifacetel or bifacetel [Figure 2]. Injuries are evaluated based on the three-column biomechanical model in each region of the spine [Figure 3] and have been the basis for our treatment rationale. Despite the high incidence of subaxial injuries, the

optimal management often is not clear from existing medical literature. The concept of spinal stability has been defined by White and Punjabi [Figure 4]. The principle is that single column injuries without neurological deficit will in general be stable without progressive deformity. Two-column injuries, which are considered unstable, are treated operatively, but some of these injuries can be treated with immobilization. Three-column injuries are highly unstable and can lead to severe neurological deficits and instability if not adequately treated. Facet dislocations and rotational injuries are the most common forms of three-column

This is an open access journal, and articles are distributed under the terms of the Creative Commons Attribution-NonCommercial-ShareAlike 4.0 License, which allows others to remix, tweak, and build upon the work non-commercially, as long as appropriate credit is given and the new creations are licensed under the identical terms.

For reprints contact: WKHLRPMedknow_reprints@wolterskluwer.com

How to cite this article: Srivastava SK, Gaddikeri M, Raj A, Bhosale S, Marathe N, Naseem A. Is only anterior stabilization enough in three-column injury of subaxial cervical spine? – A long-term retrospective analysis of 78 patients. Asian J Neurosurg 2021;16:512-7.

Submitted: 29-Nov-2020 **Revised:** 08-Jan-2021
Accepted: 10-Apr-2021 **Published:** 14-Sep-2021

**Sudhir K
Srivastava,
Manojkumar
Gaddikeri ,
Aditya Raj,
Sunil Bhosale,
Nandan Marathe,
Atif Naseem**

*Department of Orthopaedics,
Seth GS Medical College
and KEM Hospital, Mumbai,
Maharashtra, India*

Address for correspondence:
Dr. Manojkumar Gaddikeri,
Department of Orthopaedics,
Seth GS Medical College
and KEM Hospital, Mumbai,
Maharashtra, India.
E-mail: mmano394@gmail.com

Access this article online

Website: www.asianjns.org

DOI: 10.4103/ajns.AJNS_518_20

Quick Response Code:



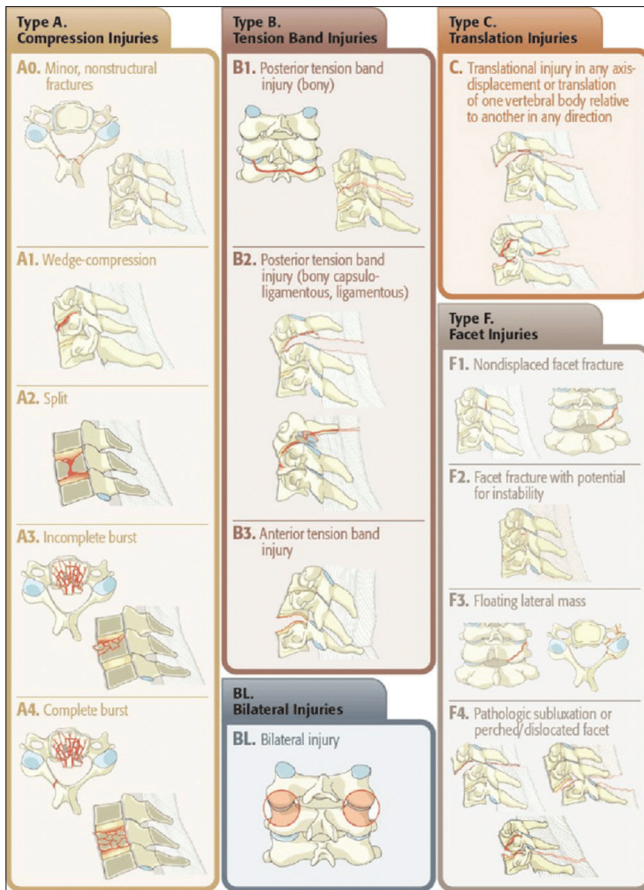


Figure 1: AO classification of subaxial cervical spine fracture

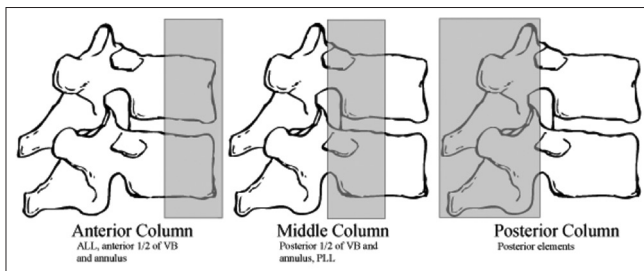


Figure 3: Three-column concept of Denis

injuries. Subaxial spine injuries can be treated by either an anterior, posterior, or combined approach. The simplest and most direct strategy is to base the approach on the area of greatest structural injury.^[1,2] Injuries that require reconstruction of the anterior column support generally are approached anteriorly and those requiring direct reduction of dislocations are approached posteriorly. There is a debate going on since ages regarding which approach to use in three-column injuries with each having its own pros and cons.^[3,4] The main objective in the treatment of such injuries is to reduce the dislocation, achieve anatomical alignment, stabilize the column, and fusion of the injured segment. Any approach that is able to achieve these goals by causing minimum morbidity is considered the best. The anterior approach is favored because of its obvious

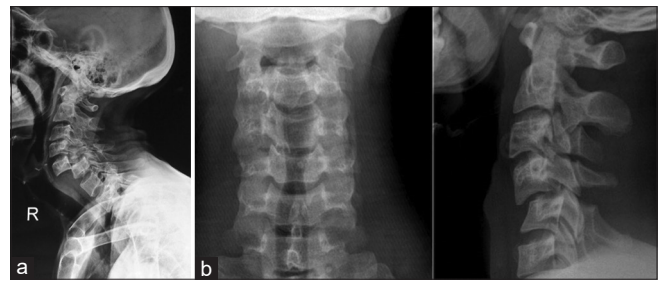


Figure 2: (a) Bifacetal dislocation. (b) Unifacetal dislocation

Diagnostic checklist elements	Points
Anterior elements destroyed or unable to function	2
Posterior elements destroyed or unable to function	2
Relative sagittal plane translation >3.5mm	2
Relative sagittal plane rotation >11 degrees	2
Positive stretch test	2
Cord damage	2
Root damage	1
Abnormal disc narrowing	1
Dangerous loads anticipated	1
TOTAL SCORE	Score of ≥ 5 points indicates instability

Figure 4: White and Panjabi instability scale

advantages of direct cord decompression and anterior column reconstruction. The posterior approach is favored by a few because of the ease of approach and reduction of the dislocation. The above study was done to evaluate the effectiveness and long-term outcome of only anterior stabilization in a three-column cervical spine injury.

Aims and objectives

The aim of this study was to retrospectively evaluate the long-term outcome of only anterior stabilization in three-column injury of the subaxial cervical spine.

Materials and Methods

A total of 105 patients of three-column injury of subaxial cervical spine (C3-C7) operated by anterior approach were chosen for the study, but only 78 patients (with follow-up of at least 2 years) were included and retrospectively analyzed as only those met our inclusion criteria. The injury at presentation was classified according to AO classification and patients were managed according to Subaxial Cervical Spine Injury Classification and scoring System (SLICS) [Figure 5]. Patients with SLIC score of 4 and above were considered for operative intervention. We retrospectively reviewed the clinicoradiological aspects from the records of these 78 patients who were operated at our institute and were followed up with serial clinical examination and radiographs taken at 1, 3, 6 months, 1 year, and 2 years to assess the progress. Clinical parameters taken into account were age, sex, time to surgery, and neurological assessment using the ASIA scale [Figure 6].

Characteristics	Points
Injury morphology	
No abnormality	0
Compression	1
Burst	2
Distraction	3
Translation	4
Integrity of the disco-ligamentous complex	
Intact	0
Indeterminate	1
Disrupted	2
Neurological status	
Intact	0
Nerve root injury	1
Complete	2
Incomplete	3
Persistent cord compression	+1

Figure 5: Subaxial cervical spine injury classification system

The radiological assessment included taking preoperative X-ray, computed tomography (CT), magnetic resonance imaging (MRI) scans, and postoperative radiographs taken at immediate postoperative, 1, 3, 6 months, 1, and 2 years. Radiological parameters calculated from these records were the level of injury, classification of injury based on AO classification, pre- and postoperative vertebral alignment, time for fusion, stability, and maintenance of correction. All the participants in the study have given their due consent and the study has been approved by the ethics committee of our institute. Patients of subaxial three-column cervical spine injury operated by anterior approach and stabilization after open or closed reduction and those with a follow-up of at least 2 years with maintained records were included in the study. Patients operated by posterior or combined approach and those lost to follow-up were excluded from the study.

All patients with cervical spine injury on presentation were thoroughly evaluated clinically and radiologically. Patients were managed according to the fixed standard protocol followed at our institute. Patients of uni- and bi-facet dislocation with ASIA-A were attempted for immediate reduction by sequential traction method [Figure 7] where patients were put on Gardner-Wells skull traction in a slight amount of neck flexion, starting with 5 kg + 2.5 kg/level of injury below C1. This was followed by the addition of 2.5 kg every 30 min until reduction was achieved, to a maximum of 50% estimated body weight for 1 h. When the anteriorly dislocated inferior facet was found to have cleared the superior facet of the vertebra below, the neck was extended and traction was reduced to 5 kg. Those with neurology other than A were temporarily immobilized and reduction attempted only after obtaining MRI as the incidence of traumatic disc injury ranges from 40% to 70% in facet dislocation and any attempted reduction without MRI can do more harm than good. Those facet dislocations

ASIA Grade	Clinical state
Grade A	Complete: no motor or sensory function is preserved in sacral segments S4-S5.
Grade B	Incomplete: sensory but not motor function is preserved below the neurological level and extends through the sacral segment S4-S5.
Grade C	Incomplete: motor function is preserved below the neurologic level; most key muscles below the neurologic level have a muscle grade <3
Grade D	Incomplete: motor function is preserved below the neurologic level; most key muscles below the neurologic level have a muscle grade >3
Grade E	Normal: motor and sensory function is normal

Figure 6: American Spine Injury Association impairment scale

with disc injury and/or prolapse on MRI were reduced intraoperatively after discectomy.

Surgical techniques

All patients who were considered for surgery were operated by the anterior approach using Smith-Robinson’s anterior approach technique.^[5-9] The reduction was attempted only after discectomy. Unreduced dislocations were reduced using techniques^[10-13] like Cloward maneuver,^[13] reverse Cloward maneuver, and modified technique using Casper pins^[10] by Khanna *et al.*^[14] Unifacetal dislocations are hard to reduce and those failed to reduce by the above methods were reduced using the technique of traction, flexion, lateral rotation, and gradual extension in sequence. Reduction is both felt and visualized while reducing. Bilateral facet dislocations that failed to get reduced by the above means are reduced using progressive traction, slight flexion, and then gradual neck extension in sequence. The reduction was assessed under fluoroscopy. Thorough cord and root decompression was done. An appropriate size iliac crest strut autograft was inserted^[15,16] and stabilized using an anterior cervical locking plate^[17,18] [Figure 8]. Wound closure over the negative suction drain, which was kept for 3 days postsurgery. The neck was immobilized in slight extension for at least 6 weeks using an appropriate brace.^[16]

Results

Out of 78 patients, 61 presented with bifacetal dislocation and 17 with unifacetal dislocation. The region most involved was C5-6 (40), followed by C4-5 (21), C3-4 (7), and C6-7 (10). C5-6 is the most common site of injury due to higher mobility at this level. The mean age of the patients was 35.98 years, of which 60 were male and 18 female.

The mean time to surgery was 4.4 days. This is due to some factors related to patient and hospital facilities which are responsible for unnecessary delay in surgery. Kanna RM *et al.*^[14] in their study had similar conditions with the mean time to surgery >72 h.

Of 78 patients, 40 dislocations were reduced by closed means and 38 by open anterior approach either due to failed closed reduction or due to traumatic disc injury with disc prolapse. Fifty-six percent of patients had traumatic disc injury as confirmed by MRI.

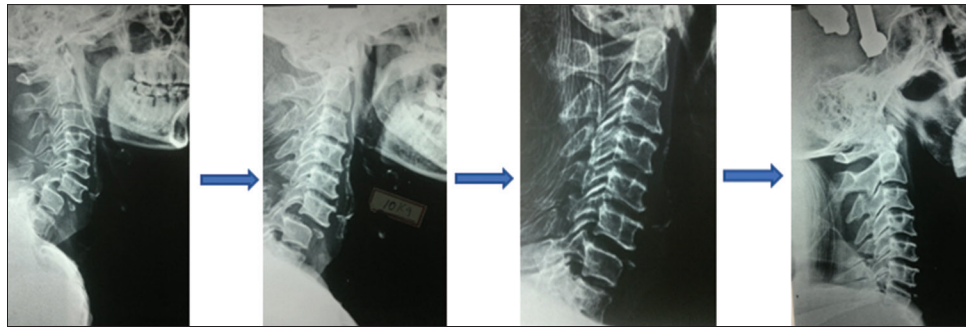


Figure 7: Closed reduction by sequential traction method

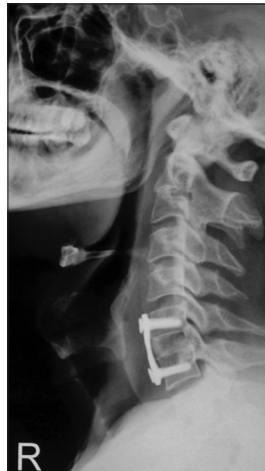

Figure 8: Anterior cervical discectomy and fusion

All patients were managed by single-level anterior cervical discectomy and fusion after closed or open reduction of facet dislocation and alignment confirmed on fluoroscopy. Iliac crest autograft was used for fusion in all patients.

Of 78.17 patients presented with ASIA-A neurology, of which 5 improved to ASIA-B and 12 showed no improvement at the end of 2 years. Twenty-eight patients presented with ASIA-B, of which 6 improved to ASIA-C and 22 showed no improvement. Fourteen patients presented with ASIA-C, of which 6 improved to ASIA-D and no improvement was seen in the rest 8. Eighteen patients presented with ASIA-D, of which 10 improved to ASIA-E and 8 showed no improvement. One patient presented with ASIA-E and remained the same postoperative. Twenty-seven patients out of 78 (34.6%) had a neurological recovery by atleast one grade. No worsening of neurology was seen in any of the patients.

Preoperative mean lordosis was 4.44° ranging between -13.4° (kyphosis) and 25° lordosis which after reduction and anterior stabilization improved to mean lordosis of 28.57° (range: 12.5° to 50°) which was statistically significant ($P < 0.0001$). The mean loss of correction was 2.59° at the end of 2 years. The mean time for fusion was 22.82 weeks. Union was seen in all patients (100%) with Bridwell grade 1 of the fusion mass. Overall alignment of the cervical spine was maintained by

the end of 2 years with no need for revision surgery. All patients were mobilized after drain removal on day 3 by an appropriate brace.

Of 78.7 patients had wound complications, of which 3 had at the neck incision site and 5 at the graft incision site. None of them needed revision surgery for the above. Dysphonia was seen in 3 patients due to recurrent laryngeal nerve injury confirmed by indirect laryngoscopy. Some amount of recovery was seen in all 3 patients at 3-month follow-up. Dysphagia was seen in 2 patients with no major injury to the esophagus which gradually recovered at a 3-month follow-up.

Discussion

Management of cervical spine injuries requires a multidisciplinary approach. Three-column injuries are highly unstable and need fixation after proper reduction. The goals of treatment in cervical fracture dislocation are reduction of dislocation and maintenance of proper alignment, cord and root decompression, bony stabilization, and fusion. Irrespective of the approach used, the above goals must be met. The anterior approach is preferred because of less morbidity, ability to thoroughly decompress the cord and nerve roots, and advantage of getting away with short-segment fusion without jeopardizing the adjacent normal motion segments. Although the posterior approach allows easy reduction of facet dislocation, it comes at the cost of the need of long-segment fusion, higher chances of neurodeficit while attempting reduction, inability to perform thorough cord and root decompression, and higher chances of infection. There has been a lot of confusion regarding the management of three-column injuries of the cervical spine. We have a standard protocol at our institute for managing such cases. We reviewed the long-term outcome in patients of three-column injuries who were managed by the anterior approach.

Our study included 78 patients of subaxial cervical spine fractures with facet dislocations. Although our study does not have the highest number of cases like Theodotou *et al.*^[19] with 398 patients, it has a good number of cases to come to a conclusion and standardize the procedure followed in treating such injuries. The

most common cause of injury in our patients was a road traffic accident which was followed by a fall from height. Out of 78 patients, 60 were male (76.9%) and 18 were female (23.1%). The mean age was 35.98 years which shows that the younger age group is the most affected. This supports the need of a treatment strategy that has a good long-term outcome.

The most common site affected in our study was C5-6 accounting for 51.28% of all cases. C5-6 and C6-7 are the most common sites affected as shown by Reindl *et al.*^[20] and Theodotou *et al.*^[19] in their study. This is due to high mobility at these sites as these are junctional areas. Bifacetal dislocations were more common than unifacetal dislocation. All of our patients were advised MRI and CT scan preoperatively and 56% had traumatic disc injury diagnosed on MRI. The incidence of traumatic disc herniation ranged from 5% to >80%, with 71% incidence in a study by Gao *et al.*,^[21] 30% incidence by Kanna *et al.*,^[14] and 42% incidence by Rizzolo *et al.*^[11] Attempted reduction in patients with traumatic disc injury can lead to herniation of disc and cord injury leading to neurological deterioration.

Of 78 patients, 40 dislocations were reduced by closed methods and 38 by the open method as per techniques shown by Keynan *et al.*^[22] in their study. Open methods were carried out either due to failed closed reduction or due to traumatic disc injury diagnosed on prereluction MRI. Among those reduced by closed means, 80% were bifacetal and 20% unifacetal dislocations. No neurological worsening was seen in any of them. The mean time to surgery was 4.4 days (range: 2–7 days). Most of these patients have polytrauma and stabilization before any surgery is of paramount importance. Time to surgery has a definite advantage in neurological recovery in patients with incomplete cord injury as shown by Kanna *et al.*^[14] where time to surgery was 1–3 days with good amount of postoperative recovery in patients with incomplete cord injury.

Preoperative mean lordosis was 4.44° (range: –13.4° kyphosis to 25° lordosis) which after reduction and anterior stabilization improved to mean lordosis of 28.57° (range: 12.5°–50°) which was statistically significant ($P < 0.0001$). Gao *et al.*^[21] in their study showed correction of alignment from 10.6° ± 8.9° of kyphosis to 6.7° ± 8.2° of lordosis. Restoration of the anterior weight-bearing column is of utmost importance. The mean loss of correction was 2.59° at the end of 2 years. Gao *et al.*^[21] had a loss of 1.5° of correction at the end of 2 years in their study. Ren *et al.*^[23] in their study showed a loss of 13% of correction at the end of 2 years.

The fusion rate was 100% with the mean time to fusion of 22.82 weeks (range 16–28 weeks). None of the patients operated by the anterior approach needed revision surgery. Lambiris *et al.*^[7] in their study showed a mean fusion rate

of 90.5% in the anterior group and 82.6% in the posterior group. Liu *et al.*^[25] had a fusion rate of 100% in those operated by anterior approach.

Seventeen patients presented with ASIA-A neurology at the time of admission, of which 5 improved to ASIA-B and 12 showed no recovery at the end of 2 years. Twenty-eight patients presented with ASIA-B, of which 6 improved to ASIA-C and 22 showed no recovery. Fourteen patients presented with ASIA-C, of which 6 improved to ASIA-D and no improvement was seen in 8 patients. Eighteen patients presented with ASIA-D, of which 10 improved to grade E and 8 showed no change in neurology. One patient presented with grade E neurology and remained the same postoperative. Twenty-seven patients out of 78 (34.6%) had a neurological recovery by at least one grade. Root recovery was seen in most patients with partial deficit. No worsening of neurology was seen in any of the patients. The main improvement was root recovery in the above patients. Kanna *et al.*^[14] in their study of 39 patients who were operated by the anterior approach, 22 patients with incomplete deficit showed recovery. Liu *et al.*^[25] in their study showed that 36.5% of their patients had a neurological recovery of at least one grade. Reindl *et al.*^[20] in their study had a neurological recovery by one grade in many patients with one patient showing neurological worsening.

Of 78.7 patients had wound complications, of which 3 had at the neck incision site and 5 at graft incision site. None of them needed revision surgery for the above. Dysphonia was seen in 3 patients due to recurrent laryngeal nerve injury confirmed by indirect laryngoscopy. Some amount of recovery was seen in all 3 patients at 3-month follow-up. Dysphagia was seen in 2 patients with no major injury to the esophagus which gradually recovered at 3-month follow-up. No major loss of correction, implant failure, pseudoarthrosis, infection, or neurological worsening was seen in any of the patients. All patients were mobilized by day 3 postoperative with proper brace avoiding neck flexion for at least 6 weeks and the brace was continued until radiological fusion.

Conclusion

Management goals in three-column injuries are timely reduction of dislocation, maintenance of proper alignment by rigid stabilization and bony fusion, cord and root decompression. All of these to be achieved using an approach that is least morbid and one with good long-term outcomes. The above study shows that only anterior stabilization after open or closed reduction of three-column injury will suffice, thereby avoiding the need for circumferential fusion.

Financial support and sponsorship

Nil.

Conflicts of interest

There are no conflicts of interest.

References

1. Wiseman D, Bellabarba C, Mirza S. Anterior Versus Posterior Surgical Treatment for Traumatic Cervical Spine Dislocation. Vol. 14. ISSN 1041-9918: Lippincott Williams & Wilkins, Inc.;2003:174-81.
2. Ulrich C, Wörsdörfer O, Claes L, Magerl F. Comparative study of the stability of anterior and posterior cervical spine fixation procedures. *Arch Orthop Trauma Surg* 1987;106:226-31.
3. Brodke DS, Anderson PA, Newell DW, Grady MS, Chapman JR. Comparison of anterior and posterior approaches in cervical spinal cord injuries. *J Spinal Disord Tech* 2003;16:229-35.
4. Capen DA, Nelson RW, Zigler J, Waters RL, Garland DE. Surgical stabilisation of the cervical spine: A comparative analysis of anterior and posterior spine fusions. *Paraplegia* 1987;25:111-9.
5. Jin DD, Lu KW, Wang JX, Chen JT, Jiang JM. The selection of the surgical approach in the management of fracture and dislocation of lower cervical spine combined spinal cord injury. *Zhonghua Wai Ke Za Zhi* 2004;42:1303-6.
6. Del Curto D, Tamaoki MJ, Martins DE, Puertas EB, Belloti JC. Surgical approaches for cervical spine facet dislocations in adults. *Cochrane Database Syst Rev* 2014;2014:CD008129.
7. Verbiest H. Anterolateral operations for fractures and dislocations in the middle and lower parts of the cervical spine. Report of a series of forty-seven cases. *J Bone Joint Surg Am* 1969;51:1489-530.
8. Lesoin F, Cama A, Lozes G, Servato R, Kabbag K, Jomin M. The anterior approach and plates in lower cervical posttraumatic lesions. *Surg Neurol* 1984;21:581-7.
9. Aebi M, Zuber K, Marchesi D. Treatment of cervical spine injuries with anterior plating. Indications, techniques, and results. *Spine (Phila Pa 1976)* 1991;16:S38-45.
10. Caspar W, Barbier DD, Klara PM. Anterior cervical fusion and Caspar plate stabilization for cervical trauma. *Neurosurgery* 1989;25:491-502.
11. Rizzolo SJ, Piazza MR, Cotler JM, Balderston RA, Schaefer D, Flanders A. Intervertebral disc injury complicating cervical spine trauma. *Spine (Phila Pa 1976)* 1991;16:S187-9.
12. Bell GD, Bailey SI. Section II: General orthopaedics. Anterior cervical fusion for trauma. *Clin Orthop Related Res.* 1977;128:155-158.
13. Cloward RB. Treatment of acute fractures and fracture-dislocations of the cervical spine by vertebral-body fusion. A report of eleven cases. *J Neurosurg* 1961;18:201-9.
14. Kanna RM, Shetty AP, Rajasekaran S. Modified anterior-only reduction and fixation for traumatic cervical facet dislocation (AO type C injuries). *Eur Spine J* 2018;27:1447-53.
15. Lee HQ, Kow CY, Ng JS, Chan P, Ton L, Etherington G, *et al.* Correlation of anterior interbody graft choice with patient-reported outcomes in cervical spine trauma. *Global Spine J* 2019;9:735-42.
16. Schürmann K. The importance for rehabilitation of the interbody fusion and stabilization operation in fracture dislocations of the cervical spine. *Scand J Rehabil Med* 1972;4:114-22.
17. Böhler J, Gaudernak T. Anterior plate stabilization for fracture-dislocations of the lower cervical spine. *J Trauma* 1980;20:203-5.
18. Stauffer ES, Kelly EG. Fracture-dislocations of the cervical spine. Instability and recurrent deformity following treatment by anterior interbody fusion. *J Bone Joint Surg Am* 1977;59:45-8.
19. Theodotou CB, Ghobrial GM, Middleton AL, Wang MY, Levi AD. Anterior reduction and fusion of cervical facet dislocations. *Neurosurgery* 2019;84:388-95.
20. Reindl R, Ouellet J, Harvey EJ, Berry G, Arlet V. Anterior reduction for cervical spine dislocation. *Spine (Phila Pa 1976)* 2006;31:648-52.
21. Gao W, Wang B, Hao D, Zhu Z, Guo H, Li H, *et al.* Surgical treatment of lower cervical fracture-dislocation with spinal cord injuries by anterior approach: 5- to 15-year follow-up. *World Neurosurg* 2018;115:e137-45.
22. Keynan O, Dvorak M, Fisher C. Reduction techniques in cervical facet dislocations. In: *Techniques in Orthopaedics® Vol. 17.* Philadelphia: Lippincott Williams & Wilkins, Inc.; 2003. p. 336-44.
23. Ren C, Qin R, Wang P, Wang P. Comparison of anterior and posterior approaches for treatment of traumatic cervical dislocation combined with spinal cord injury: Minimum 10-year follow-up. *Sci Rep* 2020;10:10346.
24. Lambiris E, Kasimatis GB, Tyllianakis M, Zouboulis P, Panagiotopoulos E. Treatment of unstable lower cervical spine injuries by anterior instrumented fusion alone. *J Spinal Disord Tech* 2008;21:500-7.
25. Liu K, Zhang Z. Comparison of a novel anterior-only approach and the conventional posterior-anterior approach for cervical facet dislocation: A retrospective study. *Eur Spine J* 2019;28:2380-9. .