

Safety and Effectiveness of a Modified ASAP Technique during Mechanical Thrombectomy for Acute Ischemic Stroke: Initial Clinical Experience

Abstract

Objectives: For patients with acute ischemic stroke, various endovascular approaches have been reported with high recanalization rates and good clinical outcomes. However, the best technique for the first attempt at mechanical thrombectomy remains a matter of debate. In this study, we evaluated the efficacy of a modified version of a stent-retrieving into an aspiration catheter with a proximal balloon (ASAP) technique. **Materials and Methods:** Modification 1: After stent deployment, the microcatheter was not removed immediately. Modification 2: After the withdrawal of the stent retriever into an aspirator and its removal from the entire system, we focused on the drainage of fluid into a pump. The aspirator was withdrawn slowly until the fluid appeared to be draining continuously into the pump. Before the removal of the aspirator, we performed angiography through the aspirator. We carried out a retrospective analysis of 30 consecutive patients with acute ischemic stroke caused by occlusion of the anterior circulation who were treated with the modified ASAP technique at our institution. **Results:** A thrombolysis in cerebral infarction score of 2B or 3 was achieved in 29/30 patients (96.7%). The average number of passes was 1.2 ± 0.5 . The mean time from puncture to recanalization was 17.6 ± 6.84 min. Twenty-three (76.7%) patients achieved a modified Rankin Scale score of 0–2 at 3 months after the procedure. **Conclusions:** We found that the modified ASAP technique yielded fast recanalization, minimal complications, and good clinical outcomes of mechanical thrombectomy in this case series.

Keywords: Combined technique, endovascular thrombectomy, stent clot retriever

Introduction

Mechanical thrombectomy is a widely used treatment in patients with acute ischemic stroke. Recently, several companies have launched aspiration catheters and stent clot retrievers of various sizes and characteristics. The fact that many combinations of these devices and various techniques can be used,^[1-9] may generate confusion among operators. Furthermore, which technique is better suited for a quick approach using a single device or a secure recanalization using multiple devices remains a controversial issue.

We used a stent-retrieving into an aspiration catheter with proximal balloon (ASAP) technique as the first-line approach to manage patients with acute ischemic stroke caused by occlusion of the anterior circulation.^[9,10] Through an accumulation of procedures, the ASAP technique has

been improved gradually based on the launching of new devices and the gleaned new knowledge from both clinical and experimental data. Here, we report the modified ASAP technique that is used currently at our institution. And our clinical results were compared with results that had been reported using various techniques.

Materials and Methods

Patients

Patients with acute ischemic stroke were examined at admission to our institution using the National Institutes of Health Stroke Scale (NIHSS).^[11] Patients with an NIHSS score ≥ 4 were treatable by mechanical thrombectomy, and computed tomography (CT) and magnetic resonance imaging were immediately performed. Mechanical thrombectomy was performed in cases in which the presence of internal

Tomotaka Ohshima¹,
Reo Kawaaguchi²,
Naoki Matsuo²,
Shigeru Miyachi^{1,2}

¹Neuroendovascular Therapy Center, Aichi Medical University, ²Department of Neurosurgery, Aichi Medical University, Nagakute, Aichi, Japan

Address for correspondence:
Dr. Tomotaka Ohshima,
Md, Phd, 1-1 Yazakokarimata,
Nagakute, Aichi 480-1195,
Japan.
E-mail: tmtkoh@gmail.com

Access this article online

Website: www.asianjns.org

DOI: 10.4103/ajns.AJNS_503_20

Quick Response Code:



This is an open access journal, and articles are distributed under the terms of the Creative Commons Attribution-NonCommercial-ShareAlike 4.0 License, which allows others to remix, tweak, and build upon the work non-commercially, as long as appropriate credit is given and the new creations are licensed under the identical terms.

For reprints contact: WKHLRPMedknow_reprints@wolterskluwer.com

How to cite this article: Ohshima T, Kawaaguchi R, Matsuo N, Miyachi S. Safety and effectiveness of a modified ASAP technique during mechanical thrombectomy for acute ischemic stroke: Initial clinical experience. Asian J Neurosurg 2021;16:56-61.

Submitted: 23-Nov-2020 **Revised:** 23-Dec-2020

Accepted: 26-Jan-2021 **Published:** 20-Mar-2021

carotid artery (ICA) or middle cerebral artery (MCA) occlusion was confirmed by magnetic resonance angiography and intracranial hemorrhage was ruled out by CT. Patients who were treated with mechanical thrombectomy at our institution between May 2019 and April 2020 were included in the study. We performed a retrospective analysis of 30 consecutive cases with acute ischemic stroke caused by occlusion of the anterior circulation who were treated with the modified ASAP technique at our institution. Informed consent was obtained after a certified neuroendovascular physician explained the content of treatment and study to each patient or his/her family. This study was approved by the ethics review board of our hospital (Application No.: 2020-083).

The preoperative patient characteristics, including age, sex, thrombus location, Alberta stroke program early CT score with diffusion-weighted magnetic resonance imaging (ASPECTS-DWI),^[12] NIHSS score, and time from onset to puncture, as well as the postoperative thrombolysis in cerebral infarction (TICI) score,^[13] the number of passes necessary to achieve recanalization, time from puncture to recanalization, procedural complications (including embolization to the new territories and asymptomatic subarachnoid hemorrhage), and clinical outcome, were assessed. Successful recanalization was defined as TICI score of 2B or 3 and good clinical outcome was defined as a modified Rankin Scale (mRS) score of 0–2 at 3 months after the thrombectomy.

Protocol of the modified ASAP technique

All procedures were performed under local anesthesia via femoral puncture. A 9-F balloon-attached guiding catheter was advanced into the proximal ICA of the affected side using a coaxial 5-F inner catheter. After an angiographic study, a 0.027-inch microcatheter with a 0.014-inch microguidewire was advanced through a large caliber aspiration catheter (≥ 0.068 -inch) in a triaxial fashion. In cases of distal MCA occlusion, we used a 0.021-inch microcatheter. The tip of the microwire was shaped as a tiny pigtail; alternatively, a preshaped type was used.^[14-16] The advancement of the aspirator was stopped at the infra-clinoid portion of the ICA. The proximal balloon was inflated before passage through the thrombus using the microwire, to prevent distal migration of the thrombus. Simultaneous angiography through both the microcatheter and the aspirator was performed, to document the exact position of the thrombus. After the deployment of a stent retriever, the microcatheter was not removed, which was in contrast with the original method of the ASAP technique (Modification 1) [Figure 1a]. Continuous aspiration was initiated via the aspirator via connection to a mechanical pump. The aspirator was advanced up to a position just proximal of the thrombus, to accomplish contact aspiration, while the deployed stent was used as an anchor. In cases with a second division of the MCA (M2),

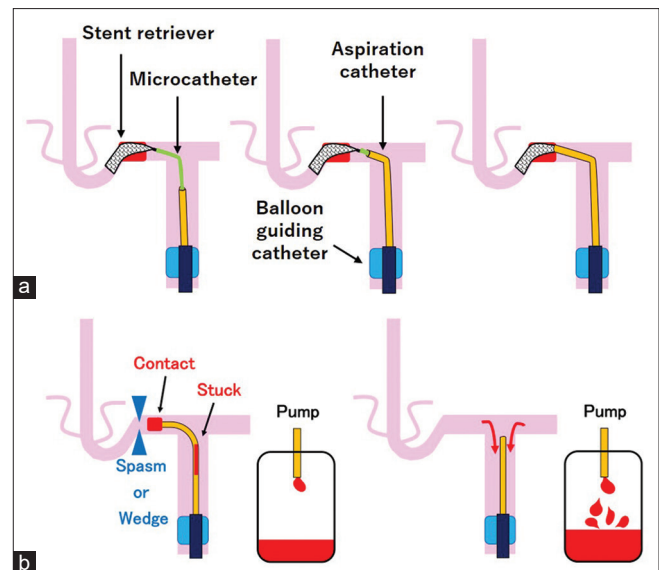


Figure 1: (a) Schematic diagram of modification 1. After stent deployment, the microcatheter is not removed from the entire system, in contrast with the original technique. The aspiration catheter is advanced together with the microcatheter as the deployed stent is used as an anchor. The tip of the aspirator is engaged at the proximal end of the clot. (b) Schematic drawing of modification 2. The draining fluid from the aspirator into the pump is usually stopped because of regional vasospasm, a wedge of the aspirator, contact with a clot, or the sticking of a clot inside the aspirator. The aspirator is slowly withdrawn until the fluid appears to continuously drain into the pump

the aspirator was kept at the first division of the MCA (M1). The stent and microcatheter were withdrawn into the aspirator and completely removed from the entire system. Subsequently, the aspirator was withdrawn until the fluid appeared to be continuously draining into the pump. This constituted Modification 2 [Figure 1b]. Rather than removing the aspirator from the guiding catheter, we performed angiography through the aspirator. If there was no residual clot, the balloon of the guiding catheter was deflated. Cone-beam CT was performed before the guiding catheter was pulled out.

Simple experimental evaluations

We evaluated the differences in the speed with which the mechanical pump (Penumbra Inc., Alameda, CA, USA) aspirated water [Figure 2A]. First, the microcatheter was positioned to deploy the stent. After the stent deployment, the microcatheter was withdrawn until the tail of the microcatheter reached the same location as the tail of the stent delivery wire. The microcatheter was then removed from the entire system, and the stent was removed from the aspiration catheter. Using the indicator attached to the mechanical pump [Figure 2B], we also evaluated the pressure at the tip of the aspirator with microcatheters of various sizes and without the microcatheter: The 0.068-inch aspiration catheter alone, the 0.0165-inch microcatheter inside the aspirator, the 0.021-inch microcatheter inside the aspirator, and 0.027-inch microcatheter inside the aspirator.

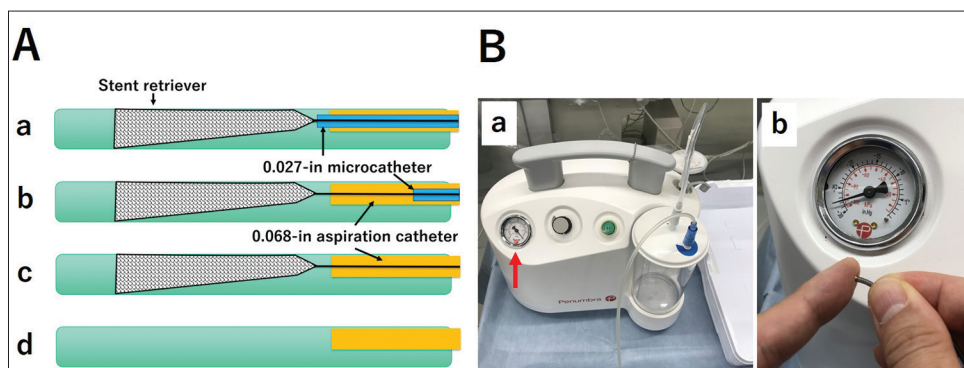


Figure 2: (A) Schematic drawing of the *in vitro* experiment. a: The position of the microcatheter to deploy the stent. b: The microcatheter is withdrawn until the tail of the microcatheter reaches the same location as the tail of the stent delivery wire. c: The microcatheter is removed from the entire system. d: The stent is removed from the aspiration catheter. (B) Photograph of the mechanical pump (Penumbra Inc., Alameda, CA, USA). a: The red arrow indicates the pressure meter. b: The pressure at the tip of the aspirator was evaluated by the presence or absence of the microcatheter

Results

A summary of the cases is provided in Table 1. The average age of the patients was 75.1 ± 10.1 (range, 43–91) years. Seventeen out of the 30 participants were male (56.7%). The mean ASPECTS-DWI was 7.3 ± 2.0 (range, 2–10). The mean NIHSS score was 14.7 ± 6.4 (range, 5–29). The mean time from stroke onset to puncture was 122.7 ± 37.8 (range, 60–210) min, except for two cases with unknown stroke onset. A TICI score of 2B or 3 was achieved in 29/30 patients (96.7%). The average number of passes was 1.2 ± 0.5 (range, 1–3). The mean time from puncture to recanalization was 17.6 ± 6.84 (range, 9–39) min. One patient (3.3%) developed minor subarachnoid hemorrhage postoperatively. Seventeen patients (56.6%) achieved an mRS score of 0–1, whereas 23 patients (76.7%) achieved an mRS score of 0–2 at 3 months after the thrombectomy.

The results of the simple experimental evaluations are illustrated in Figure 3. When the microcatheter was removed from the entire system, aspiration became dramatically faster. The pressure at the tip of the aspirator was not affected by the presence or absence of the microcatheter.

Discussion

Rationale of the modifications

Modification 1

In the original ASAP technique, the microcatheter was fully removed from the entire system after the deployment of the stent.^[9] This step was based on a simple experiment that evaluated the difference in the time required to aspirate water into the aspirator [Figure 3A]. Therefore, we considered that the removal of the microcatheter increased the flow velocity from the aspirator. However, we assumed that the contact aspiration affected the degree of pressure at the tip of the aspirator, rather than the velocity of the aspiration. We evaluated this pressure in various situations.

Table 1: Summary of the patients treated with modified aspiration catheter with a proximal balloon technique in our institution

<i>n</i>	30
Age, years (range)	75.1±10.1 (43-91)
Location	
Internal carotid artery	7 (23.3)
Carotid T	3
Proximal M1	12 (40)
Distal M1	3 (10)
M2	8 (26.7)
Tissue plasminogen activator	16 (53.3)
ASPECTS-DWI (range)	7.3±2.0 (2-10)
NIHSS score (range)	14.7±6.4 (5-29)
Time from onset to puncture, minute (range)	122.7±37.8 (60-210)*
Time from puncture to recanalization, minute (range)	17.6±6.84 (9-39)
Number of passes	
1	25 (83.3)
2	4 (13.3)
3 or more	1 (3.3)
Thrombolysis in Cerebral Infarction score	
0-2A	1 (3.3)
2B	7 (23.3)
3	22 (73.3)
Embolization to the new territory	0 (0)
Intracranial hemorrhage	1 (3.3)
Modified Rankin Scale score	
0-1	17 (56.6)
0-2	23 (76.7)
3-6	7 (23.3)

Values are number (%) or mean±standard deviation (range).

*Except one of unknown onset. M1 - First division of middle cerebral artery; M2 - Second division of middle cerebral artery; ASPECTS-DWI - Alberta Stroke Program Early CT Score with Diffusion-Weighted magnetic resonance Image; NIHSS - National Institute of Health Stroke Scale; CT - Computed tomography

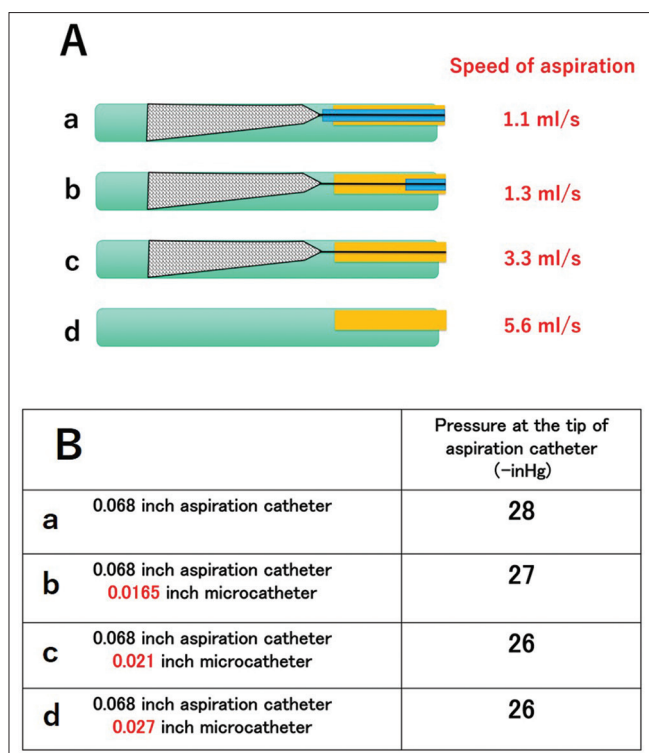


Figure 3: (A) Comparison of the speed of aspiration in various situations. a-d: The removal of the microcatheter from the entire system[®] led to a dramatic increase in the speed of aspiration. (B) Measurement of the pressure at the tip of the 0.068-inch aspiration catheter. a-d: There were no significant differences between the presence or absence of the microcatheter inside the aspirator

The results are shown in Figure 3B. The pressure at the tip of the aspirator was not affected by the presence or absence of the microcatheter. Moreover, when the microcatheter was covered with the proximal marker of the deployed stent, the stent could be retrieved easily into the aspirator. The microcatheter worked to decrease the deflections of the flexible aspirator.

Modification 2

In the original ASAP technique, just after the stent and microcatheter were completely removed from the entire system, the aspirator was also withdrawn and completely removed from the guiding catheter out of the body.^[9] We stopped the withdrawal of the aspirator until the fluid appeared to be continuously draining into the pump [Figure 1b]. In almost all cases, continuous draining was confirmed when the tip of the aspirator came back in the ICA, because of release from a wedge and/or a vasospasm. At that position, we performed angiography via the aspirator. In cases of unsuccessful recanalization or the presence of a residual clot, we thought that the second approach was able to perform quickly via the remaining aspiration catheter. We used the remaining aspirator as a distal access catheter, for quick re-access. This is one of the most advantageous aspects of the use of the modified ASAP technique compared with the continuous aspiration prior to intracranial

vascular embolectomy (CAPTIVE),^[6] stent retriever assisted vacuum-locked extraction (SAVE),^[7] and aspiration-retriever technique for stroke (ARTS)^[8] methods, in which both the stent retriever and the aspirator are retrieved as a unit.

Comparison with other methods

There is no clear consensus regarding which technique is more effective for the first-line attempt at mechanical thrombectomy. The representative techniques of mechanical thrombectomy that have been reported are summarized in Table 2. Our modified ASAP technique yielded the best results regarding the number of passes, the embolization to the new territory, the symptomatic intracranial hemorrhage, and the mRS score at 3 months after the procedure.

The simple stent-retrieving method has been widely used after a meta-analysis of five trials demonstrated its benefits.^[17] However, the simple stent-retrieving methods have some limitations, such as intracranial hemorrhage caused by the vessel shift phenomenon. Conversely, some reports have recommended a direct aspiration first pass technique (ADAPT)^[3] for the first attempt. However, Delgado Almandoz *et al.*^[4] reported that ADAPT was unsuccessful in approximately one-third of patients who required salvage. Moreover, it was often challenging to navigate the currently available large-caliber aspirators quickly into the distal cerebral arteries.

Several combination techniques using both an aspiration catheter and a stent retriever have been reported. The so-called Solumbra techniques represent a method in which there is no contact between the tip of the aspirator and the thrombus.^[4,5] Conversely, the CAPTIVE,^[6] SAVE,^[7] ARTS,^[8] and ASAP^[9] techniques are used for contact aspiration. In our modified ASAP technique, we suggest that the large caliber aspiration catheter played an important role in the highly successful recanalization rate. The deployed stent retriever works as a strong anchor during the navigation of the large-caliber aspirator. Therefore, using our technique, even the large bore aspirators could be navigated more smoothly than the ADAPT. All seven cases in whom a REACT 71 aspiration catheter (Medtronic, Irvine, CA, USA) was used in our series exhibited 1-pass recanalization with an average 12.1 ± 1.8 (range, 9–15) min from puncture to recanalization.

Limitations

The present study had significant limitations, including the small initial experience population, the retrospective and nonrandomized nature of the analysis, the absence of a control group, and the involvement of a single institution. Self-adjudicated results were also a limitation of our study. Therefore, the efficacy of the modified ASAP technique may have been overestimated. Nonetheless, regardless of the lack of statistical power, we believe that this case study will be of great interest to many physicians and patients.

Table 2: Summary of the results of the reported representative literatures

References, year	Devices (strategy)	Micro catheter aspiration SR and aspiration catheter	Contact aspiration	Number of patients	Time from puncture to recanalization (minutes)	Number of passes	Thrombolysis in cerebral infarction score 2B and 3 (%)	Embolization to the new territory (%)	Intracranial hemorrhage/ symptomatic intracranial hemorrhage (%)	Modified Rankin Scale 0-2 after 3 months (%)
ESCAPE, ^[1] 2015	SR + BGC			165	33	NR	72.4	NR	NR/3.6	53
STRATIS, ^[2] 2017	SR			984	45.6	NR	87.9	0.8	2.9/1.4	56.5
ADAPT FAST, ^[3] 2014	Asp (ADAPT)	+		98	37	NR	95	0	NR/0	40
Delgado Almandoz <i>et al.</i> , ^[4] 2016	Asp + SR (Solubra)	Remove	-	55	51	NR	84	2	47/13	31
Humphries <i>et al.</i> , ^[5] 2015	Asp + SR (Solubra)	Remove	-	105	54	NR	88	3.8	NR/4.6	44.1
McTaggart <i>et al.</i> , ^[6] 2016	Asp + SR (CAPTIVE)	Remove	+	39	14	1.7	100	5	NR	49
Maus <i>et al.</i> , ^[7] 2017	Asp + SR (SAVE)	Remove	+	32	44.5	1.2	100	0	NR/3.1	59
Massari <i>et al.</i> , ^[8] 2016	Asp + SR + BGC (ARTS)	Remove	+	42	65	2.2	97.6	2.4	2/0	65.7
Goto <i>et al.</i> , ^[9] 2018	Asp + SR + BGC (ASAP)	Remove	+	42	21.5	1.3	95.2	4.8	0/0	76.2
Present cases	Asp + SR + BGC (modified ASAP)	Not remove	+	30	17.6	1.2	96.7	0	1/0	76.7

+: Contact aspiration is needed. -: Contact aspiration is not needed. SR - Stent retriever; NR - Not reported; BGC - Balloon guiding catheter; Asp - Aspiration catheter; ADAPT - A direct aspiration first pass technique; CAPTIVE - Continuous aspiration prior to intracranial vascular embolectomy; SAVE - Stent retriever assisted vacuum-locked extraction; ARTS - Aspiration-retriever technique for stroke; ASAP - Aspiration catheter with a proximal balloon

Conclusions

The findings of this study support the hypothesis that the modified ASAP technique provides faster recanalization, fewer complications, and better clinical outcomes compared with other techniques. A further large-scale study is necessary to evaluate the efficacy of this preliminary study.

Financial support and sponsorship

Nil.

Conflicts of interest

There are no conflicts of interest.

References

- Goyal M, Demchuk AM, Menon BK, Eesa M, Rempel JL, Thornton J, *et al.* Randomized assessment of rapid endovascular treatment of ischemic stroke. *N Engl J Med* 2015;372:1019-30.
- Mueller-Kronast NH, Zaidat OO, Froehler MT, Jahan R, Aziz-Sultan MA, Klucznik RP, *et al.* Systematic evaluation of patients treated with neurothrombectomy devices for acute ischemic stroke: Primary results of the STRATIS registry. *Stroke* 2017;48:2760-8.
- Turk AS, Frei D, Fiorella D, Mocco J, Baxter B, Siddiqui A, *et al.* ADAPT FAST study: A direct aspiration first pass technique for acute stroke thrombectomy. *J Neurointerv Surg* 2014;6:260-4.
- Delgado Almandoz JE, Kayan Y, Young ML, Fease JL, Scholz JM, Milner AM, *et al.* Comparison of clinical outcomes in patients with acute ischemic stroke treated with mechanical thrombectomy using either Solubra or ADAPT techniques. *J Neurointerv Surg* 2016;8:1123-8.
- Humphries W, Hoit D, Doss VT, Eljovich L, Frei D, Loy D, *et al.* Distal aspiration with retrievable stent assisted thrombectomy for the treatment of acute ischemic stroke. *J Neurointerv Surg* 2015;7:90-4.
- McTaggart RA, Tung EL, Yaghi S, Cutting SM, Hemendinger M, Gale HI, *et al.* Continuous aspiration prior to intracranial vascular embolectomy (CAPTIVE): A technique which improves outcome. *J NeuroInterv Surg* 2016;9:1-6.
- Maus V, Behme D, Kabbasch C, Borggreffe J, Tsogkas I, Nikoubashman O, *et al.* Maximizing first-pass complete reperfusion with SAVE. *Clin Neuroradiol* 2018;28:327-38.
- Massari F, Henninger N, Lozano JD, Patel A, Kuhn AL, Howk M, *et al.* ARTS (aspiration-retriever technique for stroke): Initial clinical experience. *Interv Neuroradiol* 2016;22:325-32.
- Goto S, Ohshima T, Ishikawa K, Yamamoto T, Shimato S, Nishizawa T, *et al.* A stent-retrieving into an aspiration catheter with proximal balloon (ASAP) technique: A technique of mechanical thrombectomy. *World Neurosurg* 2018;109: e468-e475.
- Ohshima T, Niwa A, Kawaguchi R, Matsuo N, Miyachi S. Novel technique for detection of actual position of clot during endovascular clot retrieval: Assessment of microcatheter withdrawing angiography. *World Neurosurg* 2020;137:229-34.
- Lyden PD, Lu M, Levine SR, Brott TG, Broderick J, NINDS rtPA Stroke Study Group. A modified National Institutes of Health Stroke Scale for use in stroke clinical trials: Preliminary reliability and validity. *Stroke* 2001;32:1310-7.
- Hirai T, Sasaki M, Maeda M, Ida M, Katsuragawa S, Sakoh M, *et al.* Diffusion-weighted imaging in ischemic stroke: Effect of display method on observers' diagnostic performance. *Acad Radiol* 2009;16:305-12.

13. Higashida R, Furlan A, Roberts H, Tomsick T, Connors B, Barr J, *et al.* Trial design and reporting standards for intraarterial cerebral thrombolysis for acute ischemic stroke. *J Vasc Interv Radiol* 2003;14:S493-4.
14. Sato M, Ohshima T, Ishikawa K, Goto S, Yamamoto T, Izumi T, *et al.* A novel technique of safe and versatile microguidewire shaping with neuroendovascular therapy: Modified pigtail method. *J Neuroendovasc Ther* 2017;11:266-71.
15. Ohshima T, Ishikawa K, Goto S, Yamamoto T. Relationship between clot quality and microguidewire configuration during endovascular thrombectomy for acute ischemic stroke. *World Neurosurg* 2017;107:657-62.
16. Ohshima T, Kawaguchi R, Maejima R, Yukiue N, Matsuo N, Miyachi S. Initial clinical experience of using a newly designed preshaped microguidewire in acute endovascular thrombectomy. *Asian J Neurosurg* 2020;15:241-4.
17. Goyal M, Menon BK, van Zwam WH, Dippel DW, Mitchell PJ, Demchuk AM, *et al.* Endovascular thrombectomy after large-vessel ischaemic stroke: A meta-analysis of individual patient data from five randomized trials. *Lancet* 2016;387:1723-31.