

Seizure Outcome after Lesionectomy With or Without Concomitant Anteromedial Temporal Lobectomy for Low-Grade Gliomas of the Medial Temporal Lobe

Abstract

Background: Mesial temporal lobe epilepsy attributed to low-grade glioma is known for intractable seizures and choice of surgery range from lesionectomy (Lo) to lesionectomy with anteromesial temporal resection (LO + AMTR) is still debatable. We intend to analyze the seizure outcome after lesionectomy alone or with AMTR. **Subjects and Methods:** Retrospective analyses of patients operated for medial low-grade temporal lobe tumors with seizures were included in the study. Preoperative records include video-electroencephalographic, magnetic resonance imaging (epilepsy protocol), and neuropsychological evaluation for language, memory, and dominance were assessed. Two groups (Lo [Group I] and Lo + AMTR [Group II]) were assessed after surgery by the international league against epilepsy (ILAE) seizure outcome scale. **Results:** A total of 39 patients underwent Lo ($n = 20$) and Lo + AMTR ($n = 19$) with a mean age of 26.92 ± 12.96 months, and mean duration of seizures was 36.87 ± 46.76 months. A total of 23 patients had long-term intractable seizures for >1 year despite >2 drugs (Group I [$n = 10$], Group II [$n = 13$]); remaining 16 had frequent seizures of <1-year duration. In the postoperative period, on a mean follow-up of 49.72 ± 34.10 months, the ILAE outcome scale shown a significant difference ($P = 0.05$) in seizure outcome between two groups. Four (40%) patients out of 10 having refractory seizures in Group I and 8 (80%) from the Group II out of 10 patients could achieved ILAE Class 1 outcome after surgery. Histopathology analysis includes low-grade astrocytoma ($n = 29$) and in two patients there were associated CA1 neuronal loss in hippocampus, one patient had mesial temporal sclerosis from Group II attributed to its intractability in seizures. **Conclusion:** For the mesial temporal low-grade glioma presenting with seizures, the seizure outcome by lesionectomy with AMTR is superior than lesionectomy only.

Keywords: Amygdalohippocampectomy, anteromesial temporal lobe resection, epilepsy surgery, lesionectomy, temporal lobe epilepsy

Introduction

Early surgical intervention for temporal lobe epilepsy in mesial temporal sclerosis is beneficial.^[1-3] However, the benefits of the extended tailored excision in low-grade glioma located in the mesial temporal lobe remain unclear.^[4,5] The functional significance of this area and important neurovascular structures in close vicinity further limits the desired extent of excision. After subtotal excision, the seizure outcome, and overall survival of the patients are theoretically poorer. Very few studies have highlighted the seizure outcome of mesial temporal lobe tumors in context with neuro-oncological outcomes.^[5-8] The high incidence of epileptogenicity

in mesial temporal lesions is attributed to the mass effect, ischemia, neuronal degeneration, or hemosiderin accumulation due to frequent hemorrhage by tumors. Either the tumor itself is epileptogenic or the adjacent hippocampal area gets transformed to epileptic focus through kindling phenomenon (loss of neurons in hippocampal neuronal layers).^[5-8] The comparative seizure-outcome between “lesionectomy only” and “lesionectomy with anteromesial temporal lobectomy (AMTR)” for mesiotemporal lesions is still questionable. In this article, we have shared our institutional experience of seizure outcome of mesial temporal lobe

Vandan Raiyani,
Suyash Singh¹,
Jayesh Sardhara,
Anant Mehrotra,
Vinita Mani²,
Vimal K Paliwal²,
Lily Pal³,
Ashutosh Kumar,
Priyadarshi Dikshit,
Ved Prakash
Maurya,
Pawan K Verma,
Sanjay Behari

Departments of Neurosurgery,
²Neurology and ³Pathology,
Sanjay Gandhi Post Graduate
Institute of Medical Sciences,
Lucknow, ¹Department of
Neurosurgery, All India Institute
of Medical Sciences, Raebareilly,
Uttar Pradesh, India

Address for correspondence:

Dr. Jayesh Sardhara,
Department of Neurosurgery,
Sanjay Gandhi Postgraduate
Institute of Medical Sciences,
Rae Bareilly Road, Lucknow,
Uttar Pradesh, India.
E-mail: jayeshsardhara83@
gmail.com

Access this article online

Website: www.asianjns.org

DOI: 10.4103/ajns.AJNS_496_20

Quick Response Code:



How to cite this article: Raiyani V, Singh S, Sardhara J, Mehrotra A, Mani V, Paliwal VK, et al. Seizure outcome after lesionectomy with or without concomitant anteromedial temporal lobectomy for low-grade gliomas of the medial temporal lobe. Asian J Neurosurg 2021;16:518-24.

Submitted: 19-Nov-2020 Revised: 25-Nov-2020

Accepted: 13-Mar-2021 Published: 14-Sep-2021

This is an open access journal, and articles are distributed under the terms of the Creative Commons Attribution-NonCommercial-ShareAlike 4.0 License, which allows others to remix, tweak, and build upon the work non-commercially, as long as appropriate credit is given and the new creations are licensed under the identical terms.

For reprints contact: WKHLRPMedknow_reprints@wolterskluwer.com

epilepsy due to low-grade glioma after lesionectomy with or without AMTR.

Subjects and Methods

Study participants

We retrospectively reviewed all the surgically managed patients of mesial temporal lobe low-grade glioma situated medial to collateral sulcus [Figure 1], presented with seizures (with or without other neurological symptoms) in our tertiary care institute (2012–2020). Patients operated in emergency surgery for uncal herniation ($n = 12$) or those who presented without seizure as presenting complaints ($n = 34$) were excluded. Patients with high-grade glioma, traumatic epilepsy, and patients with a history of epilepsy surgery were also excluded from the study. The data were collected from institutional records and telephonic follow-up. Demographic data and predictors of seizure outcomes such as febrile seizures, duration of epilepsy, family history, history of brain trauma, history of brain infection, secondary generalized tonic-clonic seizures, and abnormal magnetic resonance imaging (MRI) findings were collected and used as data variables. The patients underwent protocol wise presurgical evaluation (phase wise) including semiology charting, interictal electroencephalographic (EEG) recording, video EEG recording, MRI with all the epilepsy protocol sequences, hippocampus volume analysis, and ictal single-photon emission computed tomography or positron emission tomography/computed tomography (in selected patients only). The management plan was discussed between a neurologist, neurosurgeons, radiologist, neuropsychologist, neuropsychiatrist, and our social worker team in a preoperative epilepsy management conference for each patient as per our institutional protocol. Localization and lateralization of the epilepsy focus were based on the confirmation of congruent data of MRI, semiology, and video EEG. Lesionectomy was done when the tumor was not involving hippocampus. The selection of surgical

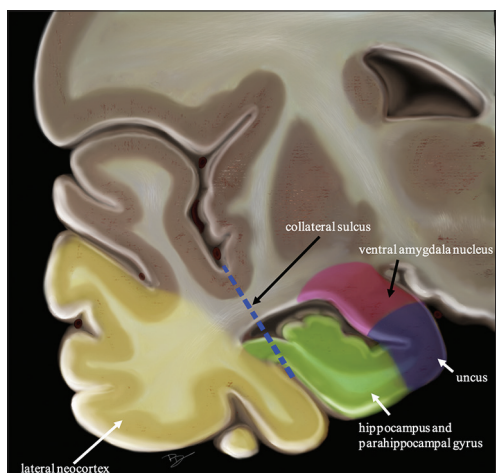


Figure 1: Coronal view of temporal lobe

methods of lesionectomy with AMTR was particularly based on certain factors such as preoperative prediction of epileptic focus based on video-EEG findings, based on the functionality of the mesial temporal lobe structures at the tumor side in the preoperative neuropsychological assessments, infiltration of tumor in the hippocampus, long-term intractability of seizure, preoperative presence of memory and language deficit, and postoperative risk of functional deficit due to dominance.

Surgical techniques

Lesionectomy only

The surgical corridor chosen for lesionectomy (Group A, $n = 20$) includes transcortical ($n = 16$), trans-Sylvian ($n = 2$), and trans-Sylvian combined with transcortical ($n = 2$) approaches. Irrespective of the dominant or nondominant side, medial temporal lobe lesion was excised with the preservation of grossly nonpathological mesial temporal structures such as uncus, amygdala, hippocampus, parahippocampal gyrus, and entorhinal cortex. Part of the tumors in some of the lesions predominantly situated in mesial temporal lesion but extend to the temporal neocortex were also excised completely.

Lesionectomy with anteromesial temporal lobe resection (LAMTR)

Apart from the mesial temporal tumor, in LAMTR, the mesial temporal structures which were excised in a standard manner included uncus, amygdala, hippocampus, parahippocampal gyrus, and entorhinal cortex. It also includes the removal of the lateral temporal neocortex of 3–4 cm on the dominant side and 5 cm on the nondominant side [Figure 2].

Seizure outcome

For comparison of seizure outcome, we divided the patients into two groups: Group I (lesionectomy only [Lo]) and Group II (lesionectomy with anteromesial temporal resection [LAMTR]). The seizure outcome was compared

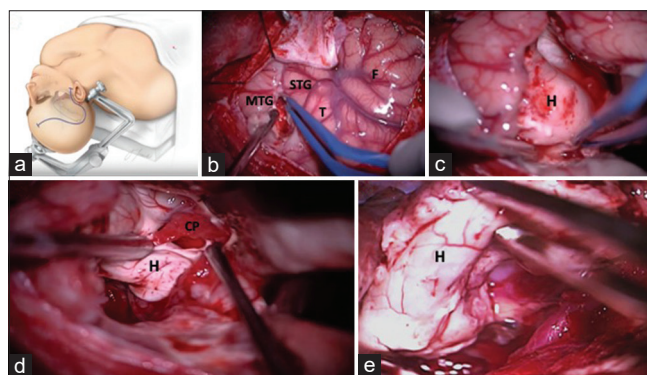


Figure 2: Operative steps of AMTR. Incision on superior temporal sulcus between superior and middle temporal Gyrus [Figure 2a,b]; tumor infiltrating hippocampus [Figure 2c]. Gross total excision of tumor with hippocampus excised [Figure 2d,e]

using the international league against epilepsy (ILAE) scale. ILAE outcome scale: (I) completely seizure-free, (II) only auras, (III) one to three seizure days/year, (IV) four seizure days/year to a 50% reduction in baseline seizure, (V) <50% reduction in baseline seizure days to 100% increase in baseline seizure days, and (VI) more than 100% increase in baseline seizure days. The preoperative subjective neuropsychological evaluation has been done in all the patients undergoing AMTR. Postoperative language, memory was assessed by a neuropsychologist, and cognitive outcomes were also analyzed by mini-mental state exam (MMSE) assessment and scoring individually in both the groups and compared.

Follow-up

Postoperative complications were recognized according to medical records and were measured during follow-up. Follow-up data sources included outpatient medical records and telephonic conversation.

Statistical analysis

All data were analyzed with IBM SPSS (Statistical Software for the Social Sciences) Statistics Version 23.00. Armonk, New York, United States. Quantitative data were compared between the two groups using Student's *t*-test, and categorical characteristics were compared using the Chi-squared test.

Results

Demographics and clinical profile

A total of 55 patients were operated on for lesional mesial temporal lobe epilepsy; of whom 39 patients had low-grade glioma as their histopathology (Group 1, lesionectomy [$n = 20$ patients]; and Group 2 lesionectomy with AMTR [$n = 19$ patients]). The most common pathology encountered was diffuse astrocytoma ($n = 29$), and the mean age of the study population was 26.92 ± 12.96 years (male:female = 1.6:1). The list of various histopathological diagnoses of the operated patients in our study is given in Table 1. The mean age of patients in Group I was 25.80 ± 12.02 years and in Group II was 28.11 ± 14.11 years. The mean duration of seizures was 36.87 ± 46.79 (range from 1 to 192 months) and was comparable in both Groups ($P = 0.452$). The distribution of preoperative types of seizure and other clinical deficits is summarized in Table 2. A total of 23 patients had long-term

intractable seizures for >1-year despite on >2 drugs (Group I [$n = 10$], Group II [$n = 13$]); remaining 19 had frequent seizure of < 1-year duration. Predominantly, right-handed patients outnumbered (26 [66.7%]) compared to left. A total 4 of them admitted with focal aware seizures, 14 patients with generalized onset seizures, and nine patients with focal onset followed by secondary generalized seizures. Six patients had preoperative memory deficit, 2 had preoperative visual deficit, and 3 had preoperative hemiparesis.

Seizure outcome

The most important finding in this study is the substantial individual benefit in the seizure outcome [Table 3]. Out of the 39 patients, a total of 30 patients could be evaluated for ILAE scoring (seven patients from Group I and two patients from Group II were lost to follow-up for seizure outcome assessment). After surgery, a total of 10 (76%) from 13 patients of Group I and 13 (76.47%) patients of Group II had a significant improvement in seizure outcome ($P = 0.05$) with Class 1 ILAE scale. Four (40%) patients out of 10 having refractory seizures in Group I preoperatively and 8 (80%) patients from the Group II out of 10 patients could achieved ILAE I outcome after surgery. In the 10 (58%) patients of Group II, the requirement of antiepileptic drug (AED) decreased successfully after surgery, whereas in 9 (69%) patients, AED was either continued or stepped up in Group I.

Language deficit, memory, and cognitive decline

At the mean follow-up of 54.92 ± 34.09 months (range from 8 to 115 months), return to work (RTW) and patient's satisfaction were almost similar in both the groups (11 in Group I vs. 15 in Group II [$P = 0.185$]). Seven patients from Group I and two patients from Group II were lost in follow-up, so we compared seizure outcome between 13 patients of Group I and 17 patients of Group II. Few case illustrations of patients who underwent lesionectomy with AMTR [Figures 2-5] are demonstrated.

In the MMSE scoring, there was no significant difference between overall cognitive decline in the comparison between two groups (Group I: 27.33 ± 2.73 ; Group II: 28.00 ± 2 , $P = 0.602$) [Table 4]. In our study, one patient developed new-onset neurological deficits (including temporary memory loss for 3 months then improved) after left side AMTR.

In Group I, $n = 6$ and in Group II, $n = 14$ patients,

Table 1: Histopathological diagnosis of patients included in our series among two groups ($n=39$)

Histopathology	Group I, lesionectomy only ($n=20$)	Group II, AMTR + lesionectomy ($n=19$)
Astrocytoma (WHO Grade I-II)	14	15
Ependymoma	1	0
Glioneural tumor	5	3
Astrocytoma associated with mesial temporal sclerosis	0	1
Associated hippocampal CA1 neuronal loss	0	2

AMTR - Anteromesial temporal resection

Table 2: Demographic and clinical profile of the patients in the Group I and II (total, n=39)

Clinical parameter	Group I (n=20)	Group II (n=19)	P
Age, years (mean±SD)	25.80±12.02	28.11±14.12	0.539
Gender (male:female)	13:7	11:8	0.648
Duration of seizures, months (mean±SD)	29.10±32.37	45.05±58.12	0.452
Type of seizures in preoperative period			
Focal unaware	5	5	
Focal aware	2	2	
GTCS	9	5	
Focal with generalization	4	5	
Mixed	0	2	
Handedness			
Left	2	2	0.01
Right	18	17	
Side of surgery			
Left	7	8	0.152
Right	13	11	
Extent of resection			
Gross total	19	18	0.299
Sub total	0	1	
Follow-up duration, months (mean)	69.5	39.6	
Recurrence	2	0	
RTW	11	15	0.185

GTCS - Generalized tonic clonic seizure; SD - Standard deviation; RTW - Return to work

Table 3: Statistical comparison of seizure outcome among two groups after surgery (n=39)

Seizure outcome	Group I (n=13; 100%), n (%)	Group II (n=17; 100%), n (%)	P (P<0.05 considered significant)
ILAE Scale outcome			
Class I	10 (76.9)	13 (76.47)	0.05
Class II	0	0	
Class III	1 (7.69)	3 (17.65)	
Class IV	1 (7.69)	0	
Class V	1 (7.69)	1 (5.88)	
Class VI	0	0	

ILAE - International league against epilepsy; AED - Anti-epileptic drug

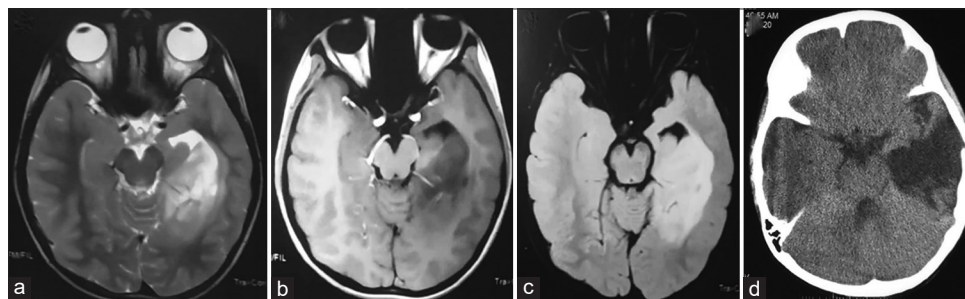


Figure 3: Magnetic resonance imaging (a-c) and computed tomography (d) of ganglioneuroma operated by AMTR with gross total excision

patients who were illiterate and could not perform MMSE effectively were excluded from the statistical analysis.

Neuro-oncological outcome

A total of 37 patients among 39 underwent a gross total excision and two of them had recurrence with a residual tumor on 30-month and 44-month follow-up. Two patients had a recurrence in our study, with ganglioglioma presented

with recurrence after 5-year, and other patient had oligoastrocytoma, recurrence develops on 9-year follow-up. Both the patients belong to Group I and had undergone only lesionectomy. Both were right-handed and underwent gross total excision which was evident in postoperative MRI. None of the patients had any postoperative complications and both had ILAE Class I seizure outcome. None of them had any wound-related complications during a hospital

Table 4: Language deficit, memory decline and cognitive decline after surgery of the two groups in our study (n=39)

Clinical parameter	Group I lesionectomy only (total, n=20)	Group II lesionectomy with AMTR (total, n=19)	P
Cognitive decline by MMSE score (mean±SD) [#]	27.33±2.73	28.00±2.0	0.602
Language deficit			-
Preoperative	3	3	
Postoperative			
Persist	1	2	
Improved	2	1	
New onset	0	1	
Memory decline			-
Preoperative	2	4	
Postoperative			
Persist	1	2	
Improved	0	2	
New onset	0	1	

[#]In Group I (n=6) and in Group II (n=14) patients, patients who were illiterate and could not perform MMSE effectively were excluded from the statistical analysis. AMTR - Anteromesial temporal lobe resection; MMSE - Mini-mental state exam; SD - Standard deviation

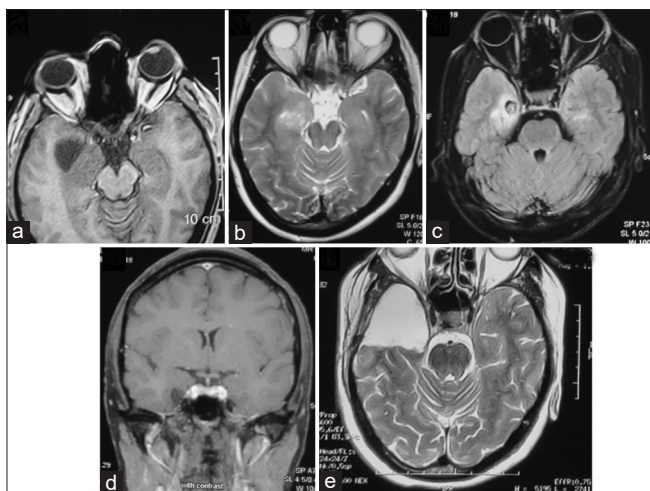

Figure 4: (a-e) Magnetic resonance imaging of a patient with medial temporal pilocytic astrocytoma operated by AMTR

stay. One patient had a new-onset memory loss and Two patients had persistent preoperative memory loss and one had cognitive decline (MMSE score 18). Two patients had new-onset temporary subtle hemiparesis resolved within 2–4 weeks. None of the patients had visual loss after surgery in both groups. One patient had intraoperative bleeding during lesionectomy (for medial temporal glioma), controlled by meticulous hemostasis without any subsequent postoperative residual complication. In preoperative, none of the patients in Group I had visual field defects, while two patients in Group II had visual field defects.

Discussion

Impact of involvement of mesial temporal structure in resection strategy on seizure outcome

Our results support the notion that, for the lesions situated in the mesial temporal lobe, lesionectomy with AMTR

yield better seizure outcome compared to lesionectomy alone. There was a significant difference between the two surgical approaches in the context of seizure outcome as per ILAE outcome assessment during follow-up ($P = 0.05$). Moreover, the majority of our patients (in both groups) reported improved quality of life and patient satisfaction in the form of RTW during follow-up. This result is also supported by very few studies available in the literature which favors better seizure outcome with AMTR compare to lesionectomy in the temporal neoplastic lesion.^[6-9] In a retrospective series of thirty patients with temporal mass lesions, by Jooma *et al.*, the authors reported that 19% in the “lesionectomy” and 93% in the second group (lobectomy) were seizure free at the last follow-up.^[9] In their five patients of “lesionectomy” group, patients failed to show seizure control and needed temporal lobectomy as a second procedure; after which they became seizure free. This study favored tailored resection in mesial temporal structure along with lesion for mesiotemporal lesion producing epilepsy. Giulioni *et al.*^[8] reported 28 patients with mesial temporal glioneuronal tumors treated by lesionectomy alone or selective lesionectomy (14 patients) and tailored temporal or anterior temporal resection (14 patients). They reported that gross-total removal of the tumor was achieved in 11 patients (78.6%) and six patients (42.8%) were seizure free (Engel I) and 8 (57.1%) had a rare disabling seizure, almost seizure free (Engel II) in lesionectomy only group. On the other hand, gross total removal of the tumor was achieved in all patients, and 13 patients (93%) were seizure free (Engel I), and 1 (7.1%) had a rare seizure (Engel II) in the anterior temporal resection group. Thus, the authors’ results demonstrate a better seizure outcome for temporo mesial glioneuronal tumors associated with epilepsy in patients who underwent tailored resection rather than simple lesionectomy ($P = 0.005$). However, this study particularly compared the glioneuronal tumors only which frequently coexisted with secondary sclerosis

or dysplasia in the adjacent hippocampus.^[8] Only one patient in our study (in Group II), had sclerotic changes adjacent to the hippocampus near mesial ganglioglioma tumor in a 14-year-old child who became seizure free after surgery. In another study by Lombardi *et al.*, 15 cases (8 extrahippocampal and 7 with the invasion of the amygdalohippocampus) were analyzed.^[6] The eight extra-hippocampal tumors were treated with lesionectomy. The seizure outcome was Class 1 in only four cases, while the remaining four were Class 4 according to Engel's classification. The four cases with Class 4 outcome required additional temporal lobectomy associated with amygdalohippocampectomy for seizure control. According to that study, hippocampal atrophy is one of the important findings on MRI which can predict poor outcome and one of the indications of AMTR in the first stage.

Factors influencing favorable seizure outcome

A total 80% achievement of complete seizure freedom rate (ILAE Class I) in the lesionectomy with AMTR group, especially in refractory seizures patients in our study indicate the successful radical excision of epileptogenic network from the hippocampus, amygdala, and entorhinal cortex due to probably kindling phenomenon in those patients. Coexisted hippocampal neuronal loss associated with a mesial temporal tumor is also one of the important attributed factors responsible for subsequent strong epileptogenic network formation particularly in the hippocampus and amygdala region which was suggested by various authors.^[10,11] In our study, two patients in Group 2 (only 10 patients had hippocampus histopathological analysis; by neuropathologist) had

findings of neuronal loss in the CA1 layer of the hippocampus associated with tumor [Figure 5]. Gross total excision of a tumor can also be the predominant factor responsible for favorable seizure outcome in both groups.

The majority of the patients, $n = 35$ (90%), were right handed with left cerebral dominance. A total of eight patients underwent left side AMTR for mesial temporal glioma. As per the neuropsychological assessment, all of the patients had shifting of their memory function to the right side (nondominant site) except one patient, in which after surgery develop temporary memory deficit. Apart from language and memory function, the predominant functional outcome (RTW) also depends on cognitive ability. Good MMSE score in postoperative outcome in Group II reflects favorable cognitive outcome due to complete freedom from seizures.

Surgical consideration

In our experience, lesionectomy is safer and has a shorter operation time than we found for AMTR. Reducing vascular damage during the operation might also help to decrease the risk of intracranial hemorrhage in lesionectomy only. However, in this study, the risk of complications was similar and less in both. AMTR demands substantial surgical expertise and experience to cope with the steep learning curve than lesionectomy only. We have used intraoperative EEG during lesionectomy, it helps us to excise the adjacent gliotic area apart from the tumor for optimal excision of epileptogenic tissue.

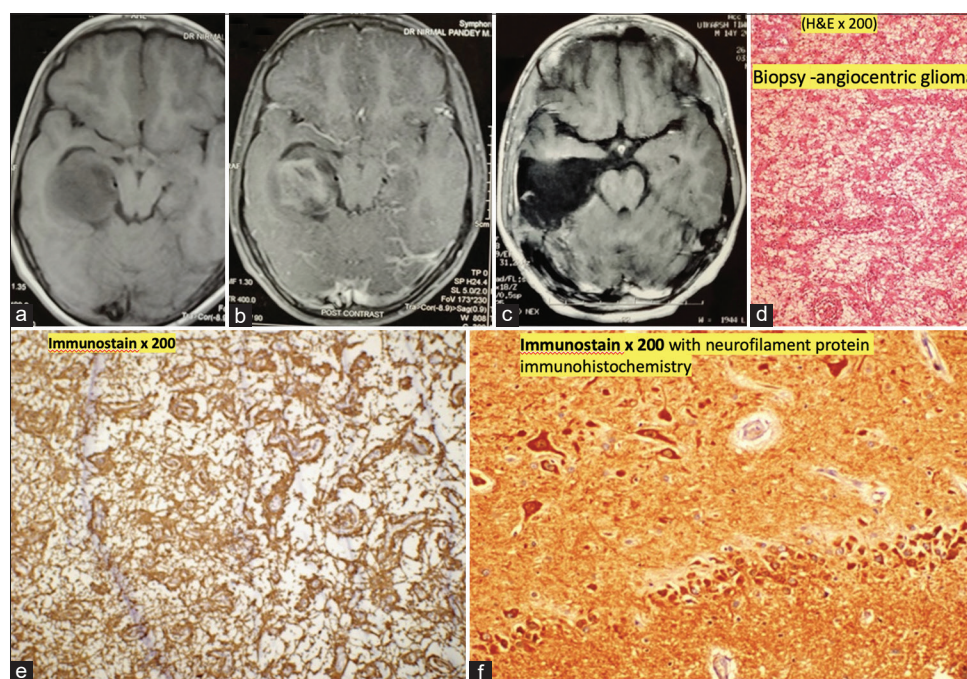


Figure 5: (a-c) The patient underwent AMTR. Histopathology showing mildly anisomorphic astrocytes around thin vascular spaces with microcystic degeneration (d). GFAP (Glial fibrillary acidic protein) positive (e). Hippocampus section showing focal loss of granule cell neurons (f)

Limitation in our study

A small sample size limits substantial conclusory remarks. A prospective, double-blinded, randomized study is warranted to substantiate our findings. Evaluations of verbal memory deficits and cognitive outcomes are limited by the retrospective study design.

Conclusion

For the mesial temporal low-grade glioma presenting with predominantly seizures, seizure outcome by lesionectomy with AMTR is superior compare to lesionectomy only. However, randomized controlled trials with larger sample sizes however are further desired.

Financial support and sponsorship

Nil.

Conflicts of interest

There are no conflicts of interest.

References

1. Radhakrishnan K, So EL, Silbert PL, Jack CR Jr., Cascino GD, Sharbrough FW, *et al.* Predictors of outcome of anterior temporal lobectomy for intractable epilepsy: A multivariate study. *Neurology* 1998;51:465-71.
2. McIntosh AM, Wilson SJ, Berkovic SF. Seizure outcome after temporal lobectomy: Current research practice and findings. *Epilepsia* 2001;42:1288-307.
3. Téllez-Zenteno JF, Dhar R, Wiebe S. Long-term seizure outcomes following epilepsy surgery: A systematic review and meta-analysis. *Brain* 2005;128:1188-98.
4. Helmstaedter C, Elger CE, Hufnagel A, Zentner J, Schramm J. Different effects of left anterior temporal lobectomy, selective amygdalohippocampectomy, and temporal cortical lesionectomy on verbal learning, memory, and recognition. *J Epilepsy* 1996;9:39-45.
5. Iannelli A, Guzzetta F, Battaglia D, Iuvone L, Di Rocco C. Surgical treatment of temporal tumors associated with epilepsy in children. *Pediatr Neurosurg* 2000;32:248-54.
6. Lombardi D, Marsh R, de Tribolet N. Low grade glioma in intractable epilepsy: Lesionectomy versus epilepsy surgery. *Acta Neurochir Suppl* 1997;68:70-4.
7. Casazza M, Avanzini G, Ciceri E, Spreafico R, Broggi G. Lesionectomy in epileptogenic temporal lobe lesions: Preoperative seizure course and postoperative outcome. *Acta Neurochir Suppl* 1997;68:64-9.
8. Giulioni M, Rubboli G, Marucci G, Martinoni M, Volpi L, Michelucci R, *et al.* Seizure outcome of epilepsy surgery in focal epilepsies associated with temporomesial glioneuronal tumors: Lesionectomy compared with tailored resection. *J Neurosurg* 2009;111:1275-82.
9. Jooma R, Yeh HS, Privitera MD, Gartner M. Lesionectomy versus electrophysiologically guided resection for temporal lobe tumors manifesting with complex partial seizures. *J Neurosurg* 1995;83:231-6.
10. Spencer DD. Strategies for focal resection in medically intractable epilepsy. *Epilepsy Res Suppl* 1992;5:157-68.
11. Sperling MR, Cahan LD, Brown WJ. Relief of seizures from a predominantly posterior temporal tumor with anterior temporal lobectomy. *Epilepsia* 1989;30:559-63.