

“Contralateral Dry Eye in Hemifacial Spasm:” A New Clinical Sign

Abstract

Hemifacial spasm (HFS) is a benign condition characterized by unilateral, involuntary, paroxysmal clonic and tonic contractions of the facial muscles. This condition usually results from a focal demyelination at the root entry zone of the 7th cranial nerve secondary to a vascular loop compression, and hence, it responds to microvascular decompression (MVD) surgery, similar to trigeminal neuralgia. Herein, we report an interesting clinical finding of a contralateral dry eye in the case of HFS, which has not been described previously and discuss the possible underlying mechanisms. A 53-year-old man presented with a 6-month history of involuntary twitching movements of the left hemiface that persisted during sleep, consistent with the diagnosis of HFS. The patient's attempts to voluntarily control the troublesome involuntary left-sided eye blinking led to the development of dryness and reddening of the right eye. Corneal reflex, both direct and consensual, was intact bilaterally, and an ophthalmological examination ruled out the diagnosis of conjunctivitis. The patient underwent MVD of the facial nerve. To our surprise and validating our supposition, his contralateral conjunctival hyperemia and dry eye resolved within a day of surgery, along with complete resolution of the HFS. HFS can lead to the contralateral dry eye from the voluntary suppression of ocular blinking which resolves following MVD. We demonstrate this finding for the first time and believe its recognition may be of value in the patient management.

Keywords: *Blink reflex, dry eye, endoscopic microvascular decompression, hemifacial spasm*

Introduction

Hemifacial spasm (HFS) represents a functional neurosurgical disorder with an incidence of approximately 0.81/100,000 in women and 0.74/100,000 in men.^[1] It is characterized by unilateral, involuntary, paroxysmal clonic and tonic contractions of the facial muscles, affecting mainly the middle-aged females.^[1] The pathophysiology of HFS is akin to trigeminal neuralgia and involves focal demyelination at the root entry zone of the 7th nerve, secondary to a vascular loop compression with a subsequent ephaptic neural transmission. Typically, these patients undergo microvascular decompression (MVD) with good long-term symptom relief.^[1] Herein, we report an interesting clinical finding of the contralateral dry eye in a 53-year-old gentleman and its resolution following MVD. To the best of our knowledge, this finding has not been described previously. We discuss the possible underlying mechanisms of this finding in this report.

This is an open access journal, and articles are distributed under the terms of the Creative Commons Attribution-NonCommercial-ShareAlike 4.0 License, which allows others to remix, tweak, and build upon the work non-commercially, as long as appropriate credit is given and the new creations are licensed under the identical terms.

For reprints contact: reprints@medknow.com

Case Report

A 53-year-old man presented with left-sided HFS. His symptoms were present for 6 months and persisted despite several trials of pharmacotherapy. He was hypertensive, albeit well-controlled pharmacologically. On clinical examination, there was an evidence of severe, repetitive spasms on the left hemiface with a reduced rate of blinking on the right side [Figure 1a, b and Supplementary Video 1]. There were dryness and reddening of the right eye without any corneal abrasion. Corneal reflexes were present bilaterally, and no other neurological deficits were present in this patient. An ophthalmological examination ruled out conjunctivitis or any other evident cause for the patient's symptoms and a possibility of dry eye was suggested.

On magnetic resonance images (MRI) of the head, there was no mass lesion in the cerebellopontine angle, and on constructive interference in steady state sequences of MRI, there was an evident compression of the 7th nerve by a vascular loop [Figure 2a]. The patient underwent a left-sided retromastoid keyhole

How to cite this article: Gosal JS, Das KK, Khatri D, Attri G, Jaiswal AK. “Contralateral dry eye in hemifacial spasm:” A new clinical sign. *Asian J Neurosurg* 2019;14:996-8.

**Jaskaran Singh Gosal,
Kuntal Kanti Das,
Deepak Khatri,
Gagandeep Attri,
Awadhesh Kumar Jaiswal**

*Department of Neurosurgery,
Sanjay Gandhi Postgraduate
Institute of Medical Sciences,
Lucknow, Uttar Pradesh, India*

Address for correspondence:

*Dr. Kuntal Kanti Das,
Department of Neurosurgery,
Sanjay Gandhi Postgraduate
Institute of Medical
Sciences, Rae Bareilly
Road, Lucknow - 226 014,
Uttar Pradesh, India.
E-mail: drkuntalkantidas@
gmail.com*

Videos Available on:
www.asianjns.org

Access this article online

Website: www.asianjns.org

DOI: 10.4103/ajns.AJNS_48_19

Quick Response Code:



craniotomy and endoscope-assisted MVD of the 7th nerve [Figure 2b and Supplementary Video 2]. There was a ventral indentation of the cisternal segment of the left 7th nerve from anterior inferior cerebellar artery (AICA). Using the utmost care, the vessel was gently separated from the nerve and MVD was performed [Figure 2c-e and Supplementary Video 2]. The HFS resolved immediately after the surgery, and in addition to that, conjunctival reddening and dryness of his right eye also improved on the very next day [Figure 1c, d and Supplementary Video 3]. His hearing remained intact postoperatively. The patient

was discharged on the 3rd postoperative day. The patient is doing well at 3-month follow-up.

Discussion

HFS is a benign condition characterized by unilateral, involuntary, paroxysmal clonic and tonic contractions of the facial muscles.^[2] Janetta has championed the idea that it is caused by the vascular compression of the facial nerve at its root exit zone from the pons, most commonly by an AICA loop.^[1,2] It needs to be differentiated from facial myokymia, blepharospasm, facial tic, and focal motor seizures.^[2] In facial myokymia, the facial movements are unilateral, continuous, fine and undulating unlike paroxysmal and tonic/clonic in HFS. Myokymia can be a sign of structural lesion in the pons with the two most common lesions being pontine glioma and multiple sclerosis. Blepharospasm is invariably bilateral and disappears during sleep. In focal motor seizures, both eyelids blink because of bilateral control of the facial nerve nuclei by contralateral motor cortex in addition to an associated conjugate deviation of eyes/head to opposite side.^[2] HFS and palatal myoclonus are the only two movement disorders which persist during sleep.

We demonstrate an interesting and a new clinical finding of the contralateral dry eye in HFS in this report. As the red and dry eye improved soon after the relief of HFS following surgery, we believe the spasmodic eye had something to do with this phenomenon. The dryness and subsequent reddening of the eye could be because of inadequate

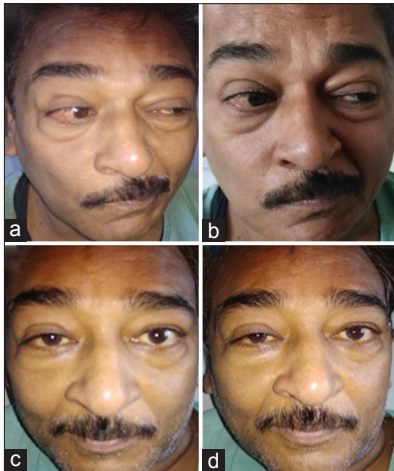

Figure 1: (a and b) are the preoperative images of the patient showing hemifacial spasm on the left side and red eye on the right side. Immediate postoperative clinical images (c and d) showing resolution of both hemifacial spasm (left side) and redness on the right side

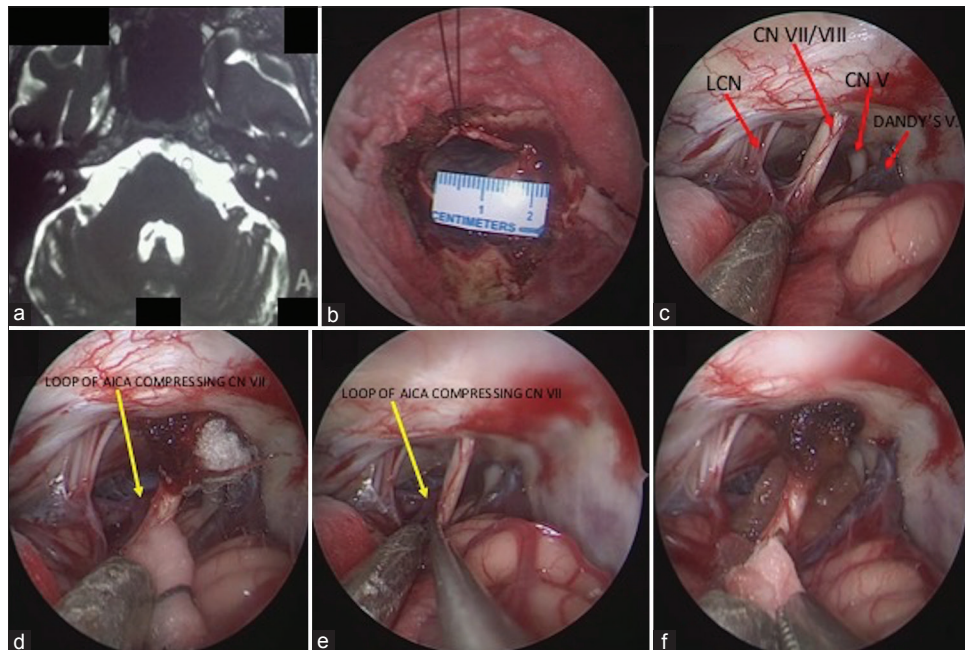


Figure 2: Shows the constructive interference in steady state sequence of magnetic resonance images (a) with a vascular loop compressing the seventh cranial nerve on the left side. There was no mass lesion in the left cerebellopontine angle. (b) shows the keyhole retromastoid suboccipital craniotomy (2.5 cm × 2 cm) and dural opening. (c) shows the anatomy in the left cerebellopontine angle under endoscopic vision. An anterior inferior cerebellar artery loop is seen compressing the facial nerve anteriorly at the root entry zone close to pons (d and e). A Teflon sponge is placed between the facial nerve and the AICA loop (f). LCN – Lower cranial nerves; CN V – Trigeminal nerve; CN VII/VIII – Seventh/eighth cranial nerve complex; Dandy's V. – Dandy's vein

blinking on the right side, perhaps as a part of the central adaptation of the blink reflex in response to HFS. The blink pathway is depicted in the Figure 3. It is well known that the blink centers located in the globus pallidus can be adaptively controlled. In patients with unilateral facial palsy, there is an increased blinking rate of the contralateral eye, as a compensatory supranuclear stimulation of the orbicularis oculi (OO) motoneuron. The fact that OO has practically no role in the lid movement, it is over activation manifests only during blinks. We believe the response to unilateral HFS is exactly the opposite. Reduced blinking on the opposite eye is an adaptive phenomenon to involuntary HFS. The downside of this new physiology is that the tear film is either unable to form over the eyeball or it loses its stability. The resultant effect was dryness and reddening, mediated by intact trigeminal sensory pathway and ocular sympathetic nerves.^[3]

With the resolution of the left HFS, the inhibited blinking phenomenon resumed its normal pattern and soon led to resolution of the dry eye. Exclusion of other possible causes and improvement after surgery supported our observation. This may be regarded as an important clinical sign of dry/red opposite eye in a patient of HFS.

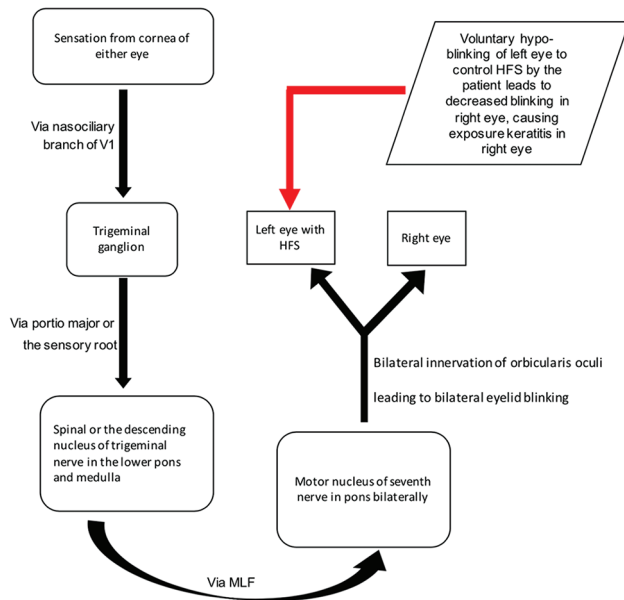


Figure 3: Normal “Blink reflex” pathway and the proposed pathophysiological mechanism of contralateral dry eye in a patient of HFS. HFS – Hemifacial spasm, MLF – Medial longitudinal fasciculus, V1 – Ophthalmic division of trigeminal nerve

HFS rarely responds to medications.^[1,4,5] Although local botulinum toxin injections provide symptomatic relief in HFS, the effect is generally temporary requiring repeated procedures every 3–4 months.^[1,4,5] MVD of the seventh nerve represents the only durable and effective treatment providing long-term success rates above 90%, which is a relatively low-risk procedure these days.^[1,5] We performed this procedure entirely using an endoscope utilizing a small keyhole craniotomy. Endoscopic MVD has recently become a popular surgical technique with favorable surgical results.^[5]

Conclusion

The HFS can lead to contralateral dry eye, as demonstrated in our patient. We believe it represents the downside of a physiological adaptive phenomenon. It is essential to be aware of this interesting clinical phenomenon in HFS, and its recognition can facilitate an optimal treatment and prognostication.

Declaration of patient consent

The authors certify that they have obtained all appropriate patient consent forms. In the form the patient(s) has/have given his/her/their consent for his/her/their images and other clinical information to be reported in the journal. The patients understand that their names and initials will not be published and due efforts will be made to conceal their identity, but anonymity cannot be guaranteed.

Financial support and sponsorship

Nil.

Conflicts of interest

There are no conflicts of interest.

References

- Rosenstengel C, Matthes M, Baldauf J, Fleck S, Schroeder H. Hemifacial spasm: Conservative and surgical treatment options. *Dtsch Arztebl Int* 2012;109:667-73.
- Rengachary SS. Cranial nerve examination. In: Wilkins RH, Rengachary SS, editors. *Neurosurgery*. 2nd ed. United States of America: McGraw-Hill; 1996. p. 79-80.
- van Setten GB. Dry eye syndrome, tear film, pharmacology of eye drops, and toxicity. *Curr Opin Ophthalmol* 1997;8:41-5.
- Abbruzzese G, Berardelli A, Defazio G. Hemifacial spasm. *Handb Clin Neurol* 2011;100:675-80.
- Costa J, Espírito-Santo C, Borges A, Ferreira JJ, Coelho M, Moore P, *et al.* Botulinum toxin type A therapy for hemifacial spasm. *Cochrane Database Syst Rev* 2005;(1):CD004899.