

Iatrogenic (Traumatic) Occipital Artery Pseudoaneurysm – Rare Complication of Ventriculoperitoneal Shunt in an Infant: Case Report and Review of the Literature

Abstract

Although ventriculoperitoneal shunt (VPS) is the most common procedure performed by pediatric neurosurgeons, it is still associated with frustrating complications, most common of which are obstruction and infection. Traumatic occipital artery pseudoaneurysm is a very rare complication of VPS procedure. To the best of our knowledge, there is no similar case reported in the English language literature. A 12-month-old patient suffered posthemorrhagic hydrocephalus of prematurity, and multiple other complications due to extreme prematurity, including immature lung disease, retinopathy of prematurity, necrotizing enterocolitis, bowel perforation, short bowel syndrome resulting in total parenteral nutrition-dependence, and hydrocephalus which was treated by insertion of VPS. Four weeks after the shunt, a slowly enlarging pulsatile swelling distal to the valve under the catheter altering the shunt function was noted. The swelling was diagnosed as a pseudoaneurysm of the occipital artery and treated by excision of the aneurysm. The child developed isolated dilated fourth ventricle, which was treated by endoscopic fourth ventriculostomy. Traumatic occipital artery pseudoaneurysm as a result of tunneling of VPS catheter is a very rare complication of VPS. Clinical and radiological imaging is diagnostic of the aneurysm. Surgical repair should be considered in such cases. This case report is aimed to raise the awareness among physicians about this rare complication.

Keywords: Endoscopic ventriculostomy, hydrocephalus, short bowel syndrome, traumatic pseudoaneurysm, ventriculoperitoneal shunt

Introduction

Ventriculoperitoneal shunt (VPS) is the most common cerebrospinal fluid (CSF) diversion procedure performed for the treatment of hydrocephalus, and the commonest procedure performed by pediatric neurosurgeons. However, like any other procedure, it is frequently associated with many complications, commonly underdrainage and infection.^[1-3] Uncommon, yet well-reported, complications include suboptimal catheter position, overdrainage, catheter migration, seizures, hemorrhage, and bowel perforation.^[1-3] Vascular injuries are rare complications of VPS, and even rarer injuries result from tunneling of the shunt distal catheter.

Only a handful of cases of traumatic occipital artery aneurysms are reported, but injury to the occipital artery leading to pseudoaneurysm formation as a result of tunneling to pass the distal catheter of VPS

is very rare.^[4-10] Moreover, swelling of the aneurysm may disturb the shunt valve or catheter, interrupting spontaneous flow of the CSF leading to underdrainage which can significantly affect the patient. The authors report a case of traumatic extracranial pseudoaneurysm of the occipital artery following VPS procedure in an infant with a review of the literature.

Case Report

The patient is a female infant born preterm at gestational age of 24 weeks, weighting 670 g. She had immature lung disease that was treated with surfactant injection and mechanical ventilation immediately after birth. Eight days later, she developed necrotizing enterocolitis and rapidly complicated to bowel perforation and fulminant peritonitis. Initially, managed with insertion of peritoneal drain, but eventually, laparotomy and resection of a long bowel segment were performed. This

Mohannad Essam Elgamal,
Essam A. Elgamal¹,
Anwar Ahmad¹,
Adham Aly Elsayed¹,
Basel Younes¹,
Mohammad Khalid Aljaraki¹,
Tamer Ibrahim Elholiby²

College of Medicine, Mohammed Bin Rashid University of Medicine and Health Sciences, Dubai, ¹Division of Neurosurgery, Surgery Institute, Sheikh Khalifa Medical City, ²Department of Radiology, Sheikh Khalifa Medical City, Abu Dhabi, UAE

Address for correspondence:

Dr. Essam A. Elgamal,
 Division of Neurosurgery,
 Surgery Institute, Sheikh
 Khalifa Medical City, P O
 Box 51900, Abu Dhabi, UAE.
 E-mail: eelgamal@hotmail.com

Access this article online

Website: www.asianjns.org

DOI: 10.4103/ajns.AJNS_45_18

Quick Response Code:



How to cite this article: Elgamal ME, Elgamal EA, Ahmad A, Elsayed AA, Younes B, Aljaraki MK, *et al.* Iatrogenic (Traumatic) occipital artery pseudoaneurysm – Rare complication of ventriculoperitoneal shunt in an infant: Case report and review of the literature. Asian J Neurosurg 2018;13:914-7.

This is an open access journal, and articles are distributed under the terms of the Creative Commons Attribution-NonCommercial-ShareAlike 4.0 License, which allows others to remix, tweak, and build upon the work non-commercially, as long as appropriate credit is given and the new creations are licensed under the identical terms.

For reprints contact: reprints@medknow.com

resulted in short bowel syndrome and total parenteral nutrition dependence.

At 2 months old, cranial ultrasound showed bilateral Grade IV intraventricular hemorrhage with significant ventricular dilation, and subsequently, she developed posthemorrhagic hydrocephalus, confirmed by magnetic resonance imaging (MRI) of the brain [Figure 1a and b]. When repeated ventricular tapping proved insufficient, a ventricular access device (Ommaya reservoir) was inserted for repeated, intermittent CSF drainage. She passed through difficult times with repeated sepsis and was not ready for CSF shunting.

At 8 months of age, her weight was 9.95 Kg and CSF protein improved to 2.14 g/L, the hydrocephalus did not resolve, and she was finally eligible for a permanent VPS insertion. Ommaya reservoir was removed and replaced with a permanent VPS. During the procedure, tunneling distal shunt catheter was smooth and uneventful, and the patient endured the surgery very well.

Postoperatively, head size showed initial improvement, but after 4 weeks, due to progressive enlargement of the head, and appearance of a subcutaneous swelling behind the ear, an MRI and Doppler Ultrasound were conducted. MRI scan showed evidence of hydrocephalus, and a subcutaneous swelling above and behind the left ear, and Doppler Ultrasound examination revealed well-defined and lobular cystic lesion, with a thick peripheral wall in the left supra articular region, measuring fully at 3.1 cm × 2.3 cm with the cystic portion containing blood flow at 1.5 cm × 1.8 cm. These findings conclude that the swelling's appearance is consistent with a pseudoaneurysm [Figure 2].

The aneurysm and malfunctioning VPS demanded exploration. The pseudoaneurysm was found attached to posterior branch of the left occipital artery, pushing against the shunt tubing [Figure 3]. The aneurysm was excised, and shunt function was restored.

Two months later, the patient further developed shunt malfunction and progressive head enlargement. Endoscopic fenestration of the dilated, isolated fourth ventricle, and endoscopic third ventriculostomy (ETV) was performed. During the procedure, prepontine cistern was very shallow, and the success of the ETV was considered unreliable; therefore, shunt revision and resetting of the valve pressure to 200 mm CSF was undertaken at the same time. She tolerated the procedure and postoperatively head size remained stable with soft widely opened anterior fontanelle without the need to change shunt pressure.

Unfortunately, after 6 months, the patient has been very sick with Gram-negative septic shock, that complicated to multiple organ failure and an overall critical prognosis, regrettably passing away at 15 months of age.

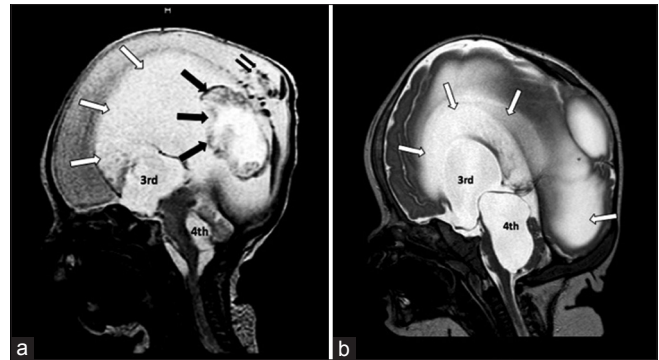


Figure 1: (a and b) Magnetic resonance imaging Sagittal view, T2WI, showing massive hydrocephalus with dilated lateral ventricle (white arrows), and dilated third and fourth ventricle (3rd and 4th). Note (a) intraventricular hemorrhage (black arrows) and occipital intraparenchymal hemorrhage (double black arrows)

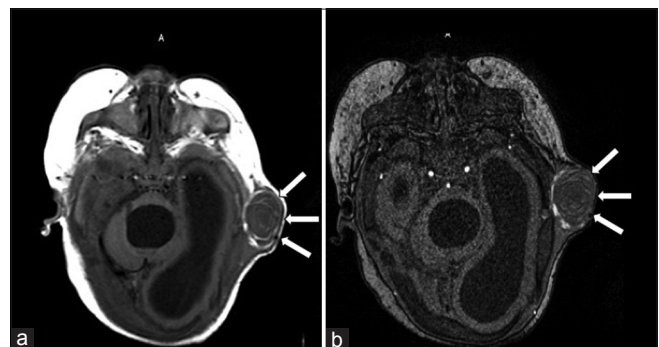


Figure 2: (a and b) Axial magnetic resonance imaging, T1WI before (a) and after intravenous injection of contrast (b) showing well-defined, round, lobular- cystic subcutaneous swelling above and behind the left ear, with a thick peripheral wall, containing blood flow consistent with a pseudoaneurysm of the occipital artery

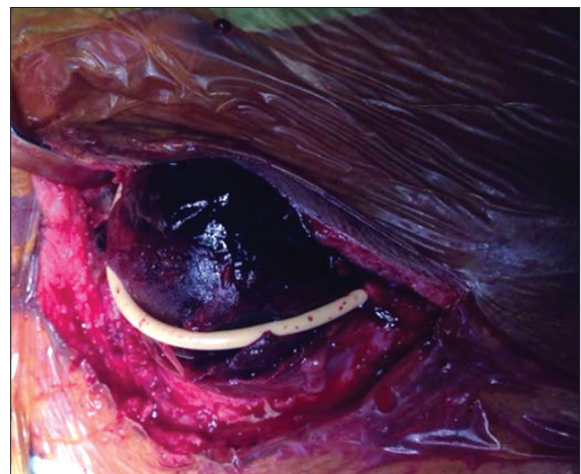

Figure 3: Operative picture of the occipital artery aneurysm distorting and pushing the shunt distal catheter (white) away of its course explaining shunt malfunction

Discussion

VPS is the most common CSF diversional procedure used for the treatment of hydrocephalus in infants. During this procedure, tunneling of subcutaneous tissue takes

place to pass the distal catheter between abdominal and scalp wounds. A rigid metal tunneling tool is usually used with some degree of controlled force especially at the tough area of deep fascia between head and neck of the patient. The tunneling part of the procedure may be associated with a variety of complications including hematoma formation, traversing the thorax, erythema, skin breakdown with exposure of shunt behind the ear, and penetration of the skin.^[1-3,11] Vascular injury with subsequent formation aneurysm/pseudoaneurysm is a very rare complication.

In this report, the authors present the first case in the English language literature, to our knowledge, of iatrogenic posttraumatic occipital artery pseudoaneurysm resulting from insertion of VPS. We found more cases reported in the literature of traumatic occipital artery pseudoaneurysm, none of which were attributed to injury from tunneling for insertion of VPS catheter.^[4-10] In almost all cases, disruption of the vessel wall caused by blunt trauma, allowing blood to leak into the surrounding tissues and form a pulsatile hematoma. Pseudoaneurysm lacks a fibrous wall and is contained by a surrounding shell of hematoma and the overlying scalp. Another possibility may be shearing of the adventitia and muscle layers of the vessel leaving an unsupported weak intimal layer, which bulges to form an aneurysm. A pseudoaneurysm usually presents as enlarging, pulsatile swelling in the scalp, sometimes painless but usually tender to touch, with associated thrill or bruit. Complications of pseudoaneurysms include rupture, embolization, local pain, neuropathy, and local skin ischemia.^[4,10,12] The authors assume in this case that the aneurysm played a role in disturbing the shunt function when revision revealed a functioning shunt after removal of the aneurysm.

In this case, the pseudoaneurysm developed as a result of direct injury by blunt force delivered to the vessel during the passage of the tunneler for insertion of distal shunt catheter. The suboccipital segment of the occipital artery which crosses the sagittal plane in the region of superior nuchal line is vulnerable to trauma as it is at the route of tunneling and an increased risk for force injury by the blunt tip of the metal tunneler specifically where it is superficial and poorly covered by muscle.

The diagnosis of occipital artery pseudoaneurysm can always be made by Doppler ultrasound, CT and MR angiography scans. These modalities are noninvasive diagnostic techniques that allow precise assessment of occipital artery abnormalities and traumatic pseudoaneurysm.^[13-15] Treatment options usually include surgical resection of the aneurysm, proximal ligation or trapping, endovascular arterial embolization, and coil occlusion or direct thrombin injections have also been employed although inducing embolism is a possible complication.^[13,16,17] Endovascular treatment can be an

effective method for treating ruptured occipital artery aneurysm. In this case report, the pseudoaneurysm was large and palpable as a mass under the scalp, and the authors suggested surgical exploration is indicated because of shunt malfunction, therefore treatment by endovascular embolization was not explored.

Traumatic intracranial aneurysm related to VPS procedure is very rare. Literature review revealed no similar cases of iatrogenic pseudoaneurysms to the occipital artery as a complication of VPS, most reports being related to direct external blunt force trauma. Angevine and Connolly reported two cases of superficial temporal artery pseudoaneurysm related to insertion of external ventricular drain, caused by sharp injury to the vessel during incision of the skin for twist drill hole placement or the use of a sharp trocar for subcutaneous tunneling of catheters.^[18] Jenkinson *et al.*^[19] reported ruptured traumatic middle cerebral artery aneurysm following removal of long-standing VPS, and Tubbs *et al.*^[20] reported another case of pericallosal artery pseudoaneurysm a complication of endoscopic insertion of a ventricular catheter during VPS procedure. The patient suffered massive intraventricular bleed, and aneurysm was diagnosed by angiography and treated by surgical trapping.

Srinivasan *et al.*^[21] described iatrogenic extracranial scalp pseudoaneurysm following retrosigmoid craniotomy presented with delayed postoperative hemorrhage. The aneurysm was treated successfully by coiling. They also described other treatment options of similar condition. On the other hand, Tambasco *et al.*^[22] reported giant occipital artery pseudoaneurysm near an extension channel of electrocatheter in a patient underwent insertion of deep brain stimulation. The aneurysm was treated by interventional embolization using acrylic glue. They believe the aneurysm resulted from trauma during tunneling, a mechanism, which is similar to our case. Given the rarity of traumatic aneurysm in the occipital artery, the authors felt this particular case report was indicative of alerting physicians when encounter occipital pulsatile swelling near to the path of VPS.

Conclusion

Traumatic occipital artery pseudoaneurysm is a rare complication of VPS procedure. Clinical findings and radiological imaging are always diagnostic. Large pseudoaneurysm close to shunt catheter may cause shunt malfunction. Surgical repair should be considered in such cases. This case report is aimed to increase awareness among physicians about this rare complication.

Declaration of patient consent

The authors certify that they have obtained all appropriate patient consent forms. In the form the patient(s) has/have given his/her/their consent for his/her/their images and other clinical information to be reported in the journal. The

patients understand that their names and initials will not be published and due efforts will be made to conceal their identity, but anonymity cannot be guaranteed.

Financial support and sponsorship

Nil.

Conflicts of interest

There are no conflicts of interest.

References

1. Agarwal N, Shukla RM, Agarwal D, Gupta K, Luthra R, Gupta J, *et al.* Pediatric ventriculoperitoneal shunts and their complications: An analysis. *J Indian Assoc Pediatr Surg* 2017;22:155-7.
2. Reddy GK, Bollam P, Caldito G. Long-term outcomes of ventriculoperitoneal shunt surgery in patients with hydrocephalus. *World Neurosurg* 2014;81:404-10.
3. Hanak BW, Bonow RH, Harris CA, Browd SR. Cerebrospinal fluid shunting complications in children. *Pediatr Neurosurg* 2017;52:381-400.
4. John N, Leach JL, Rachana T, Mangano FT. Traumatic aneurysm of the occipital artery secondary to paintball injury. *Clin Neurol Neurosurg* 2009;111:105-8.
5. Singh K, Singh A, Singh K, Bhalla V, Thukral CL. Post traumatic pseudoaneurysm of the occipital artery: A rare entity. *J Evol Med Dent Sci* 2013;2:6509-16.
6. Aquilina K, Carty F, Keohane C, Kaar GK. Pseudoaneurysm of the occipital artery: An unusual cause of persisting headache after minor head injury. *Ir Med J* 2005;98:215-7.
7. Skandalakis GP, Korfiatis S, Kalyvas AV, Anagnostopoulos C, Sakas DE. A giant pseudoaneurysm of the occipital artery. *Surg Neurol Int* 2017;8:281.
8. Patel M, Tchelepi H, Rice DH. Traumatic pseudoaneurysm of the occipital artery: Case report and review of the literature. *Ear Nose Throat J* 2008;87:E7-12.
9. Woods M, Moneley D. Occipital artery pseudoaneurysm: A rare complication of head trauma. *EJVES Extra* 2014;27:e34-5.
10. Boles DM, van Dellen JR, van den Heever CM, Lipschitz R. Traumatic aneurysms of the superficial temporal and occipital arteries: Case reports and review. *S Afr Med J* 1977;51:313-4.
11. Elgamal EA, Almotairi FS, Abdullah AM, Salih MA. Cerebrospinal fluid hydrothorax, an unusual complication of ventriculoperitoneal shunt. *J Pediatr Neurol* 2013;11:119-22.
12. Rao VY, Hwang SW, Adesina AM, Jea A. Thrombosed traumatic aneurysm of the occipital artery: A case report and review of the literature. *J Med Case Rep* 2012;6:203.
13. Chaudhry NS, Gaynor BG, Hussain S, Dembach PD, Aziz-Sultan MA. Etiology and treatment modalities of occipital artery aneurysms. *World Neurosurg* 2017;102:697.e1-697.e4.
14. Nagpal N, Bhargava GS, Singh B. Occipital artery pseudoaneurysm: A rare scalp swelling. *Indian J Surg* 2013;75:275-6.
15. Kim SK, Hwang SC, Kim BT. Usefulness of three-dimensional CT angiography as a confirmatory diagnostic test for scalp pseudoaneurysms. *Korean J Cerebrovasc Surg* 2010;12:87-90.
16. Yang HJ, Choi YH. Posttraumatic pseudoaneurysm in scalp treated by direct puncture embolization using N-butyl-2-cyanoacrylate: A case report. *Korean J Radiol* 2005;6:37-40.
17. Méndez JC, Sendra J, Poveda P, García-Leal R. Endovascular treatment of traumatic aneurysm of the occipital artery. *Cardiovasc Intervent Radiol* 2006;29:486-7.
18. Angevine PD, Connolly ES Jr. Pseudoaneurysms of the superficial temporal artery secondary to placement of external ventricular drainage catheters. *Surg Neurol* 2002;58:258-60.
19. Jenkinson MD, Basu S, Broome JC, Eldridge PR, Buxton N. Traumatic cerebral aneurysm formation following ventriculoperitoneal shunt insertion. *Childs Nerv Syst* 2006;22:193-6.
20. Tubbs RS, Acakpo-Satchivi L, Blount JP, Oakes WJ, Wellons JC 3rd. Pericallosal artery pseudoaneurysm secondary to endoscopic-assisted ventriculoperitoneal shunt placement. Case report. *J Neurosurg* 2006;105:140-2.
21. Srinivasan VM, Karas PJ, Sen AN, Fridley JS, Chen SR, Gopinath SP, *et al.* Occipital artery pseudoaneurysm after posterior fossa craniotomy. *World Neurosurg* 2017;98:868.e1-868.e4.
22. Tambasco N, Hamam M, Castrioto C, Calabresi P, Rossi A. Occipital pseudoaneurysm as a complication of extension channel placement for DBS in Parkinson's disease. *Mov Disord* 2007;22:1834-6.