

Primary Cutaneous Apocrine Carcinoma of the Scalp: A Rare Case Report

Abstract

Primary cutaneous apocrine carcinoma of the scalp is a rare adnexal sweat gland neoplasm. It is most commonly observed over eyelids and ear canals and is often confused with dermoid and epidermoid cysts, lipomas, cutaneous metastatic lesions, or basal cell carcinomas. We describe a 66-year-old male who presented with a midline scalp lesion. He was treated surgically with a wide local excision.

Keywords: Neck node dissection, palliative radiotherapy, primary cutaneous apocrine carcinoma, wide local excision

Introduction

Primary cutaneous apocrine carcinoma (PCAC) is a rare cutaneous malignancy with an incidence of 0.005–0.017/100,000 patients per year.^[1] While around 200 cases have been reported in the literature, commonly noted in areas such as the axilla, there have only been a few cases originating from the scalp.^[2,3]

Demographically, these malignancies have a Caucasian predominance with an equal distribution in both sexes. They commonly show a peak around the 6th and 7th decades of age, with a median age of 67 years, which was noted in the largest cohort studied to date.^[1]

Its presentation varies, where in it can occur as both uninodular and multinodular growths with varying colors.^[1,2] Reports have shown an infiltration of overlying epidermis. Clinically, these masses are indurated, painless, and may be associated with benign lesions such as nevus sebaceous.^[4]

As these lesions are vague in presentation and appearance, a good clinical evaluation and suspicion is required, as they are difficult to differentiate from metastatic skin lesions, especially from metastases of breast adenocarcinoma.^[1]

Among the past series of over 200 cases of PCAC, only few have a detailed description of scalp primaries.^[1] While some cases have

been reported to show longer durations with periods of rapid growth, it is observed that most of these lesions typically are eminent within a year before diagnosis.^[5,6]

Case Report

A 66-year-old male, a known case of coronary artery disease and hypertension, presented with a firm, nontender swelling over the parieto-occipital area of the scalp. It originated as a small swelling which increased in size over a period of 6 months [Figure 1]. He had no complaints of any headache or any neurological deficits.

His CT brain showed no calvarial involvement [Figure 2].

A wide local excision of the parieto-occipital lesion was done in the prone position under general anesthesia. A vertical elliptical incision was made around the lesion. The lesion was removed *en masse* along with underlying periosteum [Figure 3a-c].

Plastic surgery assistance intraoperatively was taken to create a large rotation advancement flap over the defect along with the placement of a split skin graft, harvested from the thigh [Figures 4 and 5].

Grossly, the pathology report was suggestive of a lesion with subcutaneous tissue measuring 11 cm × 7.5 cm × 4.5 cm. The skin surface showed a nodularity of around 2.5 cm diameter with an underlying tumor measuring 5 cm × 4 cm × 3 cm

Rohit Balasubramanian, Sheena Ali, Manohar A¹, Sangita S. Mehta²

Departments of Neurosurgery, ¹Plastic Surgery and ²Pathology, Kovai Medical Center and Hospital, Coimbatore, Tamil Nadu, India

Address for correspondence:

Dr. Sheena Ali,
Department of Neurosurgery
Kovai Medical Center and
Hospital, Coimbatore,
Tamil Nadu, India.
E-mail: dr.sheenaali90@gmail.com

Access this article online

Website: www.asianjns.org

DOI: 10.4103/ajns.AJNS_452_20

Quick Response Code:



How to cite this article: Balasubramanian R, Ali S, Manohar A, Mehta SS. Primary cutaneous apocrine carcinoma of the scalp: A rare case report. Asian J Neurosurg 2021;16:606-9.

Submitted: 30-Sep-2020

Revised: 20-Oct-2020

Accepted: 08-Apr-2021

Published: 07-Jun-2021

This is an open access journal, and articles are distributed under the terms of the Creative Commons Attribution-NonCommercial-ShareAlike 4.0 License, which allows others to remix, tweak, and build upon the work non-commercially, as long as appropriate credit is given and the new creations are licensed under the identical terms.

For reprints contact: WKHLRPMedknow_reprints@wolterskluwer.com

abutting the deep margin focally. The cut section was gray tan in color with areas of focal myxoid and hemorrhage.

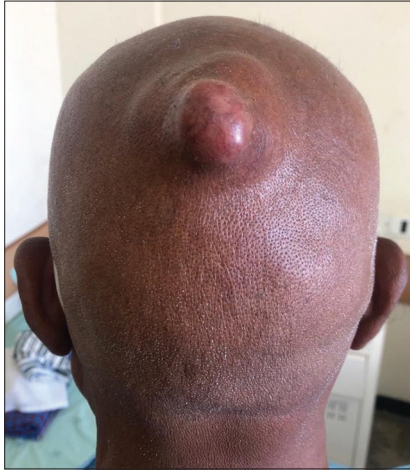

Figure 1: Gross appearance of the scalp lesion measuring 5 cm x 4 cm x 3 cm

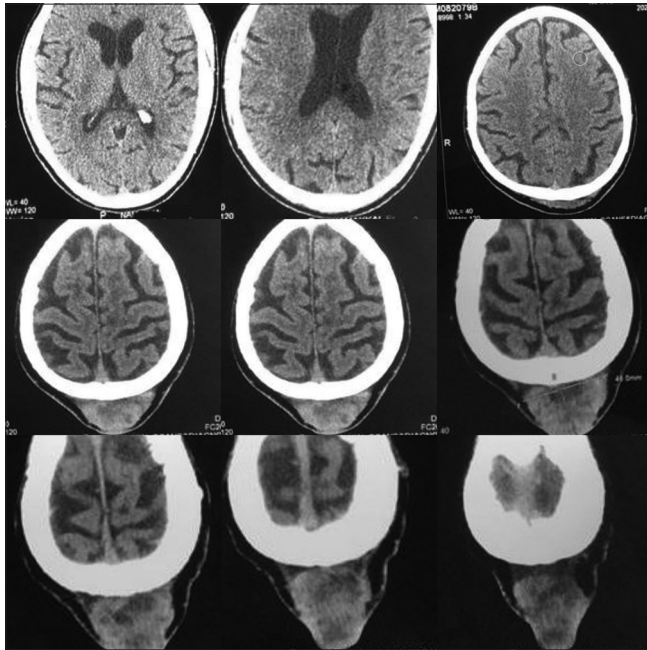


Figure 2: No intracranial extensions

Microscopically, the sections showed skin with underlying dermis and subcutis showing an unencapsulated lesion with jagged and pushing borders [Figure 6]. It was primarily composed of tubules with fusion, which were cribriforming. Some cells showed cystic dilation, intraforaminal foamy histiocytes with solid and papillary pattern of arrangement. These cells were lined with moderate to abundant eosinophilic granular to partly vacuolated cytoplasm. Patchy hemorrhagic, infarcted areas with foamy histiocytes were noted with no ulceration of overlying skin [Figure 7].

A high-resolution computed tomography (CT) of the chest showed no neck lymph nodes. A positron emission tomography CT done showed no evidence of any primaries or metabolically active lesions elsewhere in the body. He was advised a strict follow-up and explained the need for adjuvant radiotherapy.

Discussion

A literature review conducted via the PubMed engine in 2019 for patients with PCAC revealed 19 cases with detailed reports regarding the clinical presentation, treatment methods, and prognosis of the disease.^[1] The study cohort included 11 (57.9%) females and 8 (42.1%) males with a mean age of 57 years. The average size was variable with an average of 3.1 cm. 12/19 (63.2%) patients were presented with the only local cutaneous disease. 3/19 (15.8%) patients were presented with cervical lymphadenopathy at the time of diagnosis.

While metastatic disease was not present at the time of diagnosis in any of the reported cases, the average size of the metastatic lesions was higher than the average size of nonmetastatic lesions. Common sites of distant metastasis occurred in the distant lymph nodes, the bones, the brain, and the lungs.

Surgical excision (local complete vs. wide or radical) was the primary treatment done in 18/19 (94.7%) patients in that study.

Local recurrences without positive regional lymph nodes, primary treatment was wide excision of the tumor. Neck dissection, radiation, or both were the treatment in

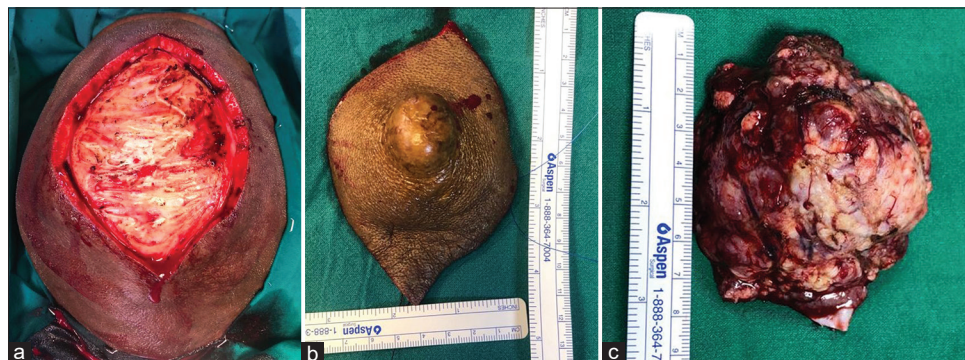

Figure 3: (a) No intracranial extensions. (b) Gross section of the lesion showing the overlying skin and undersurface of the tumor. (c) Gross section of the lesion showing the overlying skin and undersurface of the tumor

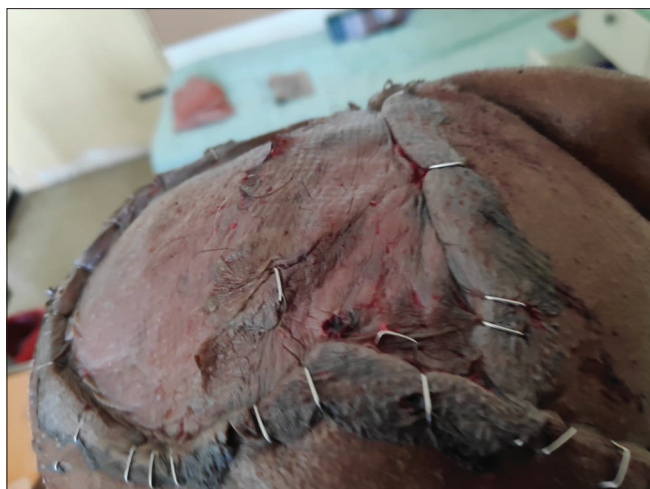

Figure 4: Advancement rotation flap of the skin defect with split skin graft

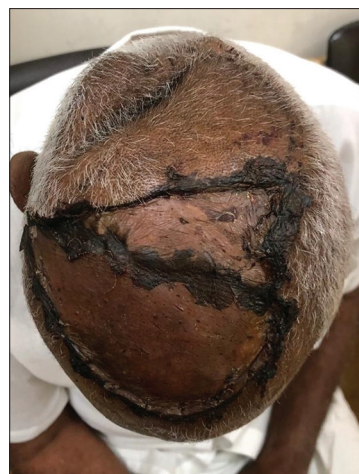

Figure 5: Postoperative wound showing good healing

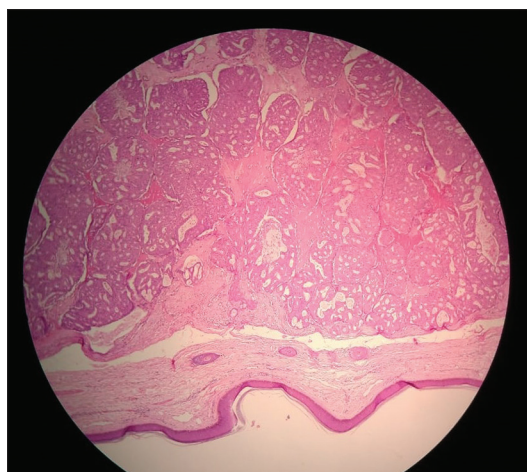


Figure 6: Underlying dermis and subcutis showing an unencapsulated SOL with jagged and pushing borders

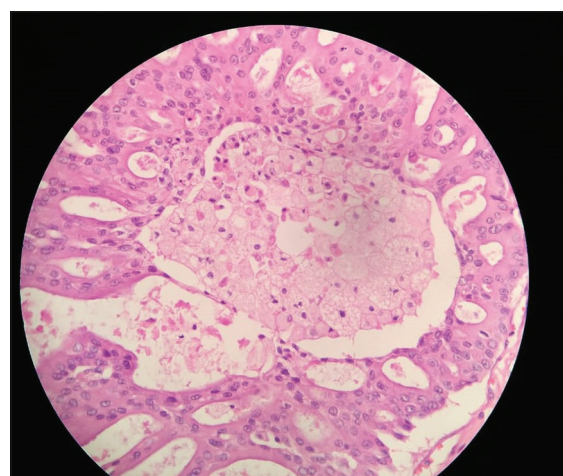


Figure 7: Presence of foamy histiocytes with papillary arrangement

cases of positive regional lymph node metastasis. Those with metastatic disease, palliative chemotherapy and/or radiotherapy was the treatment done.

From the time of metastatic diagnosis, survival ranged from approximately 1–4 years, with an average of 2.25 years.^[1,2,3,7,8,9]

The data suggested that the size of the primary at initial presentation was directly proportional to a poor prognosis, with a higher tendency to metastasize; prognosis is often fatal upon the evidence of metastatic disease.^[1]

Our case had no distant metastasis at presentation. As histopathology revealed negative wide margins on all sites, except a 1 mm margin on the deeper aspect, adjuvant radiotherapy was advised.

The current consensus suggests the use of wide surgical resection; however, due to insufficient data, surgical margins have not been standardized so far and 1–2 cm may provide sufficient eradication of tumor cells. Lesions exceeding 5 cm, the use of adjuvant radiation in the treatment protocol is said to improve survival rates.^[10,11]

In node-negative cases, there is no need for a neck dissection. Neck dissection followed by adjuvant radiotherapy was offered to the patient presented with cervical lymph node metastasis.

Sentinel lymph node biopsy (SLNB) was suggested by Hallowell,^[1] but due to the low incidence rate of PCAC, SLNB has not undergone prospective evaluation. Due to the low incidence of PCAC, individualized treatment should be addressed. Chemotherapy should be reserved for treating the advanced disease that often proves to be fatal and the initiation of palliative care in these circumstances is inevitable.^[3]

Our patient remains disease free after 2 months of surgery, consistent with literature.

Conclusion

Following an in-depth assessment of the literature on PCAC, it can be concluded that the recommendation for surgical removal with cleared margins seems to be appropriate among patients with local, node-negative disease. Good surgical clearance with wide margins of

1–2 centimeters is considered the accepted standard. However, there has been no evidence available currently, to show the benefit of adjuvant treatment for PCAC. The use of chemotherapy and radiotherapy may also be considered in patients with advanced and distant disease, as well as chronic recurrence, but should be decided on a case-to-case basis.

Declaration of patient consent

The authors certify that they have obtained all appropriate patient consent forms. In the form the patient(s) has/have given his/her/their consent for his/her/their images and other clinical information to be reported in the journal. The patients understand that their names and initials will not be published and due efforts will be made to conceal their identity, but anonymity cannot be guaranteed.

Financial support and sponsorship

Nil.

Conflicts of interest

There are no conflicts of interest.

References

- Hollowell KL, Agle SC, Zervos EE, Fitzgerald TL. Cutaneous apocrine adenocarcinoma: Defining epidemiology, outcomes, and optimal therapy for a rare neoplasm. *J Surg Oncol* 2012;105:415-9.
- Morabito A, Bevilacqua P, Vitale S, Fanelli M, Gattuso D, Gasparini G. Clinical management of a case of recurrent apocrine gland carcinoma of the scalp: Efficacy of a chemotherapy schedule with methotrexate and bleomycin. *Tumori* 2000;86:472-4.
- Vucinić I, Stojadinović T, Mikez ZB, Danić D, Coha B. Apocrine carcinoma of the scalp with aggressive clinical course – A case report and review of the literature. *Coll Antropol* 2012;36 Suppl 2:209-12.
- Fernandez-Flores A. The elusive differential diagnosis of cutaneous apocrine adenocarcinoma vs. metastasis: The current role of clinical correlation. *Acta Dermatovenerol Alp Pannonica Adriat* 2009;18:141-2.
- Domingo J, Helwig EB. Malignant neoplasms associated with nevus sebaceus of Jadassohn. *J Am Acad Dermatol* 1979;1:545-56.
- Miyamoto T, Hagari Y, Inoue S, Watanabe T, Yoshino T. Axillary apocrine carcinoma with benign apocrine tumours: A case report involving a pathological and immunohistochemical study and review of the literature. *J Clin Pathol* 2005;58:757-61.
- Vasilakaki T, Skafida E, Moustou E, Grammatoglou X, Arkoumani E, Koulia K, *et al.* Primary cutaneous apocrine carcinoma of sweat glands: A rare case report. *Case Rep Oncol* 2011;4:597-601.
- Paties C, Taccagni GL, Papotti M, Valente G, Zangrandi A, Aloï F. Apocrine carcinoma of the skin. A clinicopathologic, immunocytochemical, and ultrastructural study. *Cancer* 1993;71:375-81.
- Tlemcani K, Levine D, Smith RV, Brandwein-Gensler M, Staffenberg DA, Garg MK, *et al.* Metastatic apocrine carcinoma of the scalp: Prolonged response to systemic chemotherapy. *J Clin Oncol* 2010;28:e412-4.
- Paudel U, Jha A, Pokhrel DB, Gurung D, Parajuli S, Pant A. Apocrine carcinoma developing in a naevus sebaceous of scalp. *Kathmandu Univ Med J (KUMJ)* 2012;10:103-5.
- Jacyk WK, Requena L, Sánchez Yus E, Judd MJ. Tubular apocrine carcinoma arising in a nevus sebaceus of Jadassohn. *Am J Dermatopathol* 1998;20:389-92.
- Shimato S, Wakabayashi T, Mizuno M, Nakahara N, Hatano H, Natsume A, *et al.* Brain metastases from apocrine carcinoma of the scalp: Case report. *J Neurooncol* 2006;77:285-9.