

Methylmethacrylate Inter-Facet and Inter-Vertebral Body Spacers for Cranio-Vertebral Junction and Various Spine Surgeries: Technical Note

Abstract

Study Design: Prospective. **Purpose:** Over past one and half decade, ready-to-use magnetic resonance imaging (MRI) compatible spinal implants have changed the clinical practice and economics of spinal surgery. These are beyond reach of majority of population of developing countries like India due to financial reasons and also availability in remote areas. There is a growing need for a MRI compatible cost-effective spinal implant of proven quality. The authors used bone cement spacers for the said purpose for various level spine surgeries. **Overview of Literature:** Methylmethacrylate, known as bone cement, was used extensively for spinal surgeries from craniovertebral junction to sacrum for augmentation and replacement of various spinal elements. Its biochemical and biomechanical properties were tested for safe clinical use and was a favored material for spinal surgeons. **Materials and Methods:** The authors made molds for making bone cement spacers for various spine levels with the help of silicone material. **Results:** Sixteen patients (12 males, 4 females with an average age of 31 years) of various spine level surgeries were done where bone cement spacers were used. It included patients of basilar invagination ($n = 9$), dorsal Pott's disease ($n = 1$), lumbar ($n = 2$), and lumbo-sacral spondylolisthesis ($n = 1$). Spacers could be used without any difficulties and postoperative day 1- and 3-months follow-up computed tomography scan of the patients revealed no change in the dimensions of the spacer and fusion at 3 months of operated levels. **Conclusion:** The authors feel that bone cement spacers may be an effective and low-cost alternative to the existing costly alternatives.

Keywords: Bone cement, cranio-vertebral junction, intervertebral spacer, methylmethacrylate, spacer

Introduction

Methylmethacrylate (MMA), also known as “Bone Cement,” has been used in neurosurgery for cranioplasty and spine surgeries since 1940s and 1970s, respectively.^[1,2] Bone cement is polymerized MMA monomers, converted to polymethylmethacrylate polymers by a liquid (MMA monomer, stabilizer, inhibitor). However, its use in spine surgeries gradually disappeared by the beginning of this century except in vertebroplasty. Currently, in neurosurgery, it is being used around the world for cranioplasty and vertebroplasty/kyphoplasty.^[3] The basic reason for its waning use in spine surgeries is the progressive and incremental introduction of a variety of magnetic resonance imaging (MRI) compatible spinal implants/prostheses made of titanium and polyether ether ketone (PEEK).^[4]

These implants/prostheses are readymade and are of different sizes, unlike bone cement prosthesis, which the surgeon has to prepare manually during surgery, and which might not be of the ideal shape or size. The global spinal implants market is approximately \$12 billion and is growing annually at a rate of 5%–6%.^[4,5] A better understanding of spinal fusion after fixation highlights the use of bone grafts in addition to prosthetic implants for better outcomes. Despite proven physical, chemical, and biomechanical properties in anterior as well as posterior spinal augmentation and inter-vertebral disc replacement surgeries, bone cement is rarely used in spine surgeries except for vertebroplasty/kyphoplasty and occasionally, for pedicle screw augmentation purposes. The cost of bone cement is significantly lower than

Deepak Kumar Jha,
Mayank Garg,
Suryanarayanan
Bhaskar,
Jaskaran Singh
Gosal,
Kartikeya Shukla,
Vinay Kumar
Chugh¹,
Pushpinder Khera²,
Pradeep Kumar
Bhatia³

Departments of Neurosurgery,
¹Dentistry, ²Diagnostic and
Interventional Radiology and
³Anaesthesiology and Critical
Care, All India Institute of
Medical Sciences, Jodhpur,
Rajasthan, India

Address for correspondence:

Dr. Deepak Kumar Jha,
Department of Neurosurgery,
All India Institute of Medical
Sciences, Jodhpur - 342 005,
Rajasthan, India.
E-mail: drdeepakjha@gmail.com

Access this article online

Website: www.asianjns.org

DOI: 10.4103/ajns.AJNS_443_20

Quick Response Code:



How to cite this article: Jha DK, Garg M, Bhaskar S, Gosal JS, Shukla K, Chugh VK, *et al.* Methylmethacrylate inter-facet and inter-vertebral body spacers for cranio-vertebral junction and various spine surgeries: Technical note. *Asian J Neurosurg* 2021;16:648-54.

Submitted: 23-Sep-2020

Revised: 14-Feb-2021

Accepted: 13-Mar-2021

Published: 14-Sep-2021

This is an open access journal, and articles are distributed under the terms of the Creative Commons Attribution-NonCommercial-ShareAlike 4.0 License, which allows others to remix, tweak, and build upon the work non-commercially, as long as appropriate credit is given and the new creations are licensed under the identical terms.

For reprints contact: WKHLRPMedknow_reprints@wolterskluwer.com

the available alternatives.^[6-8] The authors present their experience of using bone cement spacers, made by silicone material molds of different sizes and shapes, to be used for craniovertebral junction (CVJ), cervical and lumbar/lumbo-sacral, fusion, and fixation surgeries.

Materials and Methods

Study design

Prospective, as an intramural project. The duration of the study was 2 years (July 2018–July 2020). Institutional ethical clearance was given for the study.

Inclusion criteria

- Patients undergoing spine surgeries, who need prosthetic spacer/s in inter-facet joint/s or inter-vertebral space/s, with or without distraction (in addition to fusion and fixation).

Exclusion criteria

- Clinical, radiological, or laboratory evidence of infection of the spine segments to be operated, except tuberculosis of spine
- Patients/relatives not giving consent for use of bone cement spacers in their surgery.

Written informed consents were taken from the patient/guardian/relatives.

The clinico-radiological findings were recorded. Imaging studies such as computed tomography (CT) and MRI scans were used to evaluate the spinal elements of interest, in patients who were likely to need spacers for facet or inter-vertebral disc-space distractions for CVJ or spine surgeries. The gross dimensions (length, breadth, and height) of the spacers were ascertained preoperatively, based on CT and MRI findings, during surgical planning.

Based on CT and MR imaging studies, approximate dimensions of the molds were ascertained for making the bone cement spacers during surgery.

Methodology of preparation of bone cement spacer

A hard plastic board was used to make the models of the spacers of desired sizes for CVJ, cervical, and dorsal/lumbar/lumbosacral spines. The finishing of its shape was done by cutting, scraping, filing, and grinding. The dimensions of the spacer models for various levels were as follows [Figure 1]:

- For CVJ: 12 mm × 10 mm × 5 mm, 12 mm × 10 mm × 7 mm and 12 mm × 10 mm × 9 mm [Figure 1, black arrow]
- For cervical spine: 15 mm × 12 mm × 5 mm, 15 mm × 12 mm × 7 mm, and 15 mm × 12 mm × 9 mm [Figure 1, red arrow]
- For dorsal/lumbar/lumbosacral spines: 18 mm × 12 mm × 9 mm, 18 mm × 12 mm × 11 mm,




Figure 1: Shows plastic designs/models of spacers for craniovertebral junction (black arrow), Cervical Spine (red arrow) and Lumbar and Lumbo-sacral Spine (yellow arrow)

and 18 mm × 12 mm × 13 mm [Figure 1, yellow arrow].

The molds for spacers were made by silicone material (Aquasil Soft Putty, Dentsply, India) used by the department of dentistry for making dental implants [Figure 2]. The required amount of the silicone material was taken and mixed, according to the manufacturer's instructions. The mixing time of the silicone material is 30 s, and the final setting time is 4 min 30 s. The silicone material in the setting stage was roughly shaped in the form of a cuboid 12 cm long, 3 cm wide, and 1.5 cm in height. The *plastic spacer* designs/models were embedded in the silicone material in the setting stage and were left as such until it was completely set [Figure 2a]. The spacer models/designs were then removed from the silicone material carefully, and the silicone molds were, thus, obtained for use after cleaning and subjecting to plasma sterilization [Figure 2b].

Properties of silicone material

Flexibility

The flexibility of silicone material molds aids in the easy removal of the plastic models embedded within the material.

Elastic recovery

The silicone material retains its shape even after minor distortions during handling.

Tear strength

Good tear strength of the silicone material allows it to resist tear during distortion.

Dimensional stability

The silicone material does not show any polymerization shrinkage or other distortions and is thus considered to be a dimension-stable material.^[9]

Sterilization

The silicone material can be sterilised using plasma sterilization or autoclave (134°C for 18 min).^[10]

- Other uses: The silicone material can be used in other medical specialities as well. The novel prosthetic vaginal dilator was prepared using silicone material for maintaining the patency of neo vagina after vaginoplasty in a 21-year-old patient.^[11]

Cost factors for mould preparation

One silicone material set (Aquasil Soft Putty, Dentsply, India) including both, the Base paste and the catalyst paste, costs around 3000 INR (approximately 40 USD). Approximately 8–10 moulds with dimensions of 12 cm length, 3 cm width, and 1.5 cm height can be prepared from one silicone material set. Thus, one silicone material mould of desired dimensions (12 cm long, 3 cm wide, and 1.5 cm in height) costs just around 300 INR (approximately 4 USD).

The moulds were tested by using them for making bone cement spacers [Figure 3a]. It was easy to remove the bone cement spacers from the moulds, after 12–15 min (setting time of bone cement used, *Surgical Simplex®P*, Stryker, Limerick, Ireland) of reconstitution of the mixture of powder and the liquid of bone cement pack. There was

no change in the shape, elasticity, and strength of the molds, during and after the formation of the bone cement spacers [Figure 3b]. They were subjected to 25 rounds of plasma sterilization and yet maintained their shape, size, and pliability. It was possible to modify the dimensions of the bone cement spacers by using bone nibblers, Kerrison's punch, and high-speed drill [Figure 3c]. The design of the mold/s could be changed, if required, to facilitate using it flawlessly for making the spacers during surgery as per the surgeon/s requirement. The spacers can be made before or during the surgery and minor modifications may be done by the surgeon at the time of surgery [Figure 4a and b]. The authors made a hole of 3–5 mm with the help of high speed drill, in the spacers, once their size/shape was finalized after necessary modifications. The hole was filled with autograft bone pieces for better fusion [Figure 5]. These autograft-filled bone cement spacers were inserted in the joint spaces during various spine surgeries.

The outcomes were measured by CT scan studies on the postoperative day 1 and at 3 and 6 months follow-up [Figure 4]. The height of the bone cement spacer on the postoperative day 1 was compared with that in the follow-up scans at 3 and 6 months [Figure 4g-i]. The clinical status (improved, unchanged, or deteriorated) in the follow-up was recorded. If any preoperative symptom persisted or a new symptom/sign appeared, its association to the spacer or implant was analyzed. Follow-up protocol included 6 monthly visits for 5 years and annual visits for the next 5 years.

Result

Patient characteristics

Sixteen patients, which included 12 males and 4 females, age ranging from 12 to 67 years (average age 31 years), were included in the study [Table 1]. Diagnoses included patients suffering from basilar invagination ($n = 9$), cervical disc protrusions ($n = 3$), dorsal spine (D2) potts disease ($n = 1$), and lumbar ($n = 2$) and lumbo-sacral spondylolisthesis ($n = 1$) [Table 1]. Various clinical characteristics are shown in table, which include CVJ pathologies with quadriplegia, with ($n = 3$) or without ($n = 6$) respiratory involvements. Two patients of BI ($n = 9$) had




Figure 2: Show Silicon (a) with embedded plastic designs/models of spacers (black arrow). Moulds prepared of Silicon (b) showing cavities in silicone mould (black arrow in b)

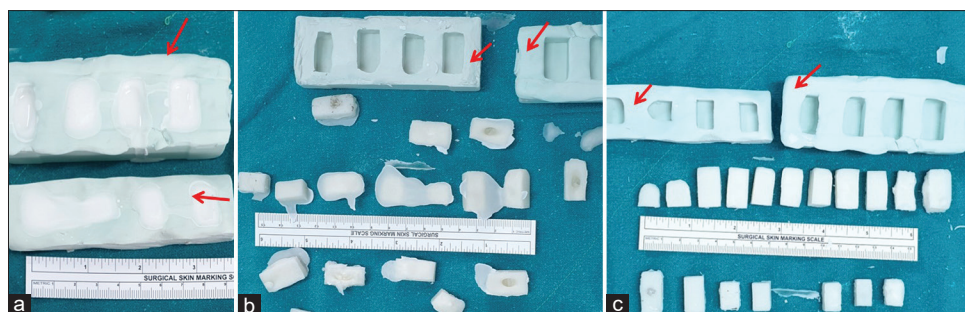


Figure 3: Shows silicone mould (red arrows) filled up with bone cement (a). Bone cement spacers removed from the moulds (b) and after removal of spilled over bone cement (c) by instruments like nibbler

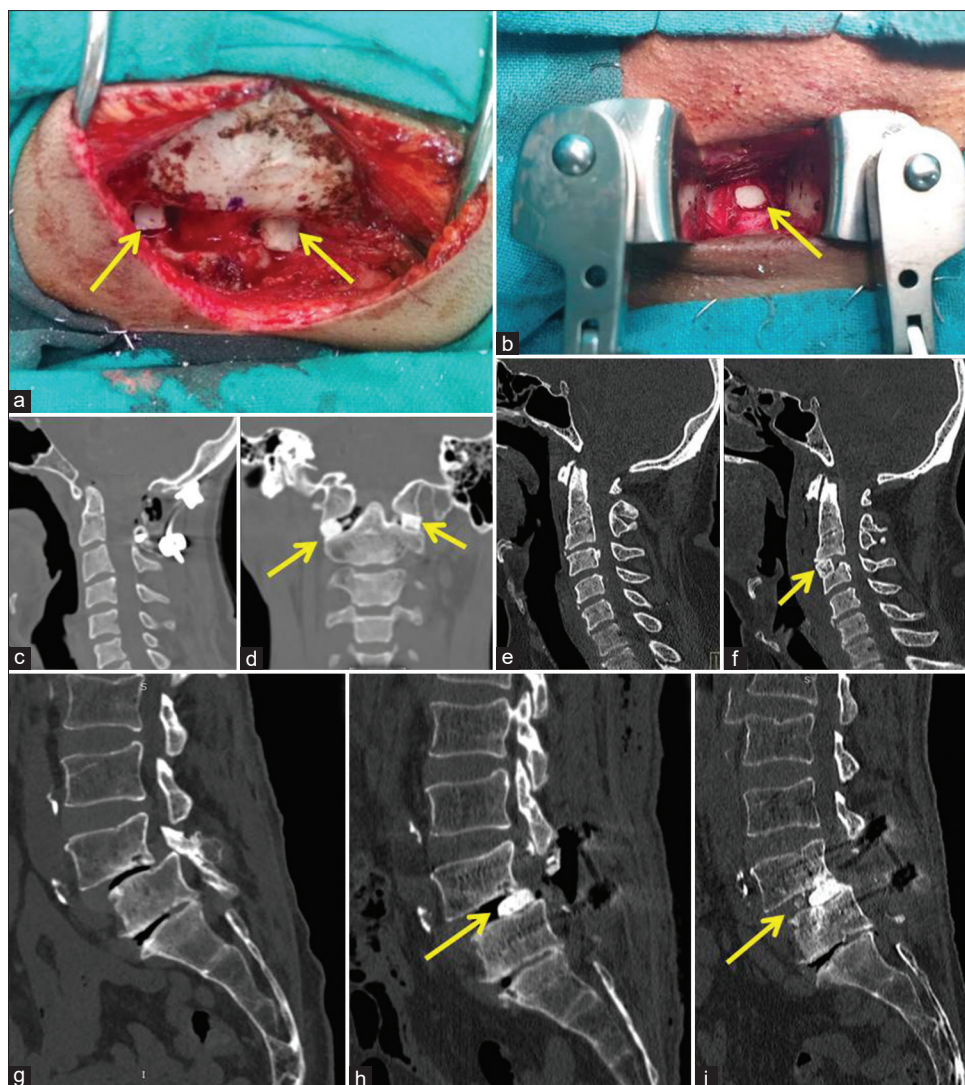


Figure 4: Shows bone cement spacers (yellow arrow) inserted in bilateral C1-2 facet joints (a) and C3-4 disc space after Discectomy (b). Postoperative day 1 computed tomography scans, bone windows of craniovertebral junction, midline sagittal (c) and coronal (d) and cervical spine, midline sagittal pre-operative (e) and postoperative (f) images show spacers (yellow arrow). Preoperative (g), postoperative day 1 (h) and 3-months follow up (i) midline sagittal bone window computed tomography scan images show spacer (yellow arrow) with maintained distraction of L4-5 in an operated patient of L4-5 Spondylolisthesis

lower cranial nerve involvements. Cervical spine patients had radiculopathies with distal motor and sensory deficits, while one patient with Pott's disease of D2 spine, presented with paraplegia with bladder/bowel involvements. The patients with lumbar and lumbo-sacral spondylolistheses had low back pain with radiculopathies and distal motor and sensory weakness.

In most of the CVJ and cervical spine surgeries, the spacer heights were approximately 7 mm [Figure 4a-f]. The spacer was made manually in the patient with Pott's disease of the dorsal spine and had a height of 12 mm with length and breadth of 26 mm and 15 mm, respectively. The spacer dimension was ascertained as per the available space after unilateral trans-pedicular decompression and minimal distraction of D1-3. In lumbar and lumbo-sacral spine surgeries, the average spacer dimensions were 18 mm × 12 mm × 8 mm [Figure 4g-i].

The average follow-up period was 20.7 months (range: 3–26 months).

Postoperative day 1 and 3-months' follow-up CT scans revealed no change in spacer height and its position [Figure 4h and i]. There was no infection or other spacer-related complication in any of the patients.

Discussion

Health-care infrastructure in India is insufficient to take care of the population at large.^[11-16] Recent studies have shown that the majority of our population (80%–85%) depend on free health-care facilities provided by the public sector hospitals.^[14-16] Over the last two decades, advancements in techniques and technologies in neurosurgery have changed the outlook of treatments and results of neurological diseases; unfortunately,

these are quite expensive and available at only a few public sector hospitals or institutes.^[11,12] If we consider the neurosurgical services in particular, approximately 90 government medical colleges have functional neurosurgical departments. Out of these, only about 15 government medical colleges/institutes have the facilities for advanced neurosurgical procedures.^[7]

Origin of the idea

- The authors believe that bone cement spacers, despite being safe, MRI compatible and cost-effective, are not being used in spine surgeries
- Unavailability of readymade bone cement spacers for spine surgeries is the likely cause, because making it manually may not be feasible for many surgeons due to the time taken (10–15 min) and in some cases, the inability to do it precisely
- High cost of the currently available MRI compatible spacers (both Indian and imported)
- Lack of availability of readymade spacers (both Indian and imported) used in spine surgeries in smaller cities.

Rationale of the proposal of alternative implant to be used for spine surgeries

MRI compatible spinal implants are made up of titanium or PEEK and are available for a variety of applications and are convenient for surgeons, as they are ready to use.^[4] However, large sections of population of developing countries like India cannot afford these due to financial constraints. The average unit cost of such implants is more than 350–1000 USD.^[4,17] In addition to being nonmagnetic (MRI compatible), bone cement is an established material for clinical use and has been found effective for the purpose of spinal column augmentation/support for all spine segments (CVJ, cervical, dorsal, lumbar, and lumbo-sacral) and columns (anterior, lateral, and posterior).^[1-7] The cost of 40 g of bone cement, which is more than sufficient for most of the spinal surgery

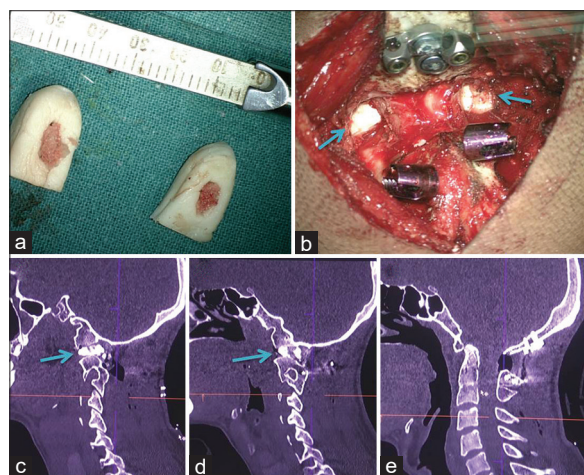


Figure 5: Shows bone cement spacers with filled up pieces of harvested auto-graft bone in the central hole of the spacers (a), Operative photo of bone cement spacers (arrows) inserted between bilateral C1-2 lateral masses (Facets) for distraction along with Occipital plate and C2 Laminar screws inserted (b), Postoperative day-1 noncontrast computed tomography scan, right (c) and left (d) para-sagittal views showing C1-2 lateral mass spacers (arrows) with bone graft and midline sagittal view (e) showing normal alignment of craniovertebral junction

Table 1: Clinical characteristics, diagnosis, relevant signs/symptoms, surgeries done and dimensions of bone cement spacers used.

Age (years)	Sex	Diagnosis	Clinical symptoms	Surgery	Spacer dimensions (L×B × H mm)
22	Female	BI	Quadripareisis	DCER	12×10×7
27	Male	BI	Quadripareisis	DCER	12×10×7
14	Female	BI	Quadripareisis with RI	DCER	12×10×7
30	Male	C3-4 PIVD	Quadripareisis	ACDF	15×12×7
56	Male	L4-5 listhesis	LBA	L4-5 PLIF	18×12×9
34	Male	C5-6 PIVD	Radicular pain with numbness	ACDF	15×12×7
67	Male	L4-5 listhesis	Radicular pain with numbness	L4-5 PLIF	18×12×8
45	Female	BI	Quadripareisis	DCER	12×10×8
17	Male	BI	Radicular pain with numbness	DCER	12×10×8
14	Male	BI	Quadripareisis with RI and LCN	DCER+TOO	12×10×9
60	Female	BI	Quadripareisis	DCER	12×10×7
14	Male	BI	Quadripareisis	DCER	12×10×6
14	Male	BI	Quadripareisis with RI and LCN	DCER	12×10×7
12*	Male	D2 potts spine	Paraplegia with BB	D2 Left TPD with FF	26×15×12
17	Male	L5-S1 listhesis	LBA	L5-S1 Listhesis	18×12×8
58	Male	C3-4 PIVD	Quadripareisis	ACDF	15×12×7

*Bone cement spacer was made manually. L - Length; B - Breadth; H - Height; BI - Basilar invagination; DCER - Occiput-C2 distraction, compression, extension and reduction by C1-2 facet joint spacers with fusion and fixation of occiput-C2 by autograft and titanium occipital plates and C2 laminar screws; PIVD - Prolapsed intervertebral disc; PLIF: Posterior lumbar inter-vertebral body fixation; TOO - Trans-oral odontoidectomy; RI - Respiratory involvement; BB - Bladder/bowel involvement; LCN - Lower cranial nerve palsy; TPD - Trans-pedicular decompression; FF - Fusion and fixation by autograft and titanium screws and rods; LBA - Low backache; ACDF - Anterior Cervical Discectomy with Fusion

procedures, is approximately 35–50 USD. Merely providing a mold which can be used by the surgeons to make bone cement prosthesis for a variety of spine surgeries, can be an effective way to fill up the gap between availability of a cost-effective, scientifically proven prosthetic material and its use as spacers in spine surgery.^[2,3,8,18] It is also to be highlighted that the bone cement spacers need not be of accurate shape and size, because minor or even major, modifications can be done in their shape and size using basic instruments as per the requirements.

International status

Bone cement is being used for spine augmentation procedures such as vertebroplasty/kyphoplasty and augmenting pedicle screw purchase in selected cases like osteoporosis.^[11] The spinal implant market has become very competitive and fierce, and it is generally felt that there is a greater interest from the industry in promoting spinal instrumentation, resulting in their greater usage by spinal surgeons. Statistics has proven that such an attitude on the part of the industry has led to an over-usage of many spinal implants.^[19] The ties between Spinal Surgeons and the Industry, at times, create a conflict of interest, with the professional judgments getting unduly influenced by secondary interests.^[4]

National status

The high cost of MRI compatible implants has led to mushrooming of low-cost implant manufacturers without adequate quality certification and effective regulation.^[4,17]

Senior author (DKJ) used hard plastic board for making designs/models of spacers, but it can be made using any hard material like wood, metal, hardened clay or putty. The silicone mould does not stick to the spacer designs/models made up, either of plastic or of bone cement, after it sets/hardens. Moulds, once made, are thoroughly cleaned and plasma sterilized before using them for making bone cement spacers. No difficulty was encountered while removing the spacers from the silicone moulds.

Ready-made implants, require the surgeon to create room into the joint space, according to their size and shapes of the spacers, whereas the bone cement spacers can be tailored according to the patients' joint space.^[20] It precludes the creation of a space in the joint, using the available space instead. By minimising the drilling of the joint space, it also protects the patients from surgical complications, especially in CVJ and cervical spine surgeries. The time taken for the setting of bone cement, which is a concern for many surgeons, can be taken care of by preoperative planning based on CT findings. In case of some difficulty, preparing the spacer during the surgery, is always an option, which was done in a patient with Pott's disease of the dorsal spine, in our study. In all our cases, there was no complication due to bone cement

spacer and postoperative day 1 and 3 months' follow-up CT scans did not show any change in the dimensions or positions of the spacers. None of the patients complained of any symptom, after surgery, which could be attributed to the bone cement spacers.

Conclusion

We conclude that bone cement spacers may be an efficient, radio-opaque, MRI compatible and cost-effective alternative to a variety of spinal implants used as disc replacement material or spacers in spine surgeries. It is simple to make, can be made manually as well as by using moulds and are available easily. The ability to modify the bone cement spacers, instead of surgical modification of the space, where the spacers are to be inserted, makes the surgery safer.

Financial support and sponsorship

This study was financially supported by Intramural project being done with support of AIIMS Jodhpur (Ethical clearance Certificate Reference Number: AIIMS/IEC/2019-20/873).

Conflicts of interest

There are no conflicts of interest.

References

1. Bone Cement. Available from: https://en.wikipedia.org/w/index.php?title=Bone_cement&oldid=860258446. [Last accessed on 2020 Sep 13].
2. Bowers KD Jr., Thrasher EL. The use of methylmethacrylate for extensive internal bracing of the cervical spine in metastatic disease. (A case report). *W V Med J* 1974;70:106-8.
3. Chandra Vemula VR, Prasad BC, Jagadeesh MA, Vuttarkar J, Akula SK. Minimally invasive transforaminal lumbar interbody fusion using bone cement-augmented pedicle screws for lumbar spondylolisthesis in patients with osteoporosis. Case series and review of literature. *Neurol India* 2018;66:118-25.
4. Ramani PS. Spinal surgeon, implant industry and patient care: Where do we draw the line! *Neurol India* 2016;64:368-71.
5. Spinal Implants & Devices Market Size, Share & Trends Analysis Report By Product (Fusion Devices, Spinal Biologics), By Technology, By Surgery Type, By Procedure Type, And Segment Forecasts, 2018 – 2024. Available from: <https://www.grandviewresearch.com/industry-analysis/spinal-implants-spinal-devices-market>. [Last accessed on 2020 Sep 13].
6. Tomita S, Molloy S, Jasper LE, Abe M, Belkoff SM. Biomechanical comparison of kyphoplasty with different bone cements. *Spine (Phila Pa 1976)* 2004;29:1203-7.
7. Belkoff SM, Mathis JM, Erbe EM, Fenton DC. Biomechanical evaluation of a new bone cement for use in vertebroplasty. *Spine (Phila Pa 1976)* 2000;25:1061-4.
8. Singh K, Vaccaro AR, Kim J, Lorenz EP, Lim TH, An HS. Biomechanical comparison of cervical spine reconstructive techniques after a multilevel corpectomy of the cervical spine. *Spine (Phila Pa 1976)* 2003;28:2352-8.
9. Donovan TE, Chee WW. A review of contemporary impression materials and techniques. *Dent Clin North Am* 2004;48:vi-vii, 445-70.

10. Kotha SB, Ramakrishnaiah R, Devang Divakar D, Celur SL, Qasim S, Matinlinna JP. Effect of disinfection and sterilization on the tensile strength, surface roughness, and wettability of elastomers. *J Investig Clin Dent* 2017;8:e12244. DOI: 10.1111/jicd.12244. Epub 2016 Oct 26.
11. Ganapathy K. Neurosurgery in India: An overview. *World Neurosurg* 2013;79:621-8.
12. Nadkarni TD, Goel A, Pandya SK. Neurosurgery in India. *J Postgrad Med* 2002;48:332-5.
13. Rural Health Statistics in India. Statistics Division, Ministry of Health and Family Welfare, Government of India; 2012. Available from: https://main.mohfw.gov.in/sites/default/files/Final%20RHS%202018-19_0.pdf. [Last accessed on 2020 Sep 13].
14. Rao GM, Choudhary M. Health Care Financing Reforms in India. Available from: https://www.nipfp.org.in/media/medialibrary/2013/04/wp_2012_100.pdf. [Last accessed on 2020 Sep 13].
15. Reddy KS, Patel V, Jha P, Paul VK, Kumar AK, Dandona L. Towards Achievement of Universal Health Care in India by 2020: A Call to Action. Published Online: January 11, 2011. Available from: [https://www.thelancet.com/journals/lancet/article/PIIS0140-6736\(10\)61960-5/fulltext](https://www.thelancet.com/journals/lancet/article/PIIS0140-6736(10)61960-5/fulltext). [Last accessed on 2020 Sep 13].
16. Gudwani A, Mitra P, Puri A, Vaidya M. India Healthcare: Inspiring Possibilities, Challenging Journey. Prepared for Confederation of Indian Industry (CII). December, 2012. Available from: https://www.mckinsey.com/~media/McKinsey/Featured%20Insights/India/India%20Healthcare%20Inspiring%20possibilities%20challenging%20journey/India%20Healthcare_Inspiring%20Possibilities_Challenging%20Journey.ashx. [Last accessed on 2020 Sep 13].
17. Rawall S, Mohan K, Nagad P, Sabnis A, Pawar U, Nene A. Role of 'low cost Indian implants' in our practice: Our experience with 1,572 pedicle screws. *Eur Spine J* 2011;20:1607-12.
18. Material Safety Data Sheet. Product Name: Surgical Simplex® P Radiopaque Bone Cement. Available from: <https://www.strykermeded.com/media/1982/surgical-simplex-p-radiopaque-bone-cement-msds.pdf>. [Last accessed on 2020 Sep 13].
19. Chandra PS, Prabhu M, Goyal N, Garg A, Chauhan A, Sharma BS. Distraction, compression, extension, and reduction combined with joint remodeling and extra-articular distraction: Description of 2 new modifications for its application in basilar invagination and atlantoaxial dislocation: Prospective study in 79 cases. *Neurosurgery* 2015;77:67-80.