Article published online: 2022-08-16

Case Report

Isolated Thoracic Spine Intramedullary Metastasis from Primary Ovarian Carcinoma: A Rare Case Report

Abstract

Ovarian carcinoma is one among the most commonly diagnosed cancer in women. Most commonly it metastasizes within peritoneal cavity by transcoelomic spread; distant metastasis to central nervous system through hematogenous spread is rare, and intramedullary spread is even rarer. Till date, only six reports have identified isolated intramedullary metastasis to spinal cord in a patient who were considered disease free on follow-up after treatment of primary disease; of which only two were in dorsal spine. The average time for diagnosis of intramedullary metastasis after diagnosis of primary disease was 26 months in previous reports. All were on regular follow-up, and clinicians were misleaded by normal CA-125 levels, and patients were considered disease free. This report is third in world literature case of isolated intramedullary dorsal spinal cord metastasis in a patient of primary ovarian carcinoma who was on follow-up with normal CA-125 levels and was treated with myelotomy and gross total resection of lesion + adjuvant chemotherapy and oral steroids. With our experience, we recommend keeping magnetic resonance imaging neuraxis to be done in follow-up of patients treated for high-grade ovarian carcinoma so that early diagnosis and prompt management can be given to patients that can improve their quality of life.

Keywords: *Distant ovarian metastasis, high-grade ovarian carcinoma, intramedullary spinal cord metastasis, intramedullary spinal tumors*

Kartik Manoj Multani, Rahul Srinivasan[1], Komal Tejwani[2], Boyina Jagadeshwar Rajesh

Department of Neurosurgery, Yashoda Superspeciality Hospital, Secunderabad, Telangana, [1]Department of Neurosurgery, Medical Trust Hospital, Kochi, Kerala, [2]Department of Obstetrics and Gynecology, Sri Aurobindo Institute of Medical Sciences, Indore, Madhya Pradesh, India

Introduction

Ovarian carcinoma is the 7th most commonly diagnosed and 8th most common cancer associated with cancer-related death in women.[1] Metastatic ovarian carcinoma is associated with poor survival and usually seen as a disseminated abdominal disease, but very rarely distant hematogenous metastasis to location like spinal cord is also reported. Metastasis forms a part of spectrum of rare intramedullary spinal cord tumors after glial tumors and hemangioblastoma. Lung and breast cancers are the most common primary disease to metastasize to intramedullary spinal cord, while reports describing solid tumors such as ovarian cancers with such spread are sparse.[2]

We present our experience with one such patient of ovarian carcinoma with isolated intramedullary metastasis in dorsal spine who received standard treatment and was believed to be disease free on follow-up visits. To the best of author's knowledge, this is the third in world literature report describing such disease in dorsal spine. It also strengthens the idea of keeping metastases as a differential in ovarian cancer patients who present to clinic with deficits localizing to intramedullary cord levels so that early diagnosis and stellar care can be given which in turn can have a positive effect on survival and quality of life of such patients.

Case Report

A 74-year-old female with CA-125 levels of 1991.89 units/ml underwent transabdominal hysterectomy with bilateral salpingoophorectimy and bilateral pelvic lymph node dissection. Histopathological examination (HPE) of excised specimen revealed ovarian adenocarcinoma, and the patient received six cycles of adjuvant chemotherapy with paclitaxel and carboplatin. On regular follow-up visits, there were no clinicoradiological signs of disease recurrence and her CA-125

Address for correspondence:
Dr. Kartik Manoj Multani, Department of Neurosurgery, Yashoda Superspeciality Hospital, Secunderabad, Telangana, India.
E-mail: kartik.multani@gmail.com

Access this article online

Website: www.asianjns.org

DOI: 10.4103/ajns.AJNS_42_21

Quick Response Code:

How to cite this article: Multani KM, Srinivasan R, Tejwan K, Rajesh BJ. Isolated thoracic spine intramedullary metastasis from primary ovarian carcinoma: A rare case report. Asian J Neurosurg 2021;16:575-8.

Submitted: 30-Jan-2021 **Revised:** 08-Feb-2021
Accepted: 20-Mar-2021 **Published:** 14-Sep-2021

levels were dropped to 2.19 units/ml at 1- year follow-up. Approximately 18 months after the end of treatment patient was referred to neurosurgical outpatient department with complaints of bilateral lower limb dysaesthetic pain, sensory loss to pain, and temperature at lower abdomen and asymmetric paraparesis (left −4/5 and right +4/5) with left extensor plantar response and a clinical localization to intramedullary D10 spinal cord level was made. The patient was evaluated with magnetic resonance imaging (MRI) scan of dorsolumbar spine which was suggestive of bulky cord with intramedullary lesion at D6/D7 vertebral level which was isointense on T1-weighted image, hypointense on T2-weighted image with hyperintense edema extending craniocaudally from D3 to D10 without any polar cyst or hemosiderin cap, on gadolinium injection the lesion was avidly enhancing, and a differential diagnosis of metastasis was made based on her past history [Figure 1]. The patient was further evaluated with positron emission tomography-computed tomography (CT) scan which showed hypermetabolic lesion in spinal cord at D7 vertebral level without any other fluorodeoxyglucose avid lesions in body and her CA-125 levels were within normal limits. Based on above findings, expected survival of >6 months and gradually worsening neurological status of patient, she was advised surgery. Patients underwent D6–D8 laminectomy and excision of lesion; intraoperatively, a circumscribed mass was seen with clear tumor-cord interface identified at most of the places and a gross total resection was achieved with moderate ease. Postoperatively, the patient was found to have worsening in her paraparesis (right 3/5 and left 1/5), for which she was treated with oral steroids and physiotherapy with rehabilitation. Over the course of 2 months, she gradually recovered to her preoperative neurological status without any untoward new event. Excised tumor on HPE showed small clusters with cribriform pattern and papillae formation, individual cells had scanty cytoplasm and hyperchromatic nuclei. Mitotic figures were abundant, and on immunohistochemical (IHC) analysis, specimens were estrogen receptor/progesterone receptor/PAX-8/WT-1 positive and thyroid transcription factor/CDX-2negative [Figure 2]. Based on HPE and IHC findings, diagnosis of metastatic papillary adenocarcinoma was made. The patient received adjuvant local radiotherapy to postoperative tumor bed. Adjuvant chemotherapy was not given as there was no other intracranial or extracranial lesion. On follow-up visits at postoperative 3 and 6 months, she regained near total strength in her lower limbs and was able to carry out her activity of daily living without any assistance. Postoperative 6 months and 1 year MRI [Figure 3] showed no recurrence or new disease in craniospinal axis, and the patient was lost to follow-up after 1 year of disease-free interval.

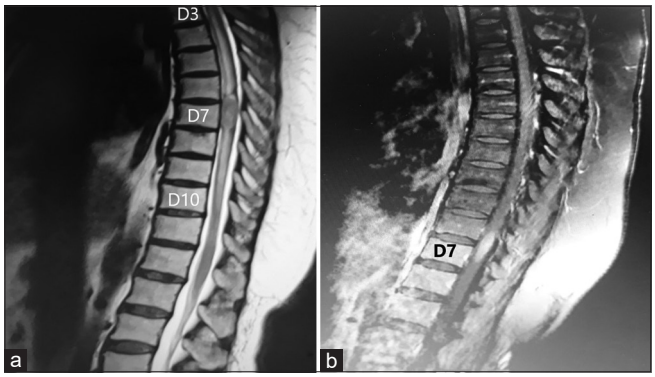

Figure 1: Preoperative magnetic resonance imaging. (a) T2 fluid-attenuated inversion recovery showing thickened spinal cord with intramedullary heterogeneous isointense lesion at D7 with cord edema extending from D3 cranially to D10 caudally, (b) postgadolinium scan showing a well circumscribed avidly enhancing intramedullary mass at D7

Discussion

Intramedullary spinal cord metastases (IMSCm) are rare tumors with the prevalence of 2.1% of all cancers and 8.5% of cases of metastasis in large autopsy series.[3] Neoplasms of lung (40%–60%) followed by breast (14%) are the most common primaries to metastasize to intramedullary spinal cord.[2] Primary ovarian neoplasm with intramedullary metastases is very rare with reported prevalence of 2.1% of all IMSCm.[4] Patients most commonly present with dysaesthetic pain, sensory loss, motor weakness, and autonomic dysfunction based on the level of cord involvement. Prognosis of such patient as per literature is highly variable with survival of 10 months to 3 years and most probably depends on the time of diagnosis from onset of symptom and treatment received by patient.[5] Role of surgery is to achieve cytoreduction, to get an unambiguous diagnosis by histology and to relieve neurodeficits in patients with expected gross total resection, i.e., in patients where lesion is well circumscribed in preoperative scans. Another viable option is oral steroids which may help reduce tumor-associated vasogenic edema and thus relieve patient symptom or else upfront platinum-based chemotherapy and upfront radiotherapy alone or in combination.

Till date, only seven cases have described isolated intramedullary metastasis (without associated cranial and extramedullary metastasis) as a recurrence for primary ovarian neoplasm, of which four were in cervical spine, one had conus medullaris and cauda equina involvement, and only two cases were involving thoracic spine; in six cases, the primary ovarian carcinoma was high grade (≥ Grade III, FIGO) and only one was Grade IB. In all cases, primary was adequately treated with surgical resection and systemic chemotherapy, and the patient was on regular follow-up and with normal CA-125 levels in six patients, thus considered disease free until they developed neurological sequalae. The average time for diagnosis of spinal disease was 24 months after the diagnosis of primary. Five patients underwent surgical resection for IMSCm with adjuvant therapies and two patients were treated with upfront radiation. Two patients died at 5 and 10 months

Table 1: Summary of isolated intramedullary metastasis from primary ovarian carcinoma published in literature till date

Authors	Histology of primary	Level of lesion	Time from primary diagnosis to spinal diagnosis	Treatment received	Outcome of patient
Cormio *et al*.. (2001)	Poorly differentiated serous Cystadenocarcinoma Grade IV	C4-C5	18 months	Radiotherapy Chemotherapy Steroid	Neurologically improved Died at 10 months follow-up
Bakshi *et al*.. (2006)	Serous papillary Adenocarcinoma Grade III	Conus Medullaris Cauda equina	2 years	Radiotherapy Chemotherapy Steroid	Neurologically improved Remission at 3 years follow-up
Isoya *et al*.. (2004)	Adenocarcinoma Grade IIIc	T10	4 years	Subtotal resection Local radiotherapy	No neurological improvement Disease free at 2 years follow-up
Rastelli *et al*.. (2005)	Cystadenocarcinoma Grade IB	T11	2 years	Radiotherapy Chemotherapy Steroid	Neurologically improved Remission at 3 years follow-up
Miranpuri *et al*.. (2011)	Serous papillary Adenocarcinoma Grade IIIc	C2-C5	2 years	Subtotal resection Local radiotherapy Steroids	Neurologically improved Died at 5 months follow-up
Soylemez *et al*.. (2017)	Poorly differentiated serous Cystadenocarcinoma Grade IIIc	C6-C7	NA	Gross total resection	Disease free at 3 years follow-up
Huang *et al*. (2017)	Adenocarcinoma Grade IIIc	C7-T1	2 years	Steroids Gross total resection Chemotherapy	Disease free at 6 months follow up
Our case	Serous papillary adenocarcinoma Grade III	D6-D7	18 months	Gross total resection Local radiotherapy Steroids	Disease free till 2 years than lost to follow-up

NA - Not available

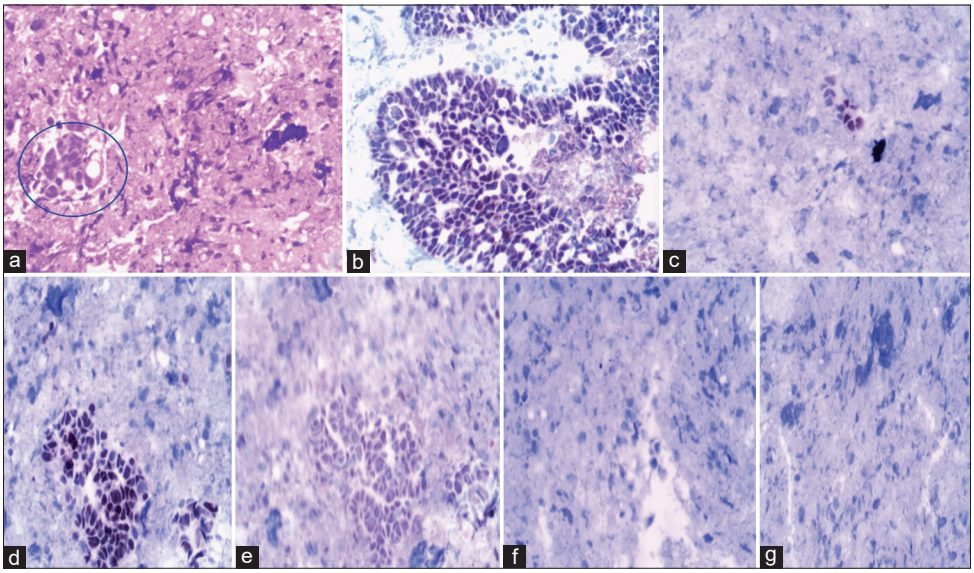

Figure 2: (a) Histopathological examination showing small clusters with cribriform pattern and papillae formation, individual cells had scanty cytoplasm and hyperchromatic nuclei; immunohistochemical analysis showing. (b) Estrogen receptor positive. (c) Progesterone receptor positive. (d) PAX-8 positive. (e) WT-1 positive. (f) Thyroid transcription factor 1 negative. (g) CDX-2 negative

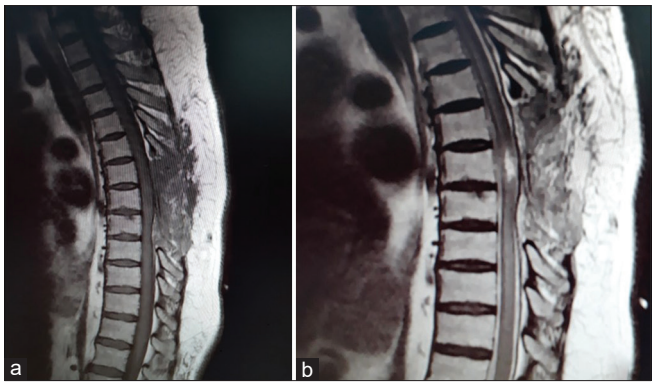

Figure 3: (a) T1WI. (b)T2WI Postoperative MRI showing gross total resection of IMSCm

follow-up from disseminated systemic metastasis and rest 5 continued to be disease free [Table 1].[6-11]

Due to sparse literature and incidence of IMSCm from ovarian carcinomas, appropriate diagnostic strategies and management protocols are less defined. Routine follow-up of a treated ovarian carcinoma involves contrast CT scans of abdomen and chest as viscera, omentum, and diaphragm are most likely to get solid tumor metastasis by transcoelomic peritoneal spread along with serum CA-125 levels which can be misleading as demonstrated by previously published literature. Mechanism of distant metastasis in ovarian carcinoma is still unclear, and most probably the cancer cells from involved lymph nodes in high stage disease reach internal jugular vein through lymphatic drainage and thus metastasize to distant organs by hematological spread later in the course of disease. Most significant predictors for distant metastasis include P53 null mutations and high stage of primary.[12]

Based on our experience, we recommend clinicians to have a very low threshold for diagnosing central nervous system metastasis in patients with high stage ovarian carcinoma and to perform screening MRI of neuroaxis in follow-up visits even with normal CA-125 values. Regarding treatment, a combination of surgical resection with oral steroids and adjuvant local radiotherapy alone or in combination should be tailored according to case. Choice of surgical resection largely depends on status of primary disease, expected survival, performance status, and most importantly consent of patient and their relatives to accept risk associated with myelotomy and resection of lesion.

Conclusion

Isolated IMSCm is a very rare clinical entity, and due to sparse literature, it can present as diagnostic and therapeutic dilemma for treating clinicians worldwide. Early diagnosis and prompt treatment can give patients with end-stage disease an extended disease-free survival. It is preferrable to keep all management options open for the patient and a stellar treatment should be tailored on case-to-case basis after thorough discussion with neuro-oncologist, medical oncologist, and radiation oncologist with a common goal of improving the quality of life of the patient.

Declaration of patient consent

The authors certify that they have obtained all appropriate patient consent forms. In the form the patient(s) has/have given his/her/their consent for his/her/their images and other clinical information to be reported in the journal. The patients understand that their names and initials will not be published and due efforts will be made to conceal their identity, but anonymity cannot be guaranteed.

Financial support and sponsorship

Nil.

Conflicts of interest

There are no conflicts of interest.

References

1. Torre LA, Islami F, Siegel RL, Ward EM, Jemal A. Global cancer in women: Burden and trends. Cancer Epidemiol Biomarkers Prev 2017;26:444-57.
2. Samartzis D, Gillis CC, Shih P, O'Toole JE, Fessler RG. Intramedullary spinal cord tumors: Part I-epidemiology, pathophysiology, and diagnosis. Global Spine J 2015;5:425-35.
3. Costigan DA, Winkelman MD. Intramedullary spinal cord metastasis. A clinicopathological study of 13 cases. J Neurosurg 1985;62:227-33.
4. Soylemez B, Ozum U, Egilmez R. Cervical Spinal Intramedullary Metastasis of Ovarian Adenocarcinoma: A Case Report. AJCRS [Internet]. 5Feb.2020 [cited 19Apr.2021];3(2):21-4. Available from: https://journalajcrs.com/index.php/AJCRS/article/view/30118.
5. Safadi S, Rendon P, Rutledge T, Mayasy S. Ovarian carcinoma with isolated spinal cord metastasis. J Investig Med High Impact Case Rep 2016;4:2324709616657644.
6. Cormio G, Di Vagno G, Di Fazio F, Loverro G, Selvaggi L. Intramedullary spinal cord metastasis from ovarian carcinoma. Gynecol Oncol 2001;81:506-8.
7. Isoya E, Saruhash Y, Katsuura A, Takahashi S, Matsusue Y, Hukuda S. Intramedullary spinal cord metastasis of ovarian tumor. Spinal Cord 2004;42:485-7.
8. Rastelli F, Benedetti G, Di Tommaso L, Mazzoli M, Calbucci F, Crinò L. Intramedullary spinal metastasis from ovarian cancer. Lancet Oncol 2005;6:123-5.
9. Miranpuri AS, Rajpal S, Salamat MS, Kuo JS. Upper cervical intramedullary spinal metastasis of ovarian carcinoma: A case report and review of the literature. J Med Case Rep 2011;5:311.
10. Bakshi A, Biswas G, Deshmukh C, Prasad N, Nair R, Parikh PM. Successful complete regression of isolated intramedullary spinal cord metastases from epithelial ovarian carcinoma with chemotherapy and radiotherapy. Indian J Cancer 2006;43:136-8.
11. Huang J, Lei D. Intramedullary spinal cord metastasis from ovarian cancer in a 50-year-old female. World Neurosurg 2017;106:1049.e3-0.
12. Mitra AK, Chiang CY, Tiwari P, Tomar S, Watters KM, Peter ME, Lengyel E. Microen- vironment-induced downregulation of miR-193b drives ovarian cancer metastasis. Oncogene. 2015; 34(48):5923–5932.