

A Case of Sellar/Suprasellar Neurocysticercosis Mimicking a Craniopharyngioma

Abstract

Neurocysticercosis (NCC) commonly presents with seizures in developing countries such as Nepal. It may also present with raised intracranial pressure due to obstructive hydrocephalus when cyst is located in the fourth ventricle or foramen of Monro. There are four main stages of NCC (1) Vesicular, (2) Colloidal vesicular, (3) Granular nodular, and (4) Nodular calcified. The colloidal vesicular stages can cause arachnoiditis and thus can cause hydrocephalus whereas obstructive hydrocephalus is usually caused by racemose type of NCC. This case was a suprasellar cyst mimicking craniopharyngioma, supported with clinical history of poor visual acuity, endocrine abnormality, suggested radiological findings by computed tomography scan, and magnetic resonance imaging. Suprasellar NCC was confirmed only by intraoperative findings and histopathology report.

Keywords: Craniopharyngioma, neurocysticercosis, sellar, suprasellar

**Sasa Shakya,
Pritam Gurung,
Dinuj Shrestha,
Pravesh
Rajbhandhari,
Basant Pant**

*Department of Neurosurgery,
Annapurna Neurological
Institute and Allied Sciences,
Maitighar, Kathmandu, Nepal*

Introduction

Neurocysticercosis (NCC) is one of the most common central nervous systems helminthic infections in the developing countries and a major cause of acquired seizure and epilepsy.^[1-3] Although NCC is highly pleomorphic in its presentation,^[4] it usually affects the highly vascular gray-white matter junction, basal cistern, subarachnoid space, and ventricles.^[4-6] However, the suprasellar region is an unusual location for cysticerci and their symptoms and locations resemble with sellar space-occupying lesions.^[4,7] We describe herein a case of suprasellar NCC extending into the sellar region which mimics as a craniopharyngioma.

Case Report

We report a 28-year-old male, presented with rapid progressive loss of vision of the left eye and headache. Neurological examination of the patient revealed no abnormalities except visual acuity of the left eye to be 6/30. Visual field test and visual perimetry showed temporal hemianopia of the left eye.

Magnetic resonance imaging (MRI) of the brain revealed well-defined lobulated cystic lesion measuring about 1.9 cm × 2 cm × 1.9 cm (Anterior-Posterior × Width × Height)

showing thin enhancing wall without internal enhancing lesion located in mid to left side of the suprasellar region extending into the sellar region. [Figure 1a-c] There was minimal extensive involvement of the left cavernous sinus, right deviation and compression of infundibulum, and slightly upward pushed optic chiasma. However, on SWI sequence, there is no calcification. [Figure 1d,e] With craniopharyngioma as one of the differential diagnosis, pituitary hormonal profile of the patient showed increased level of serum prolactin and insulin-like growth factor 1, decreased level of serum cortisol. Other hormones were within normal range. The provisional diagnosis of craniopharyngioma was made and standard pterional craniotomy was performed from the left side. After visualizing the left optic nerve and opening the left optico-carotid cistern, to our surprise, whitish multiple cystic structure was seen which was removed from optico-carotid space and prechiasmatic space. [Figure 2] Borosilicate glass pipette was used for meticulous removal of cystic lesion. The scolex was also seen in the cyst. Few calcifications were also present. Dexamethasone diluted in ringer's lactate

Address for correspondence:

*Dr. Sasa Shakya,
Department of Neurosurgery,
Annapurna Neurological
Institute and Allied Sciences,
Maitighar, Kathmandu, Nepal.
E-mail: drsasashakya@gmail.
com*

Access this article online

Website: www.asianjns.org

DOI: 10.4103/ajns.AJNS_423_20

Quick Response Code:



How to cite this article: Shakya S, Gurung P, Shrestha D, Rajbhandhari P, Pant B. A case of sellar/suprasellar neurocysticercosis mimicking a craniopharyngioma. Asian J Neurosurg 2021;16:204-7.

Submitted: 08-Sep-2020

Revised: 08-Oct-2020

Accepted: 28-Dec-2020

Published: 23-Feb-2021

This is an open access journal, and articles are distributed under the terms of the Creative Commons Attribution-NonCommercial-ShareAlike 4.0 License, which allows others to remix, tweak, and build upon the work non-commercially, as long as appropriate credit is given and the new creations are licensed under the identical terms.

For reprints contact: WKHLRPMedknow_reprints@wolterskluwer.com

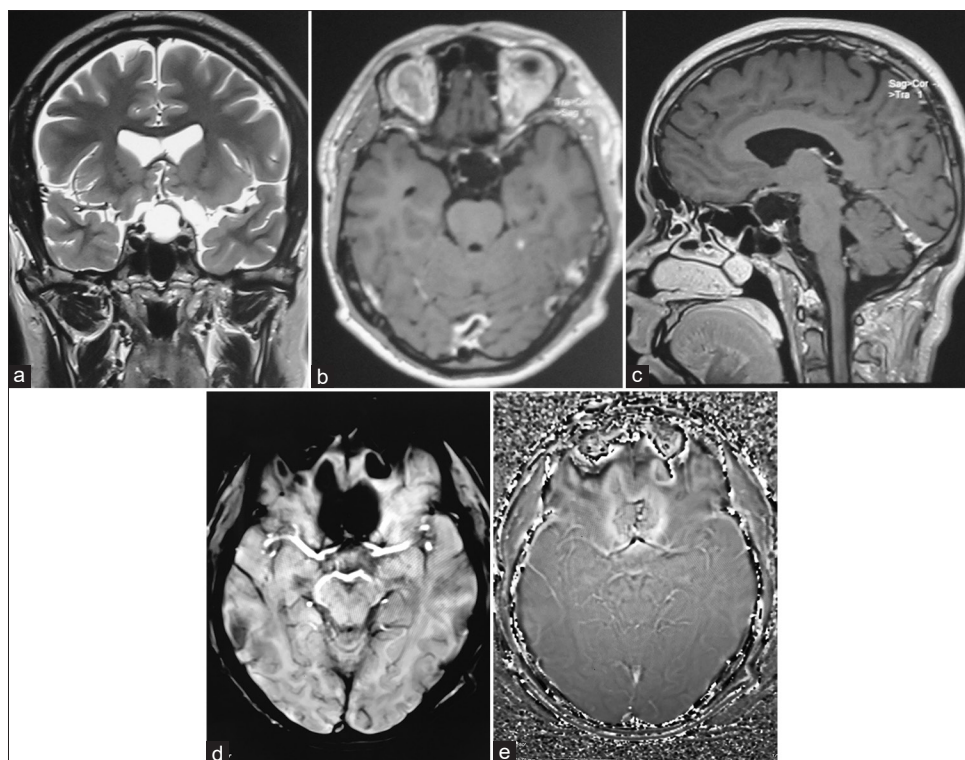


Figure 1: (a) Magnetic resonance imaging of the brain T2 coronal section showing well-defined lobulated lesion, hyperintense signal changes in mid to left side of suprasellar region with minimal extensive involvement of the left cavernous sinus. (b and c) Postcontrast axial section and sagittal section, respectively, showing slight irregular lesion wall with postcontrast enhancement with no obvious internal enhancing lesion or septa. (d and e) SWI sequence revealed no calcification

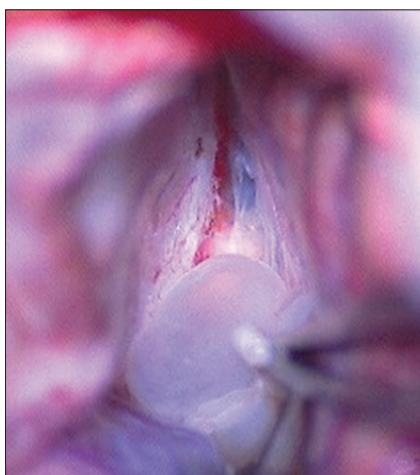


Figure 2: Frontal lobe retraction showing cystic lesion in the suprasellar region

was used for irrigation. Postoperatively, visual acuity improved without any complications. Visual acuity improved with no postoperative complications. Histopathology report showed findings compatible with cysticercosis [Figure 3]. However, immunoglobulin G appeared to be negative after surgery. Postoperative CT scan was unremarkable [Figure 4].

Discussion

In developing countries such as Nepal, with poor personal

hygiene, NCC is caused by intake of contaminated food and water containing larval stage of *Taenia solium*.^[3,5,8,9] Seizure is the most common presentation of NCC.^[1,2]

Sellar/suprasellar location of NCC is very rare and is usually presented with a nonspecific clinical presentation.^[4,5,10] In this case, we present vision loss and endocrinological disturbances as the prime symptoms which can be explained by the variety of pathologies, the most common being direct invasion of the sellar region by cysts with compression of optic chiasma and the pituitary stalk or the hypophysis itself or caused by opticochiasmatic arachnoiditis.^[4,7,11] Computed tomography and MRI diagnose NCC in its different stages.^[1,12,13] However, intrasellar/suprasellar NCC is difficult to be diagnosed by MRI due to the absence of the scolex.^[10]

NCC can be detected by serum and cerebrospinal fluid anticysticercosis antibodies, cysticercal antigens, especially in the patient from cysticercus epidemic areas.^[10] However, in sellar/suprasellar NCC these immunological marker are found to be negative.^[5] Hence, for sellar/suprasellar NCC biopsy or necropsy specimens are needed for histopathological confirmation.^[5]

NCC can be treated conservatively and surgically. Conservative management includes the use of albendazole and praziquantel which provides proven efficacy against

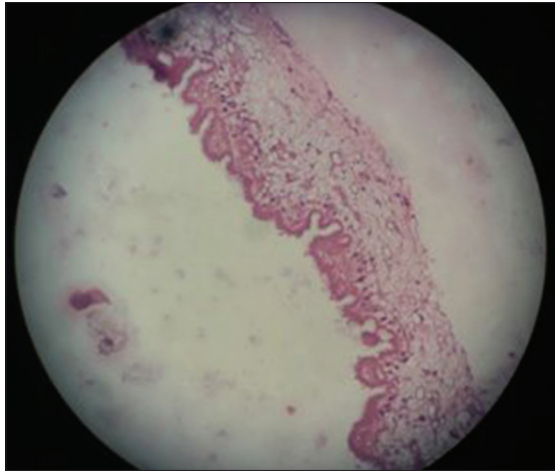


Figure 3: H and E stain showing outer cuticular layer, middle nuclear layer, and the inner reticular layer of the cyst wall (magnification: ×40)

parenchymal NCC; however, there are no studies confirming their efficacy in sellar cysts.^[4,5] The use of corticosteroids^[7] and hormone replacement has also been used to correct the endocrine abnormalities and to decrease local inflammation and edema caused by surgical or medical treatment.^[14]

In surgical approach, pterional craniotomy is considered to be best as it allows excision of the whole cyst and relieves the optic chiasm and nerves from thick adhesions that could pass unnoticed.^[5,10] Besides this, transsphenoidal and extended transsphenoidal surgical approaches have been successfully used to achieve the fenestration or resection of the cyst.^[5,15] Prompt surgical resection of the sellar lesion is recommended to stop progression of the disease and to avoid irreversible loss of visual function.^[4,5]

Biopsy of the NCC microscopically represents solices of cysticercus to be a dense wavy cuticle with focal globular structures.^[16] A surrounding inflammatory, mononuclear lymphocytic reaction with plasma cells is often observed. A variable degree of eosinophilia may be seen.^[14]

Conclusions

Sellar/suprasellar NCC is a very rare entity. Clinical findings, neuroimaging may not be conclusive of NCC, especially when there are sole manifestations of sellar involvement without the involvement of any other location. The most common clinical presentation is headache, visual loss, hypopituitarism, meningitis, and seizure. MRI findings are not conclusive of sellar NCC due to poor visibility of scolex. Only intraoperative features of cyst and postoperative biopsy become conclusive of sellar NCC. NCC should be considered as one of the differential diagnoses in sellar/suprasellar cysts in our part of the world.

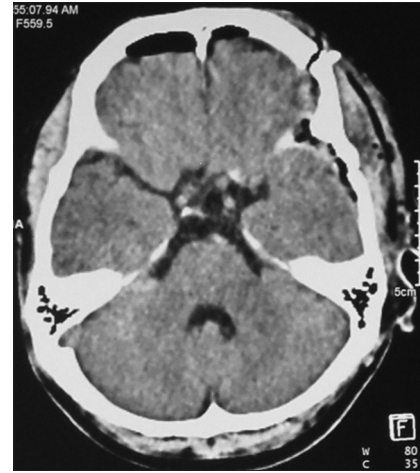

Figure 4: Postoperative Computed tomography scan showing complete removal of suprasellar lesion

Declaration of patient consent

The authors certify that they have obtained all appropriate patient consent forms. In the form the patient(s) has/have given his/her/their consent for his/her/their images and other clinical information to be reported in the journal. The patients understand that their names and initials will not be published and due efforts will be made to conceal their identity, but anonymity cannot be guaranteed.

Financial support and sponsorship

Nil.

Conflicts of interest

There are no conflicts of interest.

References

- Joshi B. The epidemiology and health burden of neurocysticercosis in Nepal. *Int J Trop Dis Heal* 2014;4:204-23.
- Ojha R, Shah D, Shrestha A, Koirala S, Dahal A, Adhikari K, *et al.* Neurocysticercosis in Nepal: A retrospective clinical analysis. *Neuroimmunol Neuroinflammation* 2015;2:167.
- Pant B, Devleesschauwer B, Shrestha P, Shrestha I, Praet N, Dorny P. Intraventricular *Taenia solium* neurocysticercosis: A report of three cases. *JNMA J Nepal Med Assoc* 2011;51:192-5.
- Del Brutto OH, Del Brutto VJ. Intrasellar cysticercosis: A systematic review. *Acta Neurologica Belgica* 2013;112:225-7.
- Del Brutto OH, Guevara J, Sotelo J. Intrasellar cysticercosis. *J Neurosurg* 1988;69:58-60.
- Dutta D, Kumar M, Ghosh S, Mukhopadhyay S, Chowdhury S. Pituitary hormone deficiency due to racemose neurocysticercosis. *Lancet Diabetes Endocrinol* 2013;1:e13.
- Arriada-Mendicoa N, Celis-López MA, Higuera-Calleja J, Corona-Vázquez T. Imaging features of sellar cysticercosis. *AJNR Am J Neuroradiol* 2003;24:1386-9.
- Del Brutto OH. Neurocysticercosis. In: *Handbook of Clinical Neurology*. Elsevier B.V; 2014. p. 1445-59.
- Brutto OH. Neurocysticercosis. *Neurohospitalist* 2014;4:205-12.
- Zhang X, Huang G, Ji T, Liu W, Gao Y, Li W. Sellar

- cysticercosis and septum pellucidum cyst: A case report and review of the literature. *Southeast Asian J Tropical Med Public Health* 2014;45:584-7.
11. Foyaca H, Ibanez Valdes L de F. Uncommon clinical manifestations of cysticercosis. In: *Novel Aspects on Cysticercosis and Neurocysticercosis*. In Tech;2013.
 12. Del Brutto OH, Rajshekhar V, White AC, Tsang VC, Nash TE, Takayanagui OM, *et al.* Proposed diagnostic criteria for neurocysticercosis. *Neurology* 2001;57:177-83.
 13. Del Brutto OH. Diagnostic criteria for neurocysticercosis, revisited. *Pathog Glob Health* 2012;106:299-304.
 14. Zada G, Lopes MB, Mukundan S, Laws E. Neurocysticercosis of the Sellar Region. In: *Atlas of Sellar and Parasellar Lesions*. Springer International Publishing; 2016. p. 419-22.
 15. Rajshekhar V. Surgical management of neurocysticercosis. *Int J Surg* 2010;8:100-4.
 16. Cheong JH, Kim JM, Kim CH. Neurocysticercosis involving the pituitary stalk: Case report and literature review. *J Korean Neurosurg Soc* 2010;48:91-3.