

Mycotic Aneurysm of Intracavernous Internal Carotid Artery Presenting as Cavernous Sinus Syndrome

Abstract

Mycotic intracranial aneurysms are infectious aneurysms accounting for 0.7%–6.5% of all intracranial aneurysms and are most commonly located in distal branches of the middle cerebral arteries, particularly at the bifurcation area. They are caused by weakening of the vessel wall secondary to infection of a segment of the artery that can be endovascular as in infective endocarditis or extravascular as in meningitis or cavernous sinus thrombophlebitis. The rare occurrence of the mycotic cavernous internal carotid artery aneurysm, its variable clinical picture and limited knowledge of its natural course is a challenge for both diagnosis and management.

Keywords: Cavernous sinus syndrome, coil embolization, mycotic intracranial aneurysms

Introduction

Mycotic aneurysm of the intracavernous internal carotid artery (ICA) typically presents as a cavernous sinus syndrome and is often confused with cavernous sinus thrombosis which may be additionally coexisting leading to the formation of these aneurysms. We present our experience of two cases with mycotic cavernous ICA aneurysm in children following orbital cellulitis.

Case Reports

Case 1

A 10-year-old boy presented to the ophthalmology clinic with a complaint of drooping left eye lid for 1 week. Before this, he had a boil at the tip of the nose which was incised and drained following which he developed preseptal cellulitis of the left eye with features of pyogenic meningitis which was treated elsewhere. He remained asymptomatic for a few weeks then he developed drooping of the left eyelid and was referred to us. On examination, his best-corrected visual acuity (BCVA) was 6/6 in the right eye and 6/12 in the left eye. The left eye had complete ptosis and ophthalmoplegia. The left pupil was dilated with no reaction to light and near. Corneal sensations were normal. The left fundus examination was normal. Automated perimetry showed mild

peripheral constriction in the left eye. In the right eye, ocular examination was normal. On investigation, magnetic resonance imaging (MRI) cranium revealed an aneurysm of size 11.7 mm × 10 mm × 9.6 mm in the left cavernous sinus arising from an ICA. Computed tomography (CT) angiography showed a lobulated aneurysm measuring 1.2 cm × 1.5 cm × 2.2 cm with the neck of 49 mm width, projecting superoanteriorly from cavernous part of the left ICA and a small aneurysm of right ICA at petrous apex [Figure 1]. Digital subtraction angiography (DSA) suggested a large aneurysm arising from the cavernous part of left ICA [Figure 2] and a small aneurysm in petrous part of right ICA [Figure 3]. After DSA, a diagnosis of mycotic aneurysm was made, as left cavernous ICA aneurysm was large and persisting after 1 month of antibiotics, it was offered endovascular embolization of the aneurysm. Crossflow from right ICA and from the posterior circulation was assessed, and it was adequate so an aneurysm along with parent vessel embolization was done [Figure 4]. Postembolization there was good cross flow from right ICA. At 1 year follow-up, there was complete improvement of the 6th and 4th nerve palsy with partial improvement of the 3rd nerve palsy. Repeat imaging in the form of magnetic resonance angiography (MRA) was done which did not reveal any a new aneurysm and right petrous ICA aneurysm has not increased in size.

How to cite this article: Sharma K, Kanaujia V, Agarwal R, Singh V, Mishra P. Mycotic aneurysm of intracavernous internal carotid artery presenting as cavernous sinus syndrome. *Asian J Neurosurg* 2019;14:547-9.

**Kumudini Sharma,
Vikas Kanaujia,
Rachna Agarwal,
Vivek Singh¹,
Priyadarshini
Mishra**

Departments of Ophthalmology and ¹Radiology, Sanjay Gandhi Postgraduate Institution of Medical Sciences, Lucknow, Uttar Pradesh, India

Address for correspondence:

*Dr. Kumudini Sharma,
Department of Ophthalmology,
Sanjay Gandhi Postgraduate
Institution of Medical
Sciences, Lucknow - 226 014,
Uttar Pradesh, India.
E-mail: kumud@sgpgi.ac.in*

Access this article online

Website: www.asianjns.org

DOI: 10.4103/ajns.AJNS_39_18

Quick Response Code:



This is an open access journal, and articles are distributed under the terms of the Creative Commons Attribution-NonCommercial-ShareAlike 4.0 License, which allows others to remix, tweak, and build upon the work non-commercially, as long as appropriate credit is given and the new creations are licensed under the identical terms.

For reprints contact: reprints@medknow.com

Case 2

A 3-year-old boy presented to us with a complaint of inward deviation left eye for 2 weeks. Two months ago, he had been treated for orbital cellulitis in both eyes secondary to multiple boils on the scalp for which he received systemic antibiotics for 2 weeks followed by oral antibiotic for 1 week with complete recovery of symptoms. At that time, contrast cranial MRI was normal. Two weeks back, parents noticed inward deviation of the left eye. On examination, his BCVA was 6/6 in the right eye and 6/36 in the left eye. The left eye had esotropia with restriction of abduction. Pupil size and reaction were normal. Fundus examination was also normal. A clinical diagnosis of left lateral rectus palsy was made. MRI was conducted, and it suggested flow void in the left cavernous sinus larger than ICA which on contrast showed enhancement. Right cavernous ICA also showed a small fusiform aneurysm. MRA revealed bilateral intracavernous ICA aneurysms. DSA showed large saccular aneurysm in the cavernous part of left ICA and small fusiform aneurysm of the cavernous part of right ICA [Figure 5]. The patient was given antibiotics for

1 month, but there was no clinical improvement. As both cavernous ICA was involved, so a reconstructive procedure in the form of flow diverter was planned for this patient.

Discussion

Intracavernous carotid mycotic aneurysm is rare and accounts for 3%–5% of intracranial aneurysms.^[1,2] Most of the mycotic aneurysms are a sequela to bacterial endocarditis due to hematogenous spread of septic emboli. Nevertheless, there are also extravascular sources of arterial wall infections as in meningitis, sinusitis, and cavernous sinus thrombophlebitis.^[3] The dural sinuses and the cerebral and emissary veins have no valves, which allows blood to flow in either direction according to pressure gradients in the vascular system. This fact and the extensive direct and indirect vascular connections of the centrally located cavernous sinuses make them vulnerable to septic thrombosis resulting from infection at multiple sites such as paranasal sinuses, face, nose, tonsils, soft palate, teeth, ears, and eyes.^[4] In our cases, the thrombophlebitis of the cavernous sinus invaded the arterial wall and caused localized arteritis leading to the formation of aneurysm. Most of the documented cases of

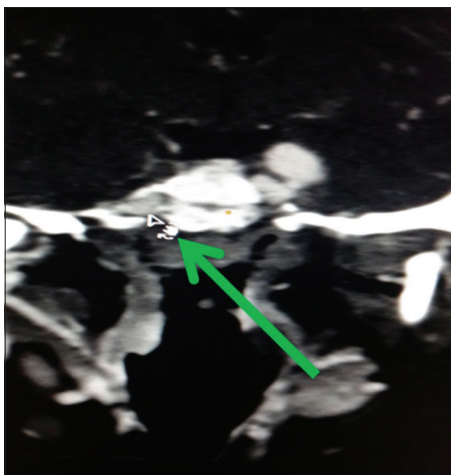


Figure 1: Computed tomography angiography showed a small aneurysm of the right internal carotid artery at the petrous apex

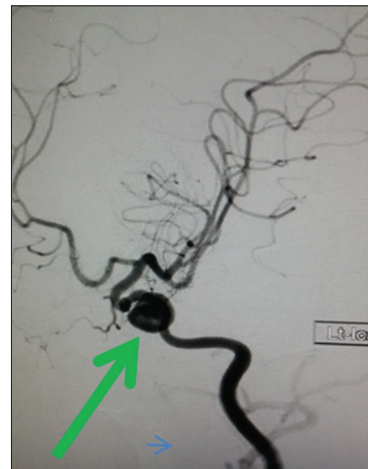

Figure 2: Digital subtraction angiography suggested a large aneurysm arising from the cavernous part of the left internal carotid artery

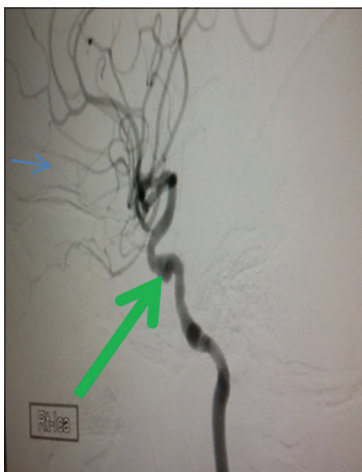

Figure 3: Digital subtraction angiography shows a small aneurysm in petrous part of the right

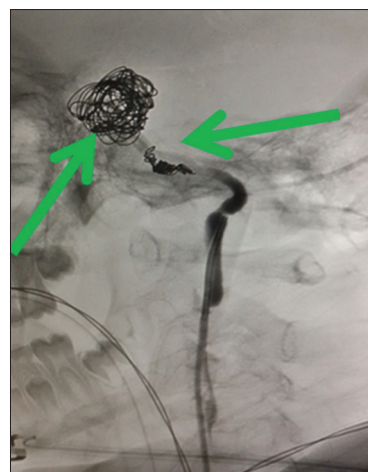


Figure 4: Postparent vessel coil embolization

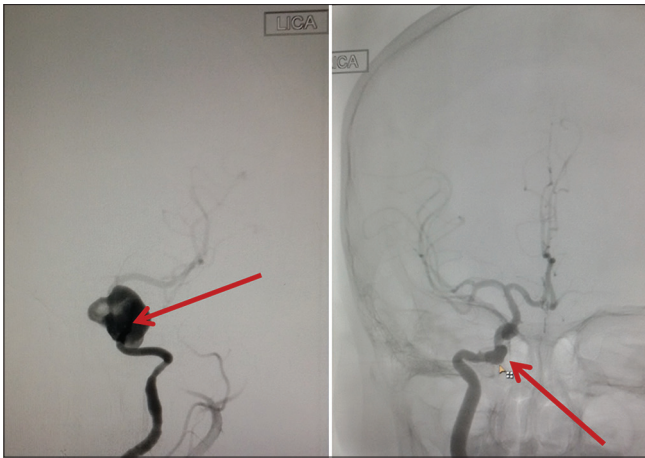


Figure 5: Digital subtraction angiography showed large saccular aneurysm in the cavernous part of the left internal carotid artery and small fusiform aneurysm of the cavernous part of the right internal carotid artery

the intracavernous carotid mycotic aneurysm (ICCA) have been in children with facial infection from less developed countries which, in turn, could be due to the greater susceptibility of children to infection, delayed presentation to a physician, antibiotic resistance, and lack of widespread radiologic investigative facility.^[5] Both our cases were children who developed mycotic aneurysms of cavernous part of ICA following cavernous sinus inflammation secondary to pyogenic meningitis (Case 1), and septic focus on the face (Case 2) and did not respond to systemic antibiotics.

Mycotic aneurysm of the intracavernous ICA generally presents as a cavernous sinus syndrome and is often confused with cavernous sinus thrombosis which may be additionally coexisting leading to the formation of these aneurysms. These type of aneurysms are more threatening as their location is a threat to the nearby neural structure.^[6] Brain and orbit imaging in the form of CT, MRI, and DSA plays an important role in diagnosing ICCA. The interval from initial infection to aneurysm detection can vary from weeks to months. Serial imaging is of immense importance as aneurysms can be absent in the initial imaging and can develop subsequently. Furthermore, it plays a role in charting the treatment plan since mycotic aneurysms are unpredictable and have been shown to improve symptomatically or shrink in size, disappear, enlarge, or develop thrombosis during antibiotic treatment. Repeat imaging can also prevent the catastrophic risk of aneurysm rupture.^[5]

With the advent of antibiotics, extravascular source of infection is more common than the embolic cause. Early treatment with antibiotics allows reparative fibrosis and promotes surgical repair. Surgical or endovascular treatment is needed in case of progressively enlarging aneurysms.

Endovascular procedures in enlarging aneurysms include ICA balloon occlusion, coil embolization of aneurysm and parent vessel, covered stent and flow diverters.^[2]

Reconstructive procedures include reconstruction of involved vessel and disunion of aneurysm using stent graft or flow diverticular. Polytetrafluoroethylene covered stents and polyethylene terephthalate endograft prostheses are successful modes of repair of pseudoaneurysms of the cervical ICA and common carotid artery blow-out.^[7] Wherever possible reconstructive procedure like stent-assisted coiling or flowdivertors or stent graft should be preferred but given a patient being a child with good cross-flow decision of aneurysm coiling along with parent vessel occlusion was done this also saves a child from taking long-term antiplatelets which is mandatory in flow diverters. Regular antiplatelets compliance in children is an issue which along with the cost of the flow diverter persuaded us for deconstructive procedure which anyhow gave long-lasting good outcome.

Second child anyhow requires flow diverter as both ICA are equally involved and cross flow from posterior circulation is not adequate, but due to cost concern could not get it done, is still awaited.

Declaration of patient consent

The authors certify that they have obtained all appropriate patient consent forms. In the form the patient(s) has/have given his/her/their consent for his/her/their images and other clinical information to be reported in the journal. The patients understand that their names and initials will not be published and due efforts will be made to conceal their identity, but anonymity cannot be guaranteed.

Financial support and sponsorship

Nil.

Conflicts of interest

There are no conflicts of interest.

References

1. Cloud GC, Rich PM, Markus HS. Serial MRI of a mycotic aneurysm of the cavernous carotid artery. *Neuroradiology* 2003;45:546-9.
2. Linskey ME, Sekhar LN, Hirsch WL Jr., Yonas H, Horton JA. Aneurysms of the intracavernous carotid artery: Natural history and indications for treatment. *Neurosurgery* 1990;26:933-7.
3. Suwanwela C, Suwanwela N, Charuchinda S, Hongsaprabhas C. Intracranial mycotic aneurysms of extravascular origin. *J Neurosurg* 1972;36:552-9.
4. Ebright JR, Pace MT, Niazi AF. Septic thrombosis of the cavernous sinuses. *Arch Intern Med* 2001;161:2671-6.
5. Micheli F, Shteinschnaider A, Plaghos LL, Melero M, Mattar D, Parera IC. Bacterial cavernous sinus aneurysm treated by detachable balloon technique. *Stroke* 1989;20:1751-4.
6. Ghali MG, Ghali EZ. Intracavernous internal carotid artery mycotic aneurysms: Comprehensive review and evaluation of the role of endovascular treatment. *Clin Neurol Neurosurg* 2013;115:1927-42.
7. Gupta V, Jain V, Mathuria SN, Khandelwal N. Endovascular treatment of a mycotic intracavernous carotid artery aneurysm using a stent graft. *Interv Neuroradiol* 2013;19:313-9.