

Pituitary Tuberculoma Masquerading as a Pituitary Adenoma: Interesting Case Report and Review of Literature

Abstract

We present a rare case of a pituitary tuberculoma masquerading as pituitary adenoma with pituitary apoplexy-like presentation in a 31-year-old female, who had symptoms suggestive of acute secondary adrenal insufficiency with secondary amenorrhea. After initial evaluation which was suggestive of pituitary adenoma, she underwent endoscopic transnasal pituitary tumor excision. Histopathology revealed features of pituitary tuberculoma. She was subsequently started on four drug anti-tubercular therapy and is on follow-up. Although uncommon, tuberculomas, especially in the pituitary gland, are known for behaving like pituitary adenomas, by impairment of pituitary hormonal function and by exerting pressure effects on surrounding vital intracranial structures. Diagnostic challenges, treatment modality, and literature review are presented in this case report. Pituitary tuberculoma even though a rare entity should be borne in mind as a differential diagnosis in a patient manifesting with pituitary apoplexy-like syndrome.

Keywords: Anti-tubercular therapy, hormone replacement, pituitary tuberculoma, sellar adenoma

Introduction

Tuberculosis is an important cause of mortality and morbidity across the world. The involvement of hypothalamo-pituitary axis by tuberculosis is rare.^[1] It presents with features of pituitary insufficiency and signs of pressure effects due to compression of optic chiasma or cavernous sinus. Tuberculous sellar mass can eventually result in permanent endocrine dysfunction, if diagnosis is delayed. The need to investigate early is crucial since endocrine dysfunction is reversible with anti-tubercular therapy.^[2] Clinicians need to be aware of tuberculosis as a possibility in any nonsecreting pituitary lesion. Histopathological examination of the lesion always gives us the final diagnosis.

Case Report

A 31-year-old female presented with complaints of secondary amenorrhea, loss of appetite, and weight loss in the past 1 year associated with multiple episodes of vomiting of 3 days duration. She had two episodes of severe vomiting requiring hospitalization in a span of 7 months. There were no complaints of any visual symptoms. On examination, higher mental

functions, cranial nerves, motor and sensory systems were normal. There were no signs of meningitis. Ophthalmology opinion was sought and it revealed normal visual acuity and visual fields. Laboratory investigations revealed secondary hypocortisolism, hypothyroidism, and hyponatremia with normal prolactin level. Subsequently, endocrinology opinion was sought and she was started on corticosteroids and L-thyroxine. Magnetic resonance imaging (MRI) brain showed features of enlarged pituitary fossa, T1/T2-weighted hyperintense solid enhancing mass lesion approximately 10.5 mm × 16 mm × 14.6 mm with superior extension into suprasellar cistern with enhancement of pituitary stalk [Figure 1]. The lesion was causing mild compression and superior displacement of optic chiasma by 3 mm. The lesion was seen bulging into cavernous sinuses bilaterally just abutting internal carotid arteries with no invasion. There was uniform enhancement of the lesion contrary to ring enhancement seen in tubercular lesions [Figure 2].

She underwent endoscopic transnasal transsphenoidal pituitary tumor excision

Blessy Balaji Prabha¹, Vijay Rangachari¹, Venugopal Subramaniam², Thottatil Viswanathan Gopan³, Vidya Bhat Baliga⁴

Departments of ¹Otorhinolaryngology, ²Neurosurgery, ³Endocrinology and ⁴Histopathology, Manipal Hospitals Whitefield, Bengaluru, Karnataka, India

Address for correspondence:

Dr. Blessy Balaji Prabha,
Department of
Otorhinolaryngology, Manipal
Hospitals, Whitefield,
Bengaluru - 560 066,
Karnataka, India.
E-mail: blessybalaji@gmail.com

Access this article online

Website: www.asianjns.org

DOI: 10.4103/ajns.AJNS_371_20

Quick Response Code:



How to cite this article: Prabha BB, Rangachari V, Subramaniam V, Gopan TV, Baliga VB. Pituitary tuberculoma masquerading as a pituitary adenoma: Interesting case report and review of literature. Asian J Neurosurg 2021;16:141-3.

Submitted: 28-Jul-2020

Revised: 06-Oct-2020

Accepted: 06-Oct-2020

Published: 20-Mar-2021

This is an open access journal, and articles are distributed under the terms of the Creative Commons Attribution-NonCommercial-ShareAlike 4.0 License, which allows others to remix, tweak, and build upon the work non-commercially, as long as appropriate credit is given and the new creations are licensed under the identical terms.

For reprints contact: WKHLRPMedknow_reprints@wolterskluwer.com

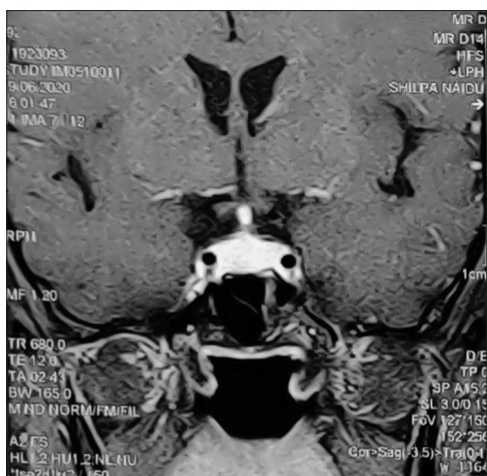

Figure 1: Magnetic resonance imaging of brain showing isointense sellar lesion with enhancement of pituitary stalk

under general anaesthesia. Intraoperatively, the sella was abnormally low lying and thickened, tumor was avascular and fibrous in consistency and was excised preserving the normal arachnoid membrane with no cerebrospinal fluid (CSF) leak. Histopathological examination revealed tissue fragments composed of numerous epithelioid granulomas, some with central caseous necrosis and occasional Langhans' giant cells [Figures 3 and 4]. Periphery showed dense lymphocytic infiltrate mixed with plasma cells and fibrosis. Stroma showed few glands lined by cuboidal cells. Acid-fast bacilli stain was found to be negative. The features were consistent with granulomatous inflammation suggestive of tubercular etiology. Perioperative period was uneventful except for transient diabetes insipidus. Postsurgery, the patient was started on anti-tubercular and hormonal replacement therapy. She is on regular follow-up since the past 3 months and is recovering without any sequelae.

Discussion

Central nervous system tuberculosis contributes to 1% of tuberculosis cases worldwide.^[3] The first report of intrasellar tuberculoma was published by Coleman *et al.*^[4] Intracranial tuberculomas contribute to 0.15%–4% of intracranial space-occupying lesions. Kim *et al.*^[5] stated that pituitary tuberculous infection disseminates by hematogenous route, direct extension from paranasal sinus, or secondary to tuberculous meningitis. The past history or active tuberculous infection elsewhere in the body was seen in 30% of patients.

Srisukh *et al.*^[3] have published a series of 81 case reports of pituitary tuberculoma, of which mean age of presentation was 34.1 ± 13.6 years (range 8–68 years) with more incidence in females (72.8%). The most common presenting symptom was headache (85.2%) followed by visual disturbances (48.1%). Endocrine disturbances were the initial presenting symptoms and included galactorrhea

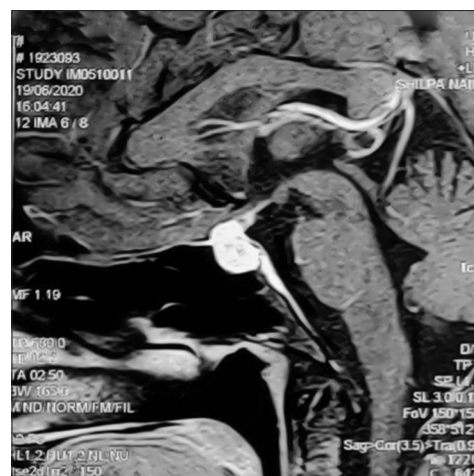

Figure 2: Magnetic resonance imaging of brain showing uniform enhancement of sellar lesion in contrary to ring enhancement seen in tuberculoma

(23.7% of female), amenorrhea (37.3% of female), and polyuria from central diabetes insipidus (8.6%). Central diabetes insipidus was an important factor in differentiating pituitary tuberculoma from pituitary adenoma. Rajasekaran *et al.*^[6] have reported the incidence of pituitary apoplexy being around 2%–7% in cases of pituitary adenoma characterized by acute infarction and/or hemorrhage of the pituitary gland. Deogaonkar *et al.*^[7] have reported that pituitary tuberculoma presenting as apoplexy is extremely rare.

Mascarenhas *et al.*^[2] have stated that on MRI, tuberculous pituitary lesions appear isointense to hypointense on T1-weighted images, hyperintense on T2-weighted images with occasional hyperintensity seen on T1-weighted images due to their high protein content. These are nonspecific and can overlap with pituitary adenomas and other granulomatous lesions. Tuberculous abscess can have peripheral contrast enhancement and adjacent meningeal enhancement on contrast-enhanced MRI. Contrast MRI showing typical changes of thickening and enhancement of pituitary stalk could be an important pointer in diagnosis.^[3,8] Pituitary tuberculoma can be managed conservatively, if confirmed by CSF polymerase chain reaction for tuberculosis if coexistent with an active tuberculous meningitis.^[3]

The main intention of surgery is to have tissue diagnosis and for surgical decompression to relieve pressure symptoms. The transsphenoidal approach is routinely followed as it permits both tissue diagnosis and tumor decompression without CSF contamination. Intraoperative findings of a thickened hypophyseal stalk, grayish firm nonsuckable mass with caseation and a thickened dura, are significant signs of a tuberculous lesion.^[2] Histopathological features are confirmatory and are characterized by a central area of caseation necrosis surrounded by epithelioid cells,

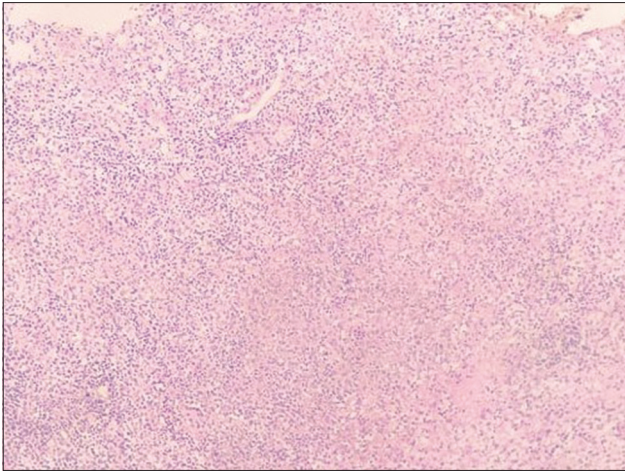


Figure 3: Diffuse granulomas composed of epithelioid cells, lymphocytes, and plasma cells replacing the pituitary gland ×100 (H and E)

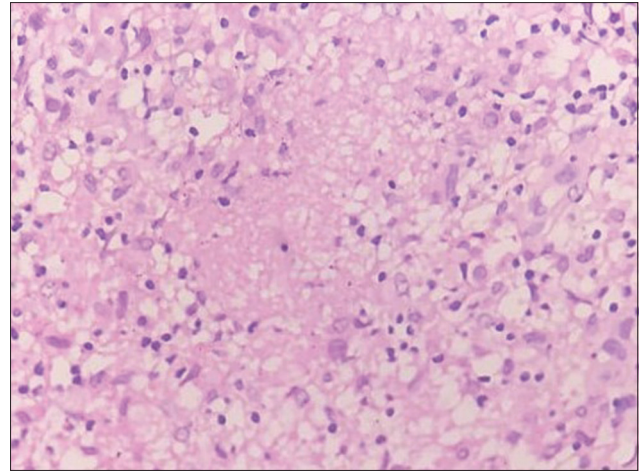


Figure 4: Epithelioid granulomas with central caseous necrosis ×400 (H and E)

lymphocytes, plasma cells, and Langhans' giant cells. Acid-fast bacilli are usually not seen.^[2]

In all sellar region masses, differential diagnosis such as adenoma, cyst of Rathke's pouch, craniopharyngioma, glioma of the optic chiasma or hypothalamus, meningioma, germ cell tumor, hamartoma, lipoma, dermoid or epidermoid cyst, metastasis and granulomatous conditions such as lymphocytic hypophysitis, sarcoidosis, tuberculoma, and Langerhans cell histiocytosis should be borne in mind. Nevertheless, distinctive MRI features, including contrast MRI showing typical changes of thickening and nodularity of the pituitary stalk and ring enhancing lesion can guide diagnosis.^[1,9,10]

A high index of preoperative suspicion with history and radiological features, avoidance of transcranial approach, minimally invasive surgical techniques and prevention of CSF contamination with mycobacterial organisms are important pearls in management. Anti-tubercular therapy is mandatory and the need for hormone replacement therapy is decided based on patient's pre- and post-operative pituitary hormonal status. Anticipated symptoms of pituitary insufficiency following surgery can be avoided by limiting the extent of surgery.^[2]

Despite being a rare entity, it is important to consider pituitary tuberculoma as a differential diagnosis in patients with sellar lesions with distinctive radiological features. Prompt recognition, early diagnosis and commencement of the anti-tuberculosis regimen, postoperative hormone replacement therapy can have good results with significant improvement of symptoms.

Financial support and sponsorship

Nil.

Conflicts of interest

There are no conflicts of interest.

References

1. Ayele BA, Abdinasir W, Abate B, Abdi T. Sellar tuberculoma: A rare presentation in a 30-year-old Ethiopian woman: Case report. *Afr J Neurol Sci* 2019;38:50-3.
2. Mascarenhas JV, Ayyar SV. Tuberculosis of the sella masquerading as pituitary adenoma. *J Clin Sci Res* 2013;2:42-4.
3. Srisukh S, Tanpaibule T, Kiertiburanakul S, Boongird A, Wattanatranoon D, Panyaping T, *et al.* Pituitary tuberculoma: A consideration in the differential diagnosis in a patient manifesting with pituitary apoplexy-like syndrome. *IDCases* 2016;5:63-6.
4. Coleman CC, Meredith JM. Diffuse tuberculosis of the pituitary gland stimulating tumor, with postoperative recovery. *Arch Neurol Psych* 1940;44:1076-85.
5. Kim SH, Kim DG. Sellar tuberculoma mimicking pituitary adenoma. *J Korean Neurosurg Soc* 2003;34:245-8.
6. Rajasekaran S, Vanderpump M, Baldeweg S, Drake W, Reddy N, Lanyon M, *et al.* UK guidelines for the management of pituitary apoplexy. *Clin Endocrinol (Oxf)* 2011;74:9-20.
7. Deogaonkar M, De R, Sil K, Das S. Pituitary tuberculosis presenting as pituitary apoplexy. *Int J Infect Dis* 2006;10:338-9.
8. Gupta PK, Pandey S, Pandey D. Pituitary tuberculoma: An uncommon pathology. *Indian J Neurosurg* 2020. DOI: <https://doi.org/10.1055/s-0039-3401334>.
9. Manghani DK, Gaitonde PS, Dastur DK. Pituitary tuberculoma—a case report. *Neurol India* 2001;49:299-301.
10. Singh S. Pituitary tuberculoma: Magnetic resonance imaging. *Neurol India* 2003;51:548-50.