

Nonmissile Anterior Skull-Base Penetrating Brain Injury: Experience with 22 Patients

Abstract

Background: Nonmissile anterior skull-base penetrating brain injuries (NASBPBIs) have specific characteristic features that are different from missile injuries. Our study presents our experiences on the characteristic features as well as management of NASBPBI. **Materials and Methods:** We retrospectively reviewed 22 consecutive patients with NASBPBI managed at our institute during a 13-year period. The mechanism of injury, clinical investigations, and complications were analyzed, with more emphasis on diagnostic and treatment regimen. **Results:** The 22 cases included in our study comprise of 20 males and 2 females. Majority (72.7%) of the patients were adults with a mean age of 27.5 years. The mechanisms of injury often include accidental fall, either onto a small-diameter sharp object (10 cases) or while carrying such an object in the hand (4 cases). The other common mechanisms were stabbing, accident, or during an altercation (8 cases). Clinical manifestations included periorbital hematoma (10 cases, 45.5%) and cerebrospinal fluid rhinorrhea or orbitorrhea (4 cases, 18.2%) as well as signs of embedded foreign object (8 cases, 36.4%). We performed emergency craniotomy in 21 cases and skin debridement in one case. Postoperative complications were abscess (1 case), epilepsy (1 case), and traumatic carotid-cavernous fistula (1 case). **Conclusion:** Nonmissile injuries are generally on the rise and therefore deserve more attention. We observed that clinical outcomes were excellent in 14 (Glasgow Outcome Scale [GOS] score of 5) and good in the remaining 8 patients (GOS of 4) during 6-month–10-year (mean 4.6 years) follow-ups.

Keywords: Anterior skull base, craniotomy, hematoma, neuronavigation, nonmissile, penetrating head trauma

Introduction

Nonmissile anterior skull-base penetrating brain injuries (NASBPBIs) are infrequent civilian injuries that carry significant morbidity and mortality rates. Complications such as intracranial infections, cerebrospinal fluid (CSF) fistulas, intracranial hemorrhage, pneumocephalus, and cerebral edema are usually associated with these injuries.^[1-4] However, these injuries are often overlooked and underreported. These injuries were first reported way back in 1806.^[2] However, ever since the documentation of the first cases in the year above, single cases or case series and very few research literatures exist.^[2,5] Objects that had penetrated the brain as documented by Pilcher in 1936 include knives, pitchforks, crochet hooks, knitting needles, breech pins, umbrella bibs, crowbars, and iron rods.^[2,6] Recent literature

has also implicated objects such as toilet brush handle, arrows, chopsticks, flatware, screwdrivers, keys, car antenna aerials, and scissors.^[2] Computed tomography (CT) although fails to identify plastic, wood, as well as soil is the most efficient radiology modality used in identifying objects that penetrate the skull and extend to the brain.^[2,7]

Furthermore, vascular abnormalities are frequently associated with penetrating brain injuries. Preventing both short- and long-term hitches related to these injuries is usually the aim of management. Short-term treatment usually includes urgent removal of the foreign body (FB) and avoiding auxiliary neurological injury, hemorrhage, as well as death. Long-term management encompasses prevention and treatment of vascular deformities and malfunctions and obstinate CSF leakage, infection, and seizures.^[2] Pathologically, Penfield reevaluated these wounds by examining the characteristics of experimental

Zhigang Lan¹,
Seidu A. Richard^{1,2,3},
Lu Ma¹,
Chaohua Yang¹

¹Department of Neurosurgery, West China Hospital, Sichuan University, Chengdu, Sichuan, ²Department of Immunology, Jiangsu University, Zhenjiang, Jiangsu, China, ³Department of Surgery, Volta Regional Hospital, Ho, Ghana-West Africa

Address for correspondence:
Prof. Chaohua Yang,
Department of Neurosurgery,
Postgraduate Training
Centre, West China Hospital,
Sichuan University, 37 Guo
Xue Xiang Road, Chengdu,
Sichuan, 610041, China.
E-mail: yangchaohua999@126.
com

Access this article online

Website: www.asianjns.org

DOI: 10.4103/ajns.AJNS_36_18

Quick Response Code:



How to cite this article: Lan Z, Richard SA, Ma L, Yang C. Nonmissile anterior skull-base penetrating brain injury: Experience with 22 patients. Asian J Neurosurg 2018;13:742-8.

This is an open access journal, and articles are distributed under the terms of the Creative Commons Attribution-NonCommercial-ShareAlike 4.0 License, which allows others to remix, tweak, and build upon the work non-commercially, as long as appropriate credit is given and the new creations are licensed under the identical terms.

For reprints contact: reprints@medknow.com

penetrating lesions by means of cannulation.^[2,5] We present a cumulative experience of successful management of 22 cases of NASBPBIs. We further discuss their diagnostic and treatment strategies.

Materials and Methods

We retrospectively reviewed 22 consecutive patients with NASBPBI treated at the Department of Neurosurgery, West China Hospital, from January 2003 to May 2016. The mechanism of injury, clinical manifestations, investigations, and complications were analyzed, with more emphasis on diagnostic and treatment regimens. The ethical committee of our hospital fully approved the study. The patients as well as their relatives were informed about our intention to involve them in this study and they agreed to partake in the study. They also agreed to the publication of their information. All the patients signed the consent form before operation was carried out. All the patients were followed up from 6 months to 10 years (mean 4.6 years). Their neurological outcomes were measured using the Glasgow Outcome Scale (GOS) during the follow-up periods. The descriptions of the patient population as well as relevant data are summarized in Table 1.

Results

Out of the 22 patients included in the study, 20 were males while 2 were females. Majority of the patients (72.7%) were adults with a mean age of 27.5 years (range, 1.5–51 years). The mechanisms of injury often include accidental fall, either onto a small-diameter sharp object (10 cases) or while carrying such an object in the hand (4 cases). The Other common mechanisms were stabbing, accident, or during an altercation (8 cases). All the patients were first seen at the emergency room (ER) in acute state except case 15, a toddler who was brought to the ER with complaints of severe orbital swelling and headache after a fall from 1.5-m platform about 1 month before presenting at our facility (illustrative case 3). Clinical manifestations included periorbital hematoma (10 cases, 45.5%) and CSF rhinorrhea or orbitorrhea (4 cases, 18.2%) as well as signs of embedded foreign object (8 cases, 36.4%). We performed emergency craniotomy in 21 cases and skin debridement in one case.

The dural closure was by suturing the dural defect together. In case of very large dural lost, we used pedicle flaps. Furthermore, in cases with midline defects, nasal mucosal flap was used to close the defect with the aid of endoscopy. Magnetic resonance imaging (MRI) was used to access postoperative complications in all the patients. Additional case complications included traumatic carotid-cavernous fistula developing in one patient (case 6) with classic signs of chemosis, proptosis, and audible bruit 1 month later.^[8] This was successfully treated with covered stent and the signs and symptoms resolved completely. Other postoperative complications were abscess (case 15) and epilepsy (case 2). Two patients lost vision permanently in one eye (cases 17 and 20) and four patients suffered moderate oculomotor palsy or abducens palsy (cases 7, 8, 10, and 21), but their daily activities were not severely affected by these deficits. Clinical outcomes were excellent in 14 (GOS of 5) and good in the remaining 8 patients (GOS of 4) during 6-month–10-year (mean, 4.6 years) follow-ups. Details of the 22 patients are summarized in Table 1.

Illustrative cases

Case 1 (patient 2)

A 22-year-old male was stabbed in the right eye by a rusted metal rod during a street fight. He immediately pulled out the rod by himself and was sent to the local hospital by ambulance. CT scan of the head revealed a large hematoma in the right frontal lobe. A FB was also seen deep within the hematoma [Figure 1a]. Emergency craniotomy and eyeball removal were carried out under general anesthesia. However, we could not locate the FB after complete evacuation of the hematoma and through debridement. The FB was later found to migrate toward deeper brain structures on the postoperative CT scan [Figure 1b]. The patient also had several episodes of epilepsy 5 days after the surgery and antiepileptic drug (antiseizure drug) seemed to have little effect. He was therefore referred to our facility for further assessment and management of his epilepsy. Head CT scan done at our facility revealed a FB embedded in the brain tissue. A second operation was carried out with the aid of intraoperative neuronavigation

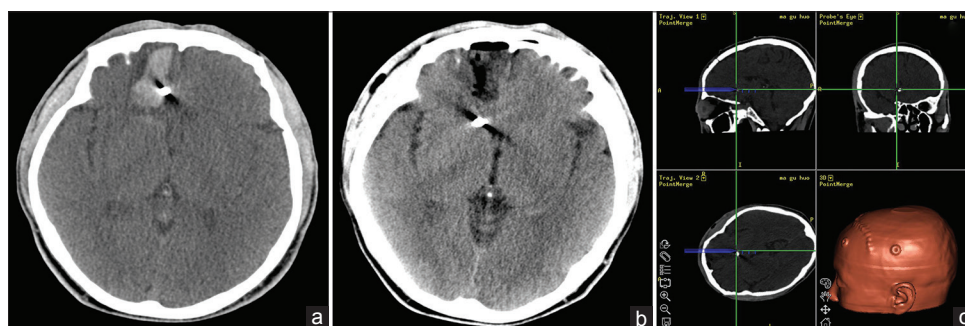

Figure 1: (a) An axial computed tomography scan showing a right frontal hematoma and a hyperdense foreign body within the hematoma; (b) Postoperative computed tomography scan showing the disappearance of the hematoma but the foreign body migrated toward deeper brain structures; (c) Intraoperative computed tomography scan-guided neuronavigation system

Table 1: Patient demographics, injury characteristics, surgery, follow-up, and outcome

Patient number/age (years)/sex	Mechanism	Retained	Initial presentations	Site of CNS entry	GCS	Surgery	Complication	Follow-up (years)	GOS
1/51/male	Fell on wooden stick	Yes	Medial right lid wound	OR	8	FB, subdural hematoma removal and dural repair	None	10	5
2/22/male	Struck by metal rod	Yes	Periorbital hematoma	OR	10	FB removal and dural repair	Epilepsy	8	4
3/30/male	Fell onto wooden stick	Yes	Periorbital hematoma	OR	13	FB removal and dural repair	None	7	5
4/3/male	Fell on a pencil	Yes	LLL puncture	OR	9	FB removal and dural repair	None	7	5
5/6/male	Struck by tree branch	Yes	LUL puncture	SOF	12	FB removal and dural repair	None	6	5
6/40/male	Struck by wooden stick	Yes	Periorbital hematoma	OR	10	FB removal and dural repair	TCCF	6	4
7/29/male	Fell onto wooden stick	Yes	CSF rhinorrhea	SOF	14	FB removal and dural repair	Right oculomotor palsy	6	4
8/32/male	Stabbed by knife	Yes	CSF orbitorrhea	SOF	13	FB removal and dural repair	Right oculomotor palsy	6	4
9/15/female	Fell on tree twig	Yes	Periorbital hematoma	OR	13	FB removal and dural repair	None	5	5
10/31/male	Fell on a chopstick	Yes	Periorbital hematoma	OR	13	FB removal and dural repair	Right abducens nerve palsy	5	4
11/44/male	Tumbled into wood stake	Yes	RLL puncture	OR	15	FB removal and dural repair	None	5	5
12/43/male	Fell onto bamboo stick	Yes	Periorbital hematoma	OR	9	FB removal and dural repair	None	5	5
13/32/male	Poked by nail	No	LLL puncture	OR	14	Skin debridement and ICP monitoring	None	5	5
14/42/male	Fell onto wooden stick	Yes	Periorbital hematoma	OR	13	FB removal and dural repair	None	4	5
15/1.5/male	Fell onto bamboo stick	Yes	LUL puncture	OR	13	FB removal and abscess drainage	None	4	5
16/3/male	Fell on a wooden toy knife	Yes	RLL canthus-imbedded knife	OR	8	FB removal and dural repair	None	3	5
17/23/male	Struck by pool cue	Yes	Periorbital hematoma	OR	13	FB removal, dural repair, and eye enucleation	Lost vision	3	4
18/5/female	Fell on a chopstick	Yes	RUL puncture	SOF	13	FB removal and dural repair	None	2	5
19/38/male	Fell onto a sharpened bamboo stick	Yes	Infrapterional imbedded stick	Tip of greater Sph.w.	13	FB removal and dural repair	None	2	5
20/41/male	Struck by a wood stick in traffic accident	Yes	Periorbital hematoma, CSF rhinorrhea	NC	9	FB removal, dural repair, and eye enucleation	Lost vision	1	4
21/22/male	Fell on tree twig	Yes	CSF orbitorrhea	OR	13	FB, subdural hematoma removal, and dural repair	Left oculomotor palsy	0.5	4
22/51/male	Fell on tree twig	Yes	LUL puncture	OR	13	FB removal	None	0.5	5

LLL – Left lower eyelid; LUL – Left upper eyelid; RLL – Right lower eyelid; RUL – Right upper eyelid; OR – Orbital roof; SOF – Superior orbital fissure; Sph.w. – Sphenoid wing; NC – Nasal cavity; TCCF – Traumatic cavernous carotid fistula; CNS – Central nervous system; ICP – Intracranial pressure; GOS – Glasgow Outcome Scale; CSF – Cerebrospinal fluid

system [Figure 1c] and ultrasound. A metal piece measuring about 3 mm × 3 mm was extracted near the head of caudate nuclei, approximately 4.5 cm from the brain cortex. The patient was seizure free after the second

surgery. He was very stable postoperatively. Eight years' follow-up reveals massive improvement in his quality of life with no neurological deficits.

Case 2 (patient 11)

A 44-year-old male was tripped over during construction work and fell upon a tree twig that protruded out on the ground. The FB penetrated through the left orbito-ethmoidal region, through the left frontal lobe and the internal capsule [Figure 2a]. A three-dimensional reconstruction based on ultra-thin CT scan showed the breaching site of the FB [Figure 2b]. Preoperative angiography was negative. However, we still performed a frontal craniotomy to expose the left frontal lobe and anterior skull base to further gain access to the FB in the cranial vault. The FB, a pine tree twig with a length of 14 cm [Figure 2c], was pulled out by applying a steady retraction at the orbital end. No intracranial bleeding was visualized after the removal of the twig. Large amount of saline water was used to flush out any possible debris and infectious pathogen. The penetrating site of the skull base was then repaired by a pedicled vascularized temporalis fascia, which was sewn in place to provide a “tongue-like” covering around the dural defect. Postoperatively, the patient's condition was stable without any fever or CSF leak. He returned to work 1 month after the surgery. Five-year follow-up reveals massive improvement in his quality of life with no further neurological complications.

Case 3 (patient 15)

A 1.5-year-old baby was brought to the ER with complaints of severe orbital swelling and headache. He fell on a bamboo stick from a 1.5-m platform about 1 month ago. He was initially managed in the local clinic without improvement in his condition before he was referred to our facility. His parents removed the superficial part of the stick exposed on the surface of the skin. He was sent home after a skin debridement. When he presented at our department, CT scan showed a breach in the left orbital roof [Figure 3a] and an MRI scan further revealed an intracerebral abscess with thick capsule [Figure 3b]. Through a parietal craniotomy, the brain abscess was totally resected along with the FB, a bamboo stick [Figure 3c], without any damage to the surrounding brain tissue and blood vessels. The pus cultures revealed alpha hemolytic *Streptococcus*, which was sensitive to ceftriaxone. We also added metronidazole as an adjuvant therapy. The patient was put on these antibiotics for 3 weeks. The child made a good recovery during the follow-up period.

Discussion

Injuries caused by objects with an impact velocity <100 m/s are known as nonmissile injuries.^[9] The relatively thin orbital roof, temporal squama, and cribriform plate allow easy passage of the FB through the anterior skull base to the intracranial cavity,^[10] making the NASBPBI more

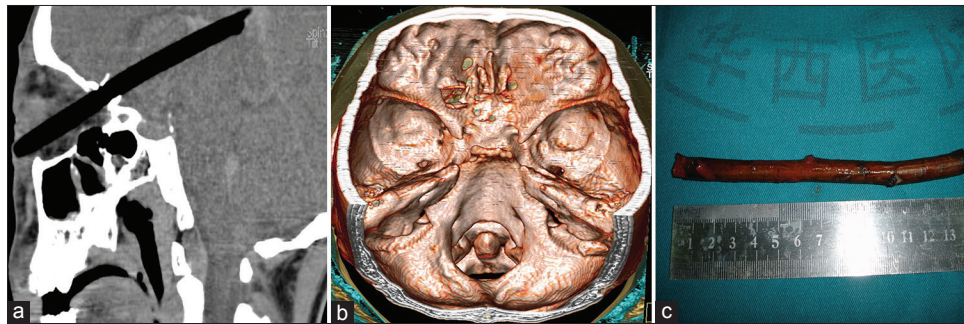


Figure 2: (a) A sagittal computed tomography scan taken before surgery showing the foreign body penetrated through the left orbito-ethmoidal region and embedded deep within the brain; (b) A three-dimensional reconstruction based on computed tomography scan showing the penetration site in the skull base; (c) the retrieved foreign body, a tree branch was measured with a length of 14 cm

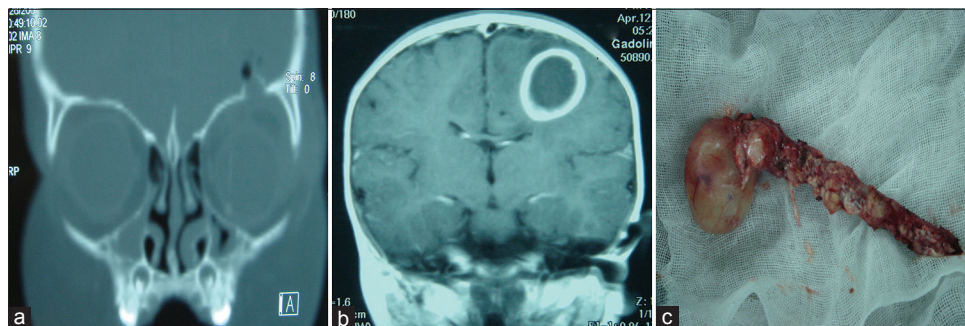


Figure 3: (a) A coronal computed tomography scan of the patient showing penetration of foreign body through the left orbital roof; (b) A magnetic resonance imaging scan showing well-formed abscess around the foreign body; (c) Intraoperative image showing the removed foreign body, a bamboo stick, and the abscess attached to it

common than other penetrating skull-base injuries. The first step toward NASBPBI is the correct diagnosis. Due to the miscellaneous types of materials retained, it is very easy to underestimate the condition, resulting in some margins for misdiagnosis.

In our series, tree branches and fragments of wood were the most common penetrating objects (12 cases), followed by metals (5 cases), bamboo sticks or chopsticks (4 cases), and a led pencil (1 case). The metal FB might be readily visualized on plain CT scan, while the wooden and bamboo FBs can be hard to differentiate due to their similar CT value with the brain parenchyma. It has been proven that ^[1] 6 out of 37 cases (16.2%) with retained FBs were not evidenced on the CT imaging and were discovered at the time of surgical exploration. We also noted that three cases (14.3%) were not visible on the initial plain CT scan we did in our study. The illustrative case 3 was typically misdiagnosed due to limitations of the current CT scan. We advocate that MRI should be done when the presence of metal fragments is excluded by the initial CT scan and patient's condition is relatively stable. This is because a penetrating wood may be poorly visualized on the CT scan. MRI however can better expose the FB, brain parenchyma, as well as abscess formations. Therefore, a negative CT scan does not necessarily exclude the possibility of a retained FB in the case of NASBPBI. We are of the view that CT should be the gold standard in evaluating patients with penetrating metallic objects. Furthermore, MRI should be done in cases of nonmetallic penetrating skull injuries. Nevertheless, CT angiogram is advocated in all patients presenting with these kinds of injuries, although the existence of metallic artifacts from the retained object may hinder visualization of other intracranial structures. ^[2,11-13] The goal of CT angiogram is to assess the cerebral vasculature as well as the magnitude of bone loss or damage during these injuries.

Once the diagnosis is done, the next decision is whether to perform open cranial surgery as well as to decide how immediate and extensive the surgery should be. One might assume that the FB could be pulled out immediately after the injury, creating the assumption that open craniotomy is unnecessary. This is a wishful thinking and can be potentially life-threatening for the patient. It is possible that the FB may pass through some large vessels, hence pulling out the FB without any direct visualization of its intracranial course may lead to massive intracranial bleeding. We observed that a delay in evacuating the hematoma via craniotomy usually predisposes the patient to significant brain herniation. One of the patients in our illustrative cases (patient 2) presented to us after the FB was removed. This led to the formation of a large frontal hematoma. Similar occurrences have been reported in literature. ^[14,15] Therefore, we advocate that surgical evacuation and debridement be done as soon as the diagnosis is made. The 2001 guidelines for managing penetrating brain injury advocate aggressive

debridement of the bone and missile fragments. Our study echoed with these guidelines. Our first illustrative case needed thorough debridement which we carried out immediately. In our second case, however, we successfully evacuated the hematoma via surgery but could not retrieve the FB. The patient suffered uncontrollable epilepsy, which we believe to be as a result of the continued presence of the FB. The reason for the initial nonretrieval of the FB could be due to the migration of the object into deeper brain structure, although this theory is still unclear. The FB might accidentally fall into deeper parenchyma due to the gravity in the supine surgical position. Nevertheless, during the second surgery, with the support of modern CT-scan-guided neuronavigation system, we located the small FB in the deeper parenchyma. It was successfully removed and his epilepsy obliterated. Therefore, we advocate that thorough or complete debridement guided by modern neuroimages and navigational tools should be the gold standard in the management of NASBPBIs.

CSF leakage is a common complication of penetrating brain injuries and even more common in NASBPBIs. When a FB has made its way through the anterior skull base, the orbital roof or lateral wall, the paranasal sinuses, and the dura and arachnoid can be compromised by the trauma, posing a significant risk for CSF orbitorrhea or rhinorrhea. This is one of the main reasons for open craniotomy in patients presenting with NASBPBIs. Nevertheless, in some cases, the leakage site could not be visualized and repaired without open surgery. CSF leaks after penetrating brain injuries have been documented as one of the main predisposing factors that leads to infectious complications. ^[16,17] Conventionally, the high postoperative CSF leak rate (15%–25%) is often cited as a barrier to the anterior cranial base surgery. ^[18] With the use of vascular pedicled flaps and suturing techniques, the postoperative CSF leak rate can be decreased by <2%. ^[19] The guidelines for the management of penetrating brain injury recommend surgical correction for CSF leaks when the defect does not close spontaneously or refractory to CSF diversion through a ventricular or lumbar drain. ^[3,8,20] We did not encounter any postoperative CSF leaks in our limited number of cases since the application of dural reconstruction technique previously described in the second illustrative case (patient 11).

Intracranial infection is another major complication after penetrating brain injuries, which has been reported to be associated with increased morbidity and mortality rates. The rate of infection reported in a series of patients with penetrating brain injuries varies directly with the use of early broad-spectrum antibiotics in the management of these patients. It ranges from 1% to 5%, as compared to the reported infection rates in civilian series. ^[10,21,22] Wooden or bamboo sticks, the most common FB in the civilian nonmissile penetrating brain injuries, carry the highest risk of infections because their

porous organic architecture provides excellent culture environment for bacteria. Infectious complications are more frequent. Patients are more prone to infections when CSF leaks or during air sinus injuries, transventricular injuries, or injuries in which the objects cross the midline.^[10,23] *Staphylococcus aureus*, a facultative anaerobic Gram-positive cocci bacterium, is the most frequently encountered organism.^[2,3] In our series, there was only one case of intracranial infection (patient 15), in which alpha hemolytic *Streptococcus* was identified as the responsible pathogen. However, Gram-negative bacteria have also been reported as the cause of intracranial infection after penetrating brain injuries. Therefore, the administration of broad-spectrum antibiotic therapy is deemed necessary in all patients with all types of penetrating brain injuries. Based on the available literature, it is recommended that broad-spectrum antibiotics should be instituted in all penetrating brain injury cases and must be started as soon as possible. Considerable variability exists in the antimicrobial agents used as prophylaxis. There are currently no formal recommendations for NASBPBI patients. However, cephalosporins are the most favorable antibiotics among most trauma physicians. We normally started with ceftriaxone (2 g q 8 h) in combination with metronidazole (500 mg q 8 h) for 7 days postoperatively. Our treatment regimen is according to the recommendation proposed by “Infection in Neurosurgery” working party of British Society for Antimicrobial Therapy.^[3,24,25] We recommend that in patients with intracerebral abscess, this regimen should be prolonged. The only patient who had intracerebral abscess (case 15) in our series was put on antibiotics for 3 weeks.

Posttraumatic epilepsy (PTE) is also a complication of penetrating brain injuries.^[20,26-29] In two series involving military personnel,^[16,30] the total combined incidence of early and late posttraumatic seizures ranged from 33% to 53% and was highest with penetrating head injuries. While the etiopathogenesis of PTE is still an enigma shrouded in mystery, the high rate of PTE after penetrating brain injury is probably due to direct traumatic injury to the cerebral cortex with subsequent cerebral scarring. In this study, only one patient (case 2) developed late PTE, the cause was postulated to be associated with a retained intracranial metal fragment. He went through a second surgery to remove the fragment and he was free of seizure ever since. The absence of seizure after the removal of the retained FB suggested that the seizure might be the result of FB. However, this speculation may not be accurate since the generation of PTE was so complicated and still poorly understood.

Conclusion

In this article, we have shared our preliminary experiences of 22 NASBPBI cases surgically treated with satisfactory

functional outcomes. We observed that the use of both modern neuronavigational and neuroimaging tools can lead to continuous improvement in the management of nonmissile injuries and ultimately to greater patient recovery. Furthermore, with accurate diagnosis, aggressive surgery, and successful postoperative management, NASBPBI patients can have the best chances of attaining positive treatment outcomes. More studies with larger case series are warranted to develop more effective management regimens for this subclass of traumatic injuries.

Informed consent

Informed consent was obtained from all individual participants included in the study.

Declaration of patient consent

The authors certify that they have obtained signed patients consent. All the patients in this study and their guardians (especially patients 2, 11 and 15) had given their consent for their images and other clinical information to be published. The patients and the guardian understand that their names and initials will not be published and due efforts will be made to conceal their identity, but anonymity cannot be guaranteed.

Financial support and sponsorship

Nil.

Conflicts of interest

There are no conflicts of interest.

References

1. Turbin RE, Maxwell DN, Langer PD, Frohman LP, Hubbi B, Wolansky L, *et al.* Patterns of transorbital intracranial injury: A review and comparison of occult and non-occult cases. *Surv Ophthalmol* 2006;51:449-60.
2. Sweeney JM, Lebovitz JJ, Eller JL, Coppens JR, Bucholz RD, Abdulrauf SI, *et al.* Management of nonmissile penetrating brain injuries: A description of three cases and review of the literature. *Skull Base Rep* 2011;1:39-46.
3. Li XS, Yan J, Liu C, Luo Y, Liao XS, Yu L, *et al.* Nonmissile penetrating head injuries: Surgical management and review of the literature. *World Neurosurg* 2017;98:873.e9-873.e25.
4. Chowdhury FH, Haque MR, Hossain Z, Chowdhury NK, Alam SM, Sarker MH, *et al.* Nonmissile penetrating injury to the head: Experience with 17 cases. *World Neurosurg* 2016;94:529-43.
5. Mason F. Case of a young man who had a pitchfork driven into his head four inches who speedily got well. *Lancet* 1870;1:700-1.
6. Pilcher C. Penetrating wounds of the brain: An experimental study. *Ann Surg* 1936;103:173-98.
7. Gupta PK, Thajjuddin BA, Al Sikri NE, Bangroo AK. Penetrating intracranial injury due to crochet needle. *Pediatr Neurosurg* 2008;44:493-5.
8. Li J, Lan ZG, Xie XD, You C, He M. Traumatic carotid-cavernous fistulas treated with covered stents: Experience of 12 cases. *World Neurosurg* 2010;73:514-9.
9. Clark WC, Muhlbaier MS, Watridge CB, Ray MW. Analysis of 76 civilian craniocerebral gunshot wounds. *J Neurosurg* 1986;65:9-14.

10. Miller CF, Brodkey JS, Colombi BJ. The danger of intracranial wood. *Surg Neurol* 1977;7:95-103.
11. Martin S, Raup GH, Cravens G, Arena-Marshall C. Management of embedded foreign body: Penetrating stab wound to the head. *J Trauma Nurs* 2009;16:82-6.
12. Richard SA, Shrestha SS, Zhang C, Fu W, Wang T, Cong W, *et al.* Successful treatment of a child with ruptured arteriovenous malformation using onyx embolization: A case report. *Open J Mod Neurosurg* 2017;7:153.
13. Zhang CW, Richard SA, Wu C, Wang T, Lui LX, Xie XD. Successful treatment of iatrogenic vertebral artery pseudoaneurysm with coil embolization: Case report. *J Vasc Med Surg* 2017;5:342.
14. Agarwal PK, Kumar H, Srivastava PK. Unusual orbital foreign bodies. *Indian J Ophthalmol* 1993;41:125-7.
15. Demetriades AK, Papadopoulos MC. Penetrating head injury in planned and repetitive deliberate self-harm. *Mayo Clin Proc* 2007;82:536.
16. Levi L, Borovich B, Guilburd JN, Grushkiewicz I, Lemberger A, Linn S, *et al.* Wartime neurosurgical experience in Lebanon, 1982-85. I: Penetrating craniocerebral injuries. *Isr J Med Sci* 1990;26:548-54.
17. Brandvold B, Levi L, Feinsod M, George ED. Penetrating craniocerebral injuries in the Israeli involvement in the Lebanese conflict, 1982-1985. Analysis of a less aggressive surgical approach. *J Neurosurg* 1990;72:15-21.
18. Schaller B. Subcranial approach in the surgical treatment of anterior skull base trauma. *Acta Neurochir (Wien)* 2005;147:355-66.
19. Zimmer LA, Theodosopoulos PV. Anterior skull base surgery: Open versus endoscopic. *Curr Opin Otolaryngol Head Neck Surg* 2009;17:75-8.
20. Younes W. Craniocerebral injuries by impacted foreign objects: Case series and literature review. *Egypt J Neurosurg* 2015, 30:55-62.
21. Byrnes DP, Crockard HA, Gordon DS, Gleadhill CA. Penetrating craniocerebral missile injuries in the civil disturbances in Northern Ireland. *Br J Surg* 1974;61:169-76.
22. Chibbaro S, Tacconi L. Orbito-cranial injuries caused by penetrating non-missile foreign bodies. Experience with eighteen patients. *Acta Neurochir (Wien)* 2006;148:937-41.
23. Gaynor WC, Gurwitz J. Experiences with 156 penetrating wounds of the head. *Ann Surg* 1945;122:12-22.
24. Bayston R, de Louvois J, Brown EM, Johnston RA, Lees P, Pople IK, *et al.* Use of antibiotics in penetrating craniocerebral injuries. "Infection in Neurosurgery" working party of British society for antimicrobial chemotherapy. *Lancet* 2000;355:1813-7.
25. Zhang D, Chen J, Han K, Yu M, Hou L. Management of penetrating skull base injury: A Single institutional experience and review of the literature. *Biomed Res Int* 2017;2017:2838167.
26. Huang J, Li D, Chen H. Successful management of a penetrating iron-rod injury through the oral cavity involving the posterior cranial fossa. *Neurol India* 2017;65:666-8.
27. Kothari K, Singh AK, Das S. Penetrating skull injury with six inch fence rod. *Natl J Maxillofac Surg* 2012;3:207-10.
28. Richard SA, Wu M, Lin D. Traumatic subdural effusion evolving into chronic subdural hematoma. *Open J Mod Neurosurg* 2014;5:12.
29. Xu F, Li J, Sun S, Guo E, Hao S, Hou Z, *et al.* The surgical management of a penetrating orbitocranial injury with a Bakelite foreign body reaching the brain stem. *Brain Inj* 2013;27:951-6.
30. Carey ME, Young HF, Mathis JL. The neurosurgical treatment of craniocerebral missile wounds in Vietnam. *Surg Gynecol Obstet* 1972;135:386-9.