

## Case Report

# Natural History of Medulloblastoma in a Child with Neurofibromatosis Type I

## Abstract

Medulloblastoma is one of the common posterior fossa tumors in children. The natural history of this tumor in presymptomatic period is not well known. Widespread use of brain imaging has increased the detection of incidental brain tumors in totally asymptomatic persons. Here, we report a case of a 4-year-old boy with prenatal diagnosis of congenital brain abnormalities and neurofibromatosis type I. He underwent regular brain imaging to follow interhemispheric arachnoid cyst and ventriculomegaly that a posterior fossa tumor was discovered. The tumor size increased during time and became symptomatic after 28 months which was resected.

**Keywords:** Imaging, medulloblastoma, natural history, neurofibromatosis

## Introduction

The posterior fossa is a common location of primary intracranial tumors of childhood which approximately 47% of pediatric brain tumors occur in this area.<sup>[1]</sup> Medulloblastoma, pilocytic astrocytoma, ependymoma, and brainstem glioma constitute the most common neoplasms of the posterior fossa. Medulloblastoma as a malignant tumor needs tumor resection and adjuvant therapy for longer survival. The natural history of medulloblastoma in presymptomatic period or natural history in neurofibromatosis type (NF) 1 is not well documented.<sup>[2]</sup> On the other hand, detection of incidental brain tumors (incidentalomas) is increasing consequently to the widespread use of brain computed tomography (CT) and magnetic resonance imaging (MRI). Natural course of these tumors can be discovered by sequential imaging in totally asymptomatic persons with tumor incidentaloma.

Here, we present case of a 4-year-old boy who was performing regular brain imaging to follow congenital brain abnormalities of interhemispheric arachnoid cyst, corpus callosum agenesis, and ventriculomegaly which a midline posterior fossa lesion was discovered at the age of 2. After 28 months of observation, the tumor was resected, and the pathological study revealed medulloblastoma.

This is an open access journal, and articles are distributed under the terms of the Creative Commons Attribution-NonCommercial-ShareAlike 4.0 License, which allows others to remix, tweak, and build upon the work non-commercially, as long as appropriate credit is given and the new creations are licensed under the identical terms.

For reprints contact: reprints@medknow.com

## Case Report

A 4-year-old boy was referred to our department for surgery of a posterior fossa mass which caused a few weeks' headache without neurological deficit. He was a known case of interhemispheric arachnoid cyst, corpus callosum agenesis, and mild ventriculomegaly diagnosed during the prenatal period. He was suspicious of NF type I with multiple café-au-lait on his skin and normal development.

Regular brain CT scan and MRI were performed to follow his congenital anomalies which confirmed the decreased size of the cyst. Later at the age of 2, new imaging showed a small enhancing nodule at the roof of the 4<sup>th</sup> ventricle in May 2014 with maximum 7 mm [Figure 1]. In 2015, he underwent only one brain CT scan without contrast that showed no tumor or increased ventriculomegaly. Then, he underwent a new brain MRI with contrast in June 2016 that confirmed the significant increase of the 4<sup>th</sup> ventricular roof tumor (maximal diameter of 2 centimeters) but without any symptoms [Figure 2]. As the tumor was hypersignal in T2-weighted MRI, it was considered to a benign lesion. The parents were informed, and they decided to undergo a close follow-up instead of tumor surgery. Three months later, he underwent a new brain MRI that revealed increased maximal diameter of

**Mehdi Golpayegani,  
Farhad Salari,  
Zohreh Habibi<sup>1</sup>,  
Mousarreza  
Anbarlouei<sup>1</sup>,  
Ali Mahdavi<sup>2</sup>,  
Farideh Nejat<sup>1</sup>**

Department of Neurosurgery, Shahid Beheshti University of Medical Science, <sup>1</sup>Department of Neurosurgery, Children's Hospital Medical Center, Tehran University of Medical Science, <sup>2</sup>Department of Radiology, Tehran University of Medical Science, Tehran, Iran

### Address for correspondence:

Dr. Farideh Nejat,  
Department of Neurosurgery,  
Children's Medical Center,  
Tehran University of Medical  
Science, Gharib Street, Postal  
Code 141557854, Tehran, Iran.  
E-mail: nejat@sina.tums.ac.ir

### Access this article online

Website: www.asianjns.org

DOI: 10.4103/ajns.AJNS\_35\_18

### Quick Response Code:



**How to cite this article:** Golpayegani M, Salari F, Habibi Z, Anbarlouei M, Mahdavi A, Nejat F. Natural history of medulloblastoma in a child with neurofibromatosis type I. Asian J Neurosurg 2018;13:918-20.

Other tumor to 27 mm and nonhomogeneous enhancement, mandating surgical resection [Figure 3].

The patient underwent posterior midline craniotomy and gross-total resection of the tumor. The tumor was purple grayish relatively firm coming from the roof of the 4<sup>th</sup> ventricle. The pathological evaluation confirmed “medulloblastoma, not otherwise specified,” as molecular subtype was not studied. The patient was introduced to oncology team for adjuvant therapy. After 1 year of surgery, he is in good health without tumor and any neurologic symptoms.

## Discussion

As far as we know, this is one of the very few cases of medulloblastoma with such a long history and imaging before surgery. The patient did not present any symptoms related to this tumor for around 28 months between when the first MRI detected the existence of the mass and when became symptomatic to be resected. According to this relatively long history and the fact that medulloblastomas are perceived as fast-growing high-grade tumors, the initial clinical impression was astrocytoma – reasoned with a history of NF type I and high signal intensity of tumor in T2-weighted MRI – until pathological evaluation of the excised tumor confirmed medulloblastoma.

Due to the patient’s congenital disorder, regular imaging studies were conducted. Therefore, radiological findings preceded the onset of symptoms. It enabled us to follow the patient more closely and assess the natural history of this tumor much better.

Medulloblastoma can pose broad-spectrum of biological behaviors, and hence, the prediagnostic symptomatic interval (PSI) varies significantly with a median time of 2 months. Surprisingly, it is inversely related to the prognosis and survival possibly because low-grade tumors have milder presentations.<sup>[3,4]</sup>

Studies on doubling time for tumor require sequential neuroimaging. In a study conducted by Ito *et al.*, 26 patients had bromodeoxyuridine labeling index to predict the potential doubling time ( $t_{pot}$ ). The  $t_{pot}$  was 25–82 h. However, in the same study, three patients had serial CT scans which allowed for the calculation of the actual doubling time ( $t_d$ ), which was 20.7, 24.4, and 23.8 days for those three patients, respectively.<sup>[5]</sup> The great difference between the  $t_{pot}$  and actual doubling time indicates a high cell loss factor in *in vivo* settings. Some high-grade medulloblastomas have relatively shorter doubling times. In one case report, the doubling time for a recurrent tumor was reported to be 6.84 days.<sup>[6]</sup>

In this case, the doubling time was calculated on the base of the three MRIs, according to the following formula:

$t_d = t_2 \times 2 / (\log V_B - \log V_A)$ , ( $t_d$  = doubling time,  $t_2$  = interval between two images,  $V_A$  and  $V_B$  are primary and secondary tumor sizes, respectively).

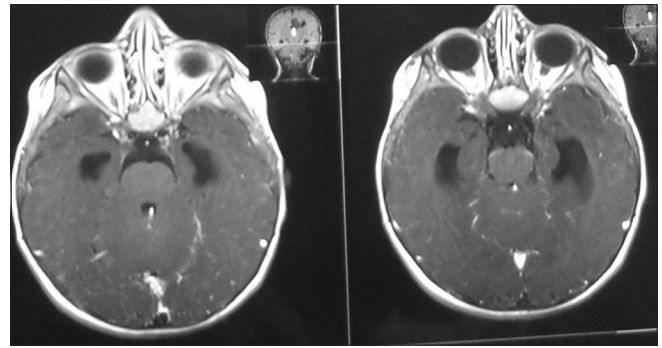


Figure 1: Brain magnetic resonance imaging axial view in May 2014 that showed small enhancing mass at the roof of the 4<sup>th</sup> ventricle

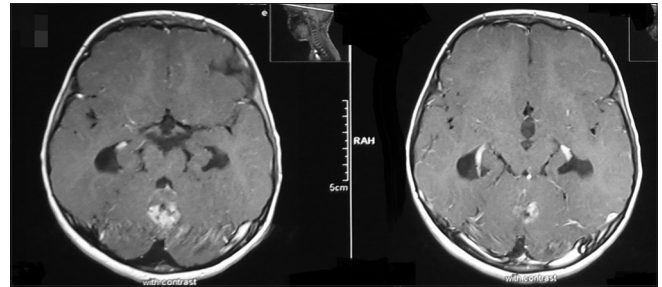


Figure 2: Brain magnetic resonance imaging axial view in June 2016 that confirmed increased size of tumor

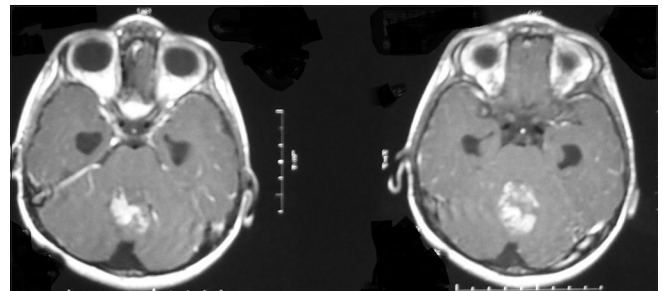


Figure 3: Brain magnetic resonance imaging performed in September 2016 shows rapid growth of tumor in 3 months

In our case, we had three MRI as follows: the volume of medulloblastoma in the first image was <1 cc, the second volume was 4.2 cc (20 mm × 22 mm × 18 mm), and the last one was 9.5 cc (24 mm × 30 mm × 25 mm). The intervals between images were 731 and 60 days, respectively. Therefore,  $t_d$  in the first period was at most 353 days, and in the second period, it was calculated to be 50.9 days.  $t_d$  of 353 and 50.9 days are significantly longer compared to other reports for medulloblastoma which support the idiosyncratic nature of this tumor as suggested by recent studies.<sup>[2,4]</sup> On the other hand, this longer  $t_d$  can be related to genetic basis of NF type I.

Revealed that there are four subgroups of medulloblastoma with different clinical presentations and outcome. A literature review showed a case of WNT medulloblastoma with the relative long PSI.<sup>[7]</sup> Furthermore, in a case of sonic hedgehog-type

medulloblastoma doubling time was deduced 3–4-fold compared to the previous data.<sup>[2]</sup>

The possible explanation for our results might lie in the impacts of biological changes within the medulloblastoma subgroups.<sup>[8,9]</sup> Accumulation of genetic aberrations in patients with medulloblastoma after a stable phase leads to an increase in the growth speed of the tumor. Genetic studies in a relapsed medulloblastoma showed accumulation of genetic aberrations compared to the corresponding primary tumors which support our hypothesis.<sup>[10]</sup>

In recent years, detection of brain incidentalomas has been increased as a consequence of growth in the application of neuroimaging diagnostic tools.<sup>[11,12]</sup> Cellular density in neuroimaging is a sign of malignant nature of the lesion. However, the pathological study is necessary for definite diagnosis. In this case, primary imaging misinformed us about the tumor's nature due to its persistent size and the absence of clinical symptoms. Wait-and-see or surgical exploration can be considered related to incidentaloma, but the case-by-case approach regarding history, clinical examinations, and neuroradiological clues is suggested.

#### Declaration of patient consent

The authors certify that they have obtained all appropriate patient consent forms. In the form the patient(s) has/have given his/her/their consent for his/her/their images and other clinical information to be reported in the journal. The patients understand that their names and initials will not be published and due efforts will be made to conceal their identity, but anonymity cannot be guaranteed.

#### Financial support and sponsorship

Nil.

#### Conflicts of interest

There are no conflicts of interest.

## References

1. Zakrzewski K, Fiks T, Polis L, Liberski PP. Posterior fossa tumours in children and adolescents. A clinicopathological study of 216 cases. *Folia Neuropathol* 2003;41:251-2.
2. Doron O, Zauberman J, Feldman Z. A medulloblastoma showing an unusually long doubling time: Reflection of its singular nature. *Childs Nerv Syst* 2016;32:1153-6.
3. Halperin EC, Watson DM, George SL. Duration of symptoms prior to diagnosis is related inversely to presenting disease stage in children with medulloblastoma. *Cancer* 2001;91:1444-50.
4. Gilbertson RJ, Ellison DW. The origins of medulloblastoma subtypes. *Annu Rev Pathol* 2008;3:341-65.
5. Ito S, Hoshino T, Prados MD, Edwards MS. Cell kinetics of medulloblastomas. *Cancer* 1992;70:671-8.
6. Bacon S, Clinkard J, Taylor RE. Paediatric medulloblastoma associated with poor prognosis and short volume doubling time. *Br J Radiol* 2005;78:1059-60.
7. Zeilhofer UB, Scheer I, Warmuth-Metz M, Rushing EJ, Pietsch T, Boltshauser E, *et al.* Natural history of a medulloblastoma: 30 months of wait and see in a child with a cerebellar incidentaloma. *Childs Nerv Syst* 2013;29:1207-10.
8. Brasme JF, Grill J, Doz F, Lacour B, Valteau-Couanet D, Gaillard S, *et al.* Long time to diagnosis of medulloblastoma in children is not associated with decreased survival or with worse neurological outcome. *PLoS One* 2012;7:e33415.
9. Northcott PA, Korshunov A, Witt H, Hielscher T, Eberhart CG, Mack S, *et al.* Medulloblastoma comprises four distinct molecular variants. *J Clin Oncol* 2011;29:1408-14.
10. Korshunov A, Benner A, Remke M, Lichter P, von Deimling A, Pfister S, *et al.* Accumulation of genomic aberrations during clinical progression of medulloblastoma. *Acta Neuropathol* 2008;116:383-90.
11. Morris Z, Whiteley WN, Longstreth WT Jr., Weber F, Lee YC, Tsushima Y, *et al.* Incidental findings on brain magnetic resonance imaging: Systematic review and meta-analysis. *BMJ* 2009;339:b3016.
12. Vernooij MW, Ikram MA, Tanghe HL, Vincent AJ, Hofman A, Krestin GP, *et al.* Incidental findings on brain MRI in the general population. *N Engl J Med* 2007;357:1821-8.