

# Intraoperative Use of Endoscope, a Valuable, Adjunctive Tool for the Surgical Management of Anterior Communicating Artery Aneurysm Surgery: Our Institutional Experience

## Abstract

**Background:** Anterior communicating (A-com) artery region is very complex; perforators are not always visualized on the microscope. The neuroendoscope with its higher magnification, better observation, and additional illumination can provide us information that may not be available with the microscope in aneurysm surgery. **Objective:** The objective was to study the use of endoscope in surgical management of A-com aneurysm surgery and its advantages, whether and how it changes operative management. **Materials and Methods:** We studied 25 serial cases of A-com aneurysm at Bantane Hospital, Fujita University, Japan, from November 2018 to October 2019. Once aneurysm was exposed, we did preclipping indocyanine green (ICG) study and examination with endoscope. After clipping, we again did ICG and endoscopic assessment. Preclipping and postclipping endoscopic information was used and necessary changes were made in the operative decisions. Whether endoscope gives any additional information over microscope and ICG which led to change in the operative decision was assessed. **Results:** In six out of 25 A-com aneurysm patients, the use of endoscope has given additional information over microscope, and ICG leading to change in the operative plans such as readjustment of the clip/application of the second clip or release of perforator compromise. **Conclusion:** Simultaneous endoscopic and microscopic guidance can reveal important information hidden from the microscope. Thus, this method increases the safety and durability of the A-com aneurysmal clipping.

**Keywords:** Anterior communicating aneurysm, clipping, neuroendoscope

## Introduction

The goal of surgical management of intracranial aneurysm is to exclude the aneurysm from the circulation while preserving the parent artery, its branches, and perforators while avoiding damage to the adjacent cranial nerves and brain parenchyma.<sup>[1]</sup> Hence, it is crucial to achieve a good view of regional anatomic features, including the relationships between the aneurysm neck, wall and parent vessel, branches, perforators, and adjacent cranial nerves before, during, and after clipping. This is not always possible even with most sophisticated microscope available. This problem is overcome by the intraoperative use of endoscope, which permits observation of areas considered blind under the microscope and allows close-up view of regional anatomic features.

This is an open access journal, and articles are distributed under the terms of the Creative Commons Attribution-NonCommercial-ShareAlike 4.0 License, which allows others to remix, tweak, and build upon the work non-commercially, as long as appropriate credit is given and the new creations are licensed under the identical terms.

For reprints contact: reprints@medknow.com

To enhance the intraoperative visualization of the regional anatomy, endoscopy was introduced during microneurosurgery for cerebral aneurysms by Fischer and Mustafa.<sup>[2]</sup> In 1977, Apuzzo *et al.* applied the side-angled rigid endoscope to neurosurgical procedures and reported its great value for assessing the confirmation of clip placement in a case of the basilar tip aneurysm.<sup>[3]</sup> Perneczky and Fries elaborated on the general principles of endoscope-assisted microsurgery and described three advantages of the endoscope as follows:<sup>[4,5]</sup> (1) increased light intensity while approaching an object, (2) clear depiction of details in close-up positions, and (3) extended viewing angles. Therefore, the surgeon can inspect hidden structures, dissect perforators at the back of aneurysm, identify important

**How to cite this article:** Chavan VS, Yamada Y, Kadam C, Devareddy G, Stanzani R, Shukurov F, *et al.* Intraoperative use of endoscope, a valuable, adjunctive tool for the surgical management of anterior communicating artery aneurysm surgery: Our institutional experience. *Asian J Neurosurg* 2020;15:338-43.

Submitted: 12-Dec-2019

Revised: 23-Dec-2019

Accepted: 11-Mar-2020

Published: 29-May-2020

Chavan Vaibhav S<sup>1,2</sup>,  
Yashuhiro Yamada<sup>2</sup>,  
Kadam Chandratej<sup>2</sup>,  
Devareddy  
Gowtham<sup>2</sup>,  
Stanzani Riccardo<sup>2,3</sup>,  
Shukurov Firuz<sup>2</sup>,  
Kato Yoko<sup>2</sup>

<sup>1</sup>Department of Neurosurgery, Krishna Institute of Medical Sciences, Karad, Maharashtra, India, Departments of

<sup>2</sup>Department of Neurosurgery, Fujita Health University, Bantane Hospital, Nagoya, Japan, <sup>3</sup>Department of Neurosurgery, Neurosurgery Unit, AOU, Policlinico di Modena – OCSAE, Modena Hospital, Modena, Italy

## Address for correspondence:

Dr. Chavan Vaibhav S,  
Department of Neurosurgery,  
Krishna Institute of Medical  
Sciences, Karad - 415 539,  
Maharashtra, India.  
E-mail: vschavan86@gmail.com

## Access this article online

Website: [www.asianjns.org](http://www.asianjns.org)

DOI: 10.4103/ajns.AJNS\_359\_19

## Quick Response Code:



**Table 1: Endoscopic observations**

Age yrs	Sex	Size mm	Observation on Endoscope	Change in operative Plan
69	M	3	Complete clipping	No
70	F	5	Complete clipping	No
62	F	5	Complete clipping	No
79	F	3	Complete clipping	No
79	M	2	Complete clipping	No
69	F	8	Residual aneurysm under first clip visualised	2nd clip applied.
79	M	2	Complete clipping	No
58	F	6	Complete clipping	No
74	M	8	Complete clipping	No
42	M	2	Complete clipping	No
74	F	4	Complete clipping	No
65	M	3	Clip tip compressing on optic nerve	Readjustment of clip
69	M	6	Complete clipping	No
67	F	5	Complete clipping	No
44	F	5	Complete clipping	No
69	F	8	Complete clipping	No
81	M	3	Complete clipping	No
70	F	3	Complete clipping	No
75	F	2	Remnant aneurysm below first clip visualised	Readjustment of clip
70	F	5	Perforator clearly visualised preclipping, Residual aneurysm below first clip.	2nd clip applied and first clip readjusted to avoid perforator.
41	M	5	Complete clipping	No
73	F	5	Complete clipping	No
79	F	7	Perforator compromise	Release of perforator
71	F	7	2 clips applied, 2nd clip tip not across aneurysm, incomplete clipping	Readjustment of 2nd clip
47	M	5	Complete clipping	No

**Table 2: Age group**

Age	Frequency	Percentage
<50	4	16
51-60	1	4
61-70	10	40
>70	10	40

**Table 3: Size group**

P (0.428)	Endoscopic Findings		Total
	Abnormal	Normal	
Size Group			
≤ 3	2(22.2%)	7(77.8%)	9
4 - 5	1(11.8%)	8(89.9%)	9
> 5	3(42.9%)	4(57.1%)	7
Total	6	19	25

**Table 4: Change in operative plan**

Change in operative plan	Frequency	Percentage
Yes	6	24
No	19	76

vessels without retraction of aneurysm, and check for the completion of clipping.

Anterior communicating (A-com) artery anatomy is very complex; there are total of seven major vessels (bilateral A1,

bilateral A2, bilateral recurrent Heubners arteries, and A-com artery) and multiple small perforators. A-com aneurysm can have anterior, superior, inferior, and posterior projections hiding these vessels and perforators during pterional craniotomy. Hence, it is very important to have precise anatomical information before and after the clipping of aneurysm which is possible with simultaneous use of microscope and endoscope. Intraoperative use of endoscope in A-com aneurysm surgery is not individually assessed according to our knowledge. Hence, we present our experience with the use of intraoperative endoscopy in A-com aneurysm surgery.

### Materials and Methods

We studied 25 serial cases of A-com aneurysm which were operated between November 2018 and October 2019 (all were unruptured aneurysms) in Bantane Hospital, Fujita Health University, Japan. For these patients, intraoperative endoscopy was done.

### Instrumentation

We used rigid rod lens endoscope(A81000A, Olympus, Germany) for microsurgical procedures. Rigid endoscope of diameter 2.4 mm and 4.0 mm with angles of 0° and 30° was used. Illumination was provided by the Xenon light source. The endoscope was attached to a three-chip

camera and the images were viewed on video monitor (Olympus, Germany).

### Operative technique

The pterional craniotomy was done in the usual manner. The initial exposure was performed under the microscope. The endoscope was then introduced into the surgical field with observation through microscope, and the endoscopic image is viewed on the monitor. An initial view of the aneurysm and surrounding structures is obtained with the endoscope for the assessment of regional anatomy. Further, dissection and exposure of the aneurysm was performed under the microscope. Once aneurysm was exposed, we did preclipping indocyanine green (ICG) and examination with endoscope. The aneurysm neck was then clipped usually with microscopic observation and occasionally with endoscopic observation assistance. After aneurysm clipping, ICG study and endoscopic inspection were repeated. The inspection includes assessment of the completeness of aneurysm clipping, inadvertent inclusion of the parent vessel in the clip, and pressure on surrounding vital structures such as the cranial nerves. If any of these are encountered, necessary changes were made in operative decisions such as readjustment of the clip, application of the second clip, or release of perforator compromise.

### Results

Of 25 A-com aneurysm patients operated, ten patients were male, while 15 patients were female (male-to-female ratio of 1:1.5) with an average age of 67 years. Following observations were made [Table 1]. The distribution of patients according to the age and size of aneurysm is as shown in Tables 2 and 3. In cases with aneurysm size >5 mm, we found more percentage of abnormal findings (42.9%) on endoscope which lead to change in the intraoperative management [Table 3]. However, this difference was not found statistically significant ( $P = 0.428$ ). In six out of 25 patients, endoscope has given additional information over microscope and ICG which changed the operative plan [Table 4]. In three patients after clip application, there was residual aneurysm visualized below the clip on endoscope (intraoperative ICG showed complete obliteration of aneurismal sac). Hence, the second clip application or readjustment of the clip was done in those patients. In one patient, incomplete clipping (distal tip of the clip was not across the aneurysm) was visualized on endoscope (intraoperative ICG did not show any obvious refilling of aneurysm) and needed readjustment of the clip. In one patient, distal tip of the clip was seen compressing on the optic nerve on endoscopic inspection and needed readjustment of the clip. In one patient, the clip was seen compressing the perforator on endoscopy, and hence, perforator was separated and clip readjustment was done. Postoperative computed tomography angiography did not reveal any neck remnant, and no patients have required further interventional or surgical treatment.

### Illustrative cases

#### *Case 1: Residual aneurysm under the clip*

A 69-year-old female was diagnosed with A-com aneurysm [Figure 1a] with left A1 dominance. The patient was operated with left pterional craniotomy with a transsylvian approach. Intraoperatively, aneurysm was found as shown in Figure 1b. After application of the first clip [Figure 1c], ICG was done suggestive of complete occlusion of the aneurismal sac [Figure 1d] and no residual. After doing intraoperative endoscopy, we found a residual aneurysm below the first clip [Figure 1e], hence, the second clip application was needed for residual aneurysm [Figure 1f].

#### *Case 2: Perforator compromise*

A 79-year-old female presented with A-com aneurysm with right A1 dominance [Figure 2a]. The patient was operated with right pterional craniotomy with transsylvian approach, and aneurysm was visualized as shown in Figure 2b. Preclipping endoscopy was done [Figure 2c] which showed small perforator adherent to dome of the aneurysm, but the aneurysm neck was free. Aneurysm was clipped under the microscope [Figure 2d], but no perforator compromise was noticed, however, after doing postclipping endoscopy [Figure 2e], we found that perforator is kinked and part of its wall is caught in the clip, hence, the readjustment of the clip was done [Figure 2f] and perforator was separated.

#### *Incomplete clipping*

A 71-year-old female presented with A-com aneurysm with right A1 dominance [Figure 3a]. The patient was operated with right pterional craniotomy and transsylvian approach, and aneurysm was visualized, as shown in Figure 3b. Preclipping endoscopy was done [Figure 3c], which was showing multiple perforators at the neck of aneurysm which were separated and aneurysm was clipped with two clips [Figure 3d]. Postclipping endoscopy was done [Figure 3e], which was showing the second clip was not across aneurysm suggestive of incomplete clipping, hence, the readjustment of the second clip was done [Figure 3f].

### Discussion

#### History

The first endoscopic neurosurgical procedure was performed in 1910 by V.L.L'Espinasse, an urologist from Chicago.<sup>[6]</sup> He used a small rigid cystoscope to cauterize the choroid plexus of two hydrocephalic infants. In 1922, Dandy<sup>[7]</sup> coined the term "ventriculoscope" and described the use of a rigid Kelly cystoscope to inspect the lateral ventricles of two hydrocephalic infants. In 1923, Mixer<sup>[8]</sup> described the first successful third ventriculostomy

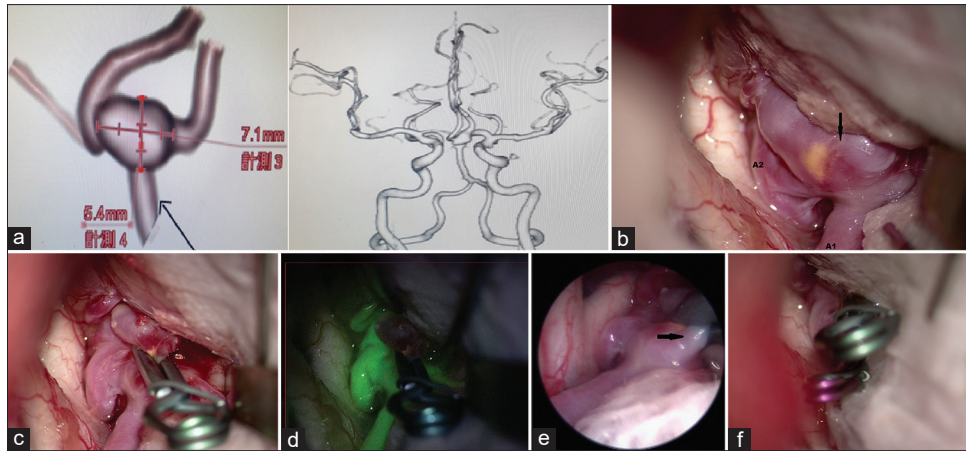


Figure 1: (a) Preoperative three-dimensional computed tomography scan showing anterior communicating aneurysm. (b) Intraoperative microscopic image showing aneurysm (shown by black arrow), ipsilateral A1 and A2. (c) Intraoperative microscopic image showing completely clipped anterior communicating aneurysm. (d) Intraoperative microscopic post indocyanine green image showing completely clipped aneurysm with no indocyanine green in aneurismal sac. (e) Intraoperative endoscopic image showing residual aneurysm sac under the clip. (f) Intraoperative microscopic image showing second clip applied for residual aneurysm

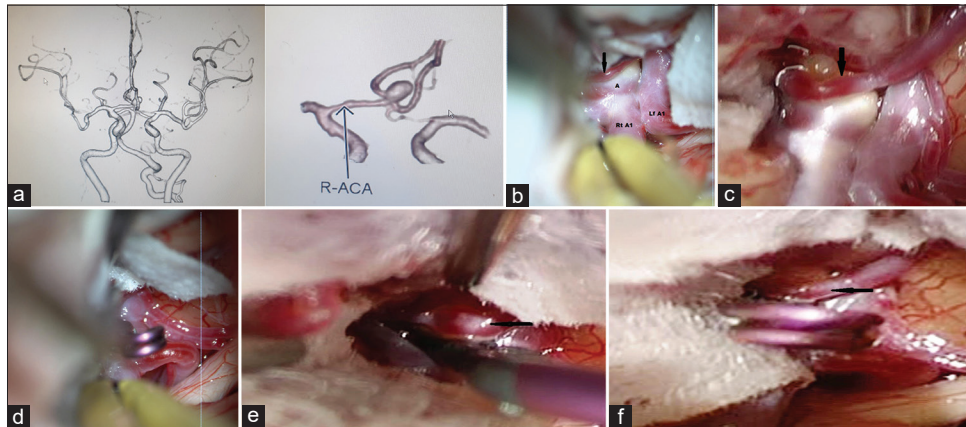


Figure 2: (a) Preoperative three-dimensional computed tomography scan showing anterior communicating aneurysm with the right A1 dominance. (b) Intraoperative microscopic image showing aneurysm (a), right A1, left A1, and perforator (as shown by arrow). (c) Intraoperative endoscopic image showing perforator (shown by arrow) adherent to dome of the aneurysm. (d) Intraoperative microscopic image showing clipped aneurysm. (e) Intraoperative endoscopic view showing perforator getting kinked and part of its wall caught in the clip. (f) Intraoperative endoscopic view showing perforator (shown by black arrow) separated from the clip

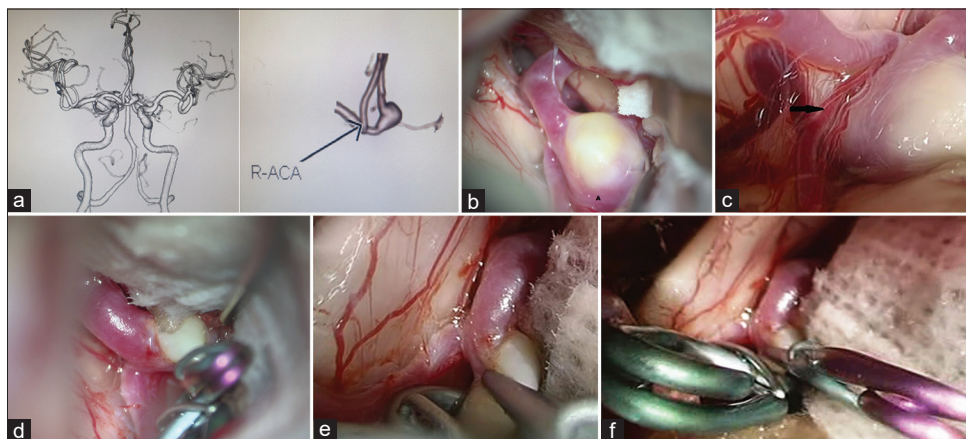


Figure 3: (a) Preoperative three-dimensional computed tomography scan showing anterior communicating aneurysm with the right A1 dominance. (b) Intraoperative microscopic view of aneurysm (a). (c) Intraoperative endoscopic view clearly showing perforator at the neck of aneurysm (shown by black arrow). (d) Intraoperative microscopic view showing two clips applied. (e) Intraoperative endoscopic view showing second clip not across the aneurysm suggestive of incomplete clipping. (f) Intraoperative endoscopic view showing clip position after the second clip readjustment

procedure. In 1930, Tracy Putnam working with the urethroscope described by Mixer, treated a series of children with communicating hydrocephalus through choroid plexus coagulation.<sup>[9]</sup> Fukushima introduced his ventriculofiberscope in 1973. Fukushima<sup>[10]</sup> described three important phases in the development of the application of endoscopic devices. The first phase (from 1910 to 1950s) involved endoscopic diagnosis and coagulation of choroid plexus to treat hydrocephalus; the second phase (initiated in the early 1970) involved the application of flexible fiber endoscopes; and the third phase involves the recent revival of endoscope assisted, minimally invasive surgical procedures.

### Advantages of endoscope in aneurysm surgery

The endoscope with its higher magnification, better observation, and additional illumination can provide us with information that may not be available with the microscope. It can look around corners and allow observation of areas considered blind under the microscope.<sup>[6]</sup>

The endoscope provides a second perspective on the regional anatomic features and enables surgeons to develop a mental three-dimensional image of the aneurysm and its surroundings. During aneurysm surgery, maneuvers such as retraction or unnecessary dissection performed under inadequate microscopic observation can be dangerous. The straight line of view imposed by microscope results in inadequate observation of structures that lie behind the aneurismal sac. The use of endoscope during aneurysm surgery can overcome this “microscopic blind eye” and avoid disastrous complications. During endoscope-assisted aneurysm surgery, the endoscope can be used to inspect hidden structures, dissect perforators at the back of the aneurysm, identify important vessel segments without retraction of the aneurysm or arteries, and check for the completeness of clipping.<sup>[5]</sup>

Perneckzy and Fries enumerated five ways in which microscopic and endoscopic images can be observed at the same time.<sup>[4]</sup> We connect the scope to a three-chip camera and the image is viewed on the monitor placed in front of the surgeon. The microscopic image is simultaneously monitored on a video monitor placed next to the endoscopic image monitor.

### Other authors experience

In our experience, the use of endoscope changed the operative plan in six out of 25 cases (24% cases) of A-com aneurysm. In a series of 54 cases reported by Taniguchi *et al.*,<sup>[11]</sup> the endoscope clarified the detailed additional regional anatomy in 9 cases (16.7%), and the surgeons reapplied the clip on the basis of endoscopic information obtained after the initial clipping in 5 cases (9.3%). In a series of studies by Kalavakonda *et al.*,<sup>[1]</sup> the endoscope was used to observe the clip position in 75 of 79 cases (95%) and anatomic features in 26 (33%). In 15 (19%) aneurysms, key information such

as parent artery, branches, perforators, the neck and back wall of the aneurysm, and completeness of clipping of the neck and inclusion of the parent artery in the clip could be visualized through the endoscope. The clip repositioned because of residual neck or inclusion of the parent artery in six cases, and the clip position was readjusted because of compression of the optic nerve in one case.

In a report by Fischer *et al.*,<sup>[12]</sup> the endoscope was used to gain additional topographic information before clipping in 150 of 180 cases (83%). Depending on the endoscopic findings, rearrangement of the applied clip or additional clipping was found to be necessary in 26 of 130 cases (20%). In recent report by Galzio *et al.*,<sup>[13]</sup> the endoscope provided additional information in 147 cases (71.4%), and clipping under the endoscopic view was done in 42 cases (20.4%). Reapplication of the clip was required in 42 cases (20.4%).

Our study findings coincide with these reports regarding application or readjustment of the clip rate (24%). Our study specifically deals with the use of endoscope in A-com aneurysm, for which no data are available in current literature. Apart from the use of endoscope for inspection of aneurysm, it could be also used for endoscopic ICG video angiography as described by Yoshioka and Kinouchi.<sup>[14]</sup>

### Complications

We encountered no major complication related to the use of endoscope. Taniguchi *et al.*<sup>[11]</sup> encountered one patient with transient oculomotor palsy and one patient with an asymptomatic cerebral contusion in a series of 48 patients with 54 aneurysms. Van Lindert *et al.*<sup>[15]</sup> observed accidental rupture of four aneurysms in a series of 197 aneurysms. Yamada *et al.*<sup>[16]</sup> described the single-center experience for the intraoperative use of endoscope in aneurysm surgery, they did not report any complication related to the use of endoscope. The morbidity in their case series was not related to use the endoscope.

### Disadvantages

Some disadvantages of the endoscope have been reported as follows:<sup>[1]</sup>

(1) the endoscope can cause rupture of the aneurysm during initial inspection, (2) three-dimensional views are not possible, (3) when there is blood in the operative field, the endoscope is useless, (4) there is still a lack of instrumentation specifically designed for endoscopic surgery, and (5) bimanual surgery is impeded when the scope is handheld.

### Conclusion

Simultaneous endoscopic and microscopic guidance can reveal important information hidden from the microscope and it can avoid potential complications. This method increases the safety and durability of the A-com aneurismal clipping.

### Declaration of patient consent

The authors certify that they have obtained all appropriate patient consent forms. In the form the patient(s) has/have given his/her/their consent for his/her/their images and other clinical information to be reported in the journal. The patients understand that their names and initials will not be published and due efforts will be made to conceal their identity, but anonymity cannot be guaranteed.

### Financial support and sponsorship

Nil.

### Conflicts of interest

There are no conflicts of interest.

### References

1. Kalavakonda C, Sekhar LN, Ramachandran P, Hechl P. Endoscope-assisted microsurgery for intracranial aneurysms. *Neurosurgery* 2002;51:1119-26.
2. Fischer J, Mustafa H. Endoscopic-guided clipping of cerebral aneurysms. *Br J Neurosurg* 1994;8:559-65.
3. Apuzzo ML, Heifetz MD, Weiss MH, Kurze T. Neurosurgical endoscopy using the side-viewing telescope. *J Neurosurg* 1977;46:398-400.
4. Perneczky A, Fries G. Endoscope-assisted brain surgery: Part 1-evolution, basic concept, and current technique. *Neurosurgery* 1998;42:219-24.
5. Fries G, Perneczky A. Endoscope-assisted brain surgery: Part 2-analysis of 380 procedures. *Neurosurgery* 1998;42:226-31.
6. Cohen AR. Endoscopic neurosurgery. In: Wilkins RH, Rengachary SS, editors. *Neurosurgery*. New York: McGraw Hill; 1996. p. 539-46.
7. Dandy WE. An operative procedure for hydrocephalus. *Johns Hopkins Hosp Bull* 1922;33:189-90.
8. Mixter WJ. Ventriculoscopy and puncture of the floor of the third ventricle: Preliminary report of a case. *Boston Med Surg J* 1923;188:277-8.
9. Gieger M, Cohen AR. The history of neuroendoscopy. In: Cohen AR, Haines SJ, editors. *Minimally Invasive Techniques in Neurosurgery*. Baltimore: Williams and Wilkins; 1995. p. 1-5.
10. Fukushima T. Endoscope-assisted brain surgery: Part I – Evolution, basic concept, and current techniques. *Neurosurgery* 1998;42:224.
11. Taniguchi M, Takimoto H, Yoshimine T, Shimada N, Miyao Y, Hirata M, *et al.* Application of a rigid endoscope to the microsurgical management of 54 cerebral aneurysms: Results in 48 patients. *J Neurosurg* 1999;91:231-7.
12. Fischer G, Oertel J, Perneczky A. Endoscopy in aneurysm surgery. *Neurosurgery* 2012;70:184-90.
13. Galzio RJ, di Cola F, Raysi Dehcordi S, Ricci A, de Paulis D. Endoscope-assisted microneurosurgery for intracranial aneurysms. *Front Neurol* 2013;4:201.
14. Yoshioka H, Kinouchi H. The roles of endoscope in aneurysmal surgery. *Neurol Med Chir (Tokyo)* 2015;55:469-78.
15. van Lindert E, Perneczky A, Fries G, Pierangeli E. The supraorbital keyhole approach to supratentorial aneurysms: Concept and technique. *Surg Neurol* 1998;49:481-9.
16. Yamada Y, Kato Y, Ishihara K, Ito K, Kaito T, Nouri M, *et al.* Role of endoscopy in multi-modality monitoring during aneurysm surgery: A single center experience with 175 consecutive unruptured aneurysms. *Asian J Neurosurg* 2015;10:52.