

# Petroclival Meningioma: Management Strategy and Results in 21<sup>st</sup> Century

## Abstract

**Background:** Petroclival meningioma (PCM) is considered among the most difficult tumors to be treated by microneurosurgery because of its location and its relation to critical structures. The authors report on the outcome in a series of patients with PCM treated in the new millennium with a tailored approach of gross total excision or subtotal removal and adjuvant Gamma Knife Radiosurgery (GKR) depending on the particular case. **Methods:** Between 2001 and 2017, 72 consecutive PCMs were operated in a single center by the senior surgeon. Clinical presentation, operative approaches, intraoperative findings, complications, and imaging findings were retrospectively analyzed. Postoperative outcome, adjuvant Gamma knife, and follow-up findings were reviewed. **Results:** The average age was 47.95 years, and female-to-male ratio was 52:20. Cavernous sinus extension was present in 21 patients. The mean duration of follow-up was 66.65 months. Gross-total resection, near-total resection (NTR), and subtotal resection (STR) resection was achieved in 30, 24, and 18 (42.8%, 34.28%, and 25%) patients, respectively, with recurrences of 10%, 33%, and 50%, respectively. Twenty-two patients (18 STR and 4 NTR) had received postoperative GKR. Only four patients had recurrences following GKR. New cranial nerve deficits were more common in patients in whom a total resection was performed. There was no mortality. **Conclusions:** Gross total excision had the best recurrence free rate though with a higher morbidity. Upfront GKR is advisable in patients with residual tumor, if the preoperative temporal course had a rapid symptomatology, to reduce recurrence. Wait and watch for a small intracavernous residue and radiosurgery on growth is also a valid option as long as follow-up is not suspect. A flexible approach of individualizing the treatment protocol for a given patient goes a long way toward optimal outcome.

**Keywords:** Current management, gamma knife radiosurgery, meningioma, petroclival

## Introduction

Petroclival meningioma (PCM) presents a formidable challenge for neurosurgeons because of their deep-seated locations and proximity to critical neurovascular structures. Advances in skull base surgery, microneurosurgical techniques, and neuroimaging modalities together with intraoperative neurophysiologic monitoring have led to a reduction in surgical morbidity and mortality rates. Despite advances and the usual benign history of lesions, the incidence of permanent cranial nerve (CN) deficits has been shown to vary from 20.3% to 76% in a number of series [Table 1].<sup>[1-20]</sup> Similarly, the rates of gross total resection (GTR) in the same series vary widely from 28% to 85%, reflecting differing philosophies in the management and surgical radicalness. Recently, most surgeons have tended to move away from radical

resection to preservation of quality of life (QOL).<sup>[2,4-7,9,14,21,22]</sup> Moreover, the availability of stereotactic radiosurgery,<sup>[23]</sup> which has been associated with excellent tumor growth control and progression-free survival rates with a long-term follow-up, has also affected treatment algorithms. Nevertheless, many skull base surgeons continue to advocate aggressive resection whenever possible.<sup>[24]</sup> In cases of smaller tumors, results typically are excellent, and often simple cranial approaches are adequate to ensure total or near-total resection (NTR).<sup>[2]</sup> Larger tumors are much more difficult to treat and often require complex skull base approaches, many of which are rarely performed and are described using unclear terminology. Understanding the natural history, determining the surgical approach, and knowing the radiosurgical results are important in selecting the ideal treatment modality for PCMs. In this context, we

This is an open access journal, and articles are distributed under the terms of the Creative Commons Attribution-NonCommercial-ShareAlike 4.0 License, which allows others to remix, tweak, and build upon the work non-commercially, as long as appropriate credit is given and the new creations are licensed under the identical terms.

For reprints contact: WKHLRPMedknow\_reprints@wolterskluwer.com

**How to cite this article:** Kankane VK, Misra BK. Petroclival meningioma: Management strategy and results in 21<sup>st</sup> century. Asian J Neurosurg 2021;16:89-95.

Submitted: 20-Jul-2020

Revised: 25-Nov-2020

Accepted: 28-Dec-2020

Published: 23-Feb-2021

**Vivek Kumar Kankane, Basant Kumar Misra<sup>1</sup>**

Department of Neurosurgery, G.R. Medical College, JAH Groups of Hospital, Gwalior, Madhya Pradesh, <sup>1</sup>Department Neurosurgery and Gamma Knife Radiosurgery, P.D. Hinduja National Hospital and Medical Research Center, Mumbai, Maharashtra, India

**Address for correspondence:**  
Dr. Basant Kumar Misra,  
Department Neurosurgery and Gamma Knife Radiosurgery,  
P.D.Hinduja National Hospital  
and Medical Research Center,  
Mahim, Mumbai - 400 016,  
Maharashtra, India.  
E-mail: dr\_misra@hindujahospital.com

Access this article online

Website: www.asianjns.org

DOI: 10.4103/ajns.AJNS\_357\_20

Quick Response Code:



**Table 1: Review of literature of surgical outcome in petroclival meningioma**

Authors	Number of patient	Cranial nerve deficit (%)	Mortality rate (%)	Gross total resection (%)
Al-Mefty <i>et al.</i> , 1988	13	31	0	85
Sammi <i>et al.</i> , 1989	24	70	0	71
Spetzler <i>et al.</i> , 1992	18	39	0	78
Bricolo <i>et al.</i> , 1992	33	76	9	79
Couldwell <i>et al.</i> , 1996	109	33	3.7	69
Jung <i>et al.</i> , 2000				
Roberti <i>et al.</i> , 2001	110	47	0.9	45
Little <i>et al.</i> , 2005	137	22.6	0.7	40
Park <i>et al.</i> , 2006	49	30	28.6	20
Bambakidis <i>et al.</i> , 2007	46	30	0	43
Natarajan <i>et al.</i> , 2007	150	20.3	0	32
Seifert, 2010	93	31	0	37
Nanda <i>et al.</i> , 2011	50	32	0	28
Feng Xu <i>et al.</i> , 2013	8	37.5	0	67
Almefty <i>et al.</i> , 2014	64	21	0	64.6
Koutourousio <i>et al.</i> , 2017	17	47.1	0	17.6
J.S. Gosal <i>et al.</i> , 2018	33	33.33	9.09	36.36
Liqiao <i>et al.</i> , 2019	176	19.8	7.3	34.7
Our study	72	19.4	0	42.8

reviewed these issues and discuss the management of PCMs by describing our series of large tumors to demonstrate anatomical and clinical factors that are useful in treatment decision-making.

## Methods

We performed a retrospective analysis of 72 cases involving patients who were treated surgically by the senior author between 2001 and 2017 in the Department of Neurosurgery P. D. Hinduja National Hospital and Medical Research Centre. Clinical presentation [Table 2], tumor histology, operative approaches, intraoperative findings, complications, imaging findings (including magnetic resonance imaging [MRI], magnetic resonance angiography, preoperative computed tomography [CT], and postoperative CT and MRI), Adjuvant Gamma knife, and follow-up findings were reviewed.

## Results

### Clinical characteristics

The patients' average age was 47.95 years. Female-male ratio was 2.6 (52 women and 20 men). The mean duration of follow-up was 66.65 months (range 2 month–144 months). Sixty-seven patients presented *de novo* tumors. Five have recurrent meningioma after having had surgery. Three of these five patients had sizeable residual tumor after resection and four patients had been treated with radiation therapy in addition to resection VIII CN deficit (27 patients, 37.5%), was the most common followed by CN V deficit (22 patients, 30.55%). A summary of the clinical finding at presentation is shown in Table 3.

**Table 2: Clinical findings of petroclival meningioma patients**

Symptoms at presentation	Number of patient (%)
Headache	31 (43.05)
Diplopia	12 (16.66)
Facial numbness	17 (23.61)
Hearing loss	27 (37.5)
Dizziness	6 (8.33)
Gait ataxia	24 (33.33)
Lower cranial nerve symptoms	20 (27.77)

### Radiological and pathological characteristics

The average tumor size was 3.5 cm × 3.2 cm, largest tumor size was 7 cm × 6.8 cm, and the range of tumor size was 2 cm × 1.5–7 cm × 6.8 cm. Cavernous sinus extension was present in 21 patients. Thirty (41.66%) patients had giant tumors (>4 cm). Forty-two (58.33%) patients had large tumors (>2, <4 cm) and no patient had small tumor (<2 cm). Majority of the tumors (91.23%) compressed the brain stem. Forty patients had imaging appropriate to assess extension into the cavernous sinus, jugular foramen, or internal auditory meatus.

Only 9 tumors (12.5%) were WHO Grade II pathology. One tumor (1.38%) was papillary (WHO Grade III), one tumor Anaplastic (WHO Grade III). Rest of the tumors (86.11%) were Grade I. In six of these cases, the patients had undergone prior surgery followed by radiosurgery and 5 (45.45%) of the 11 high-grade tumors were in females.

### Surgical considerations

The authors have modified their philosophy to a tailored approach to preserve function based on brain stem

**Table 3: Preoperative, postoperative and new deficit of cranial nerve**

Cranial number	Preoperative deficit (72 patients) (103 CN)	Postoperative deficit			New deficit (14 CN)	Deficit in mean follow up 66.65 month (20 CN)
		No change (76 CN)	Deterioration (7 CN)	Improvement (20 CN)		
III	1	1	0	0	1	1
IV	0	0	0	0	1	0
V	22	17	1	4	2	6
VI	8	6	1	1	3	5
VII	14	7	3	4	2	4
VIII	27	20	2	5	2	4
IX	16	15	0	1	1	0
X	10	9	0	1	1	0
XI	2	1	0	1	1	0
XII	3	0	0	3	0	0

CN: Cranial nerves

symptoms, patient age, and subarachnoid planes between tumor and brain stem [Figure 1]. The aim of surgery was an attempt at total removal facilitated by adequate exposure, preservation of arterial perforating vessels, special consideration of venous preservation, respecting arachnoid plane, and minimization of CN manipulation.

The approaches used included retrosigmoid (49 patients), transpetrosal (9 patients), combined retrosigmoid and transpetrosal (5 patients), frontotemporoorbitozygomatic (7 patients), and combined retrosigmoid and far-lateral (2 patients) [Figure 2]. Treatment was chosen primarily using an algorithm that includes assessment of preoperative hearing status and tumor location relative to the internal auditory canal and to the tentorium [Figure 3].

Different surgical approaches have been used to expose and remove the tumors depending on the location and epicenter of the tumor, direction of tumor extension, tumor size, patient's age, medical comorbidities, and proposed extent of resection. We selected the retrosigmoid approach for majority of the patients, as a safe alternative to lateral approaches. Combined with tentorial incision or suprameatal drilling, it can be safely used for almost every PCM surgery.

### Extent of resection

In 72 patients, the operative reports allowed the evaluation of extent of resection. Tumor removal was classified based on the postoperative contrast-enhanced MRI, and GTR was considered to be achieved if there was no enhancement present and at operation resection was considered a GTR in cases of gross microsurgical removal along with dural coagulation and/or removal. An NTR was considered to correspond to >90% resection shown on postoperative imaging and usually correlated to the surgeon's intraoperative impression that all macroscopic tumors had been removed. The results of GTR and NTR were thought to correspond to Simpson Grade III and IV, respectively. GTR was achieved in 30 (41.6%) of 72 patients, NTR

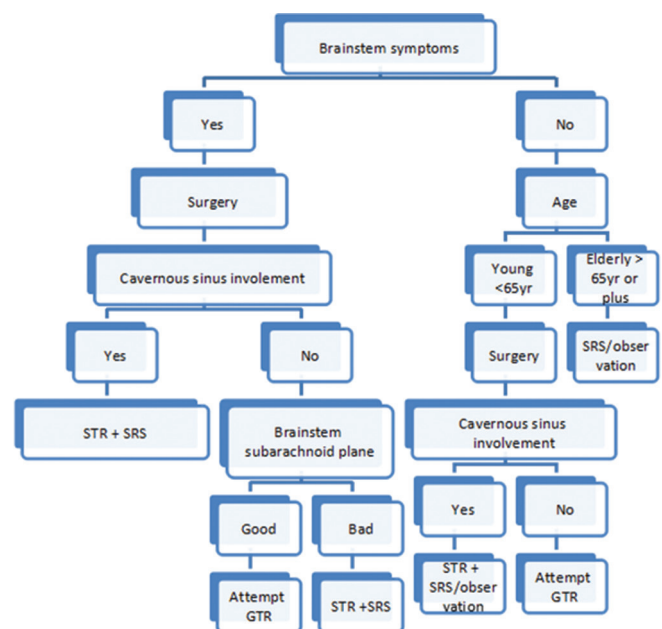


Figure 1: Management algorithm for petroclival meningioma

was achieved in 24 (33.33%) patients, and subtotal resection (STR) was achieved in 18 (25%) patients. New CN deficits occurred in 14 patients (19.4%) and were more common in patients in whom a total resection was performed.

### Recurrence

There were twenty recurrences for an overall recurrence rate of 27.77%. There were three recurrences (10%) in the thirty patients who underwent GTR, 8 recurrences (33.33%) in 24 patients who underwent NTR, Nine recurrences (50%) in 18 patients who underwent STR.

### Clinical outcome

There was no operative mortality. There were five patients operated multiple times. Four patients' recurred despite two times of Gamma Knife treatment. Total 22 patients had received Gamma knife radiosurgery (GKR) for residual or

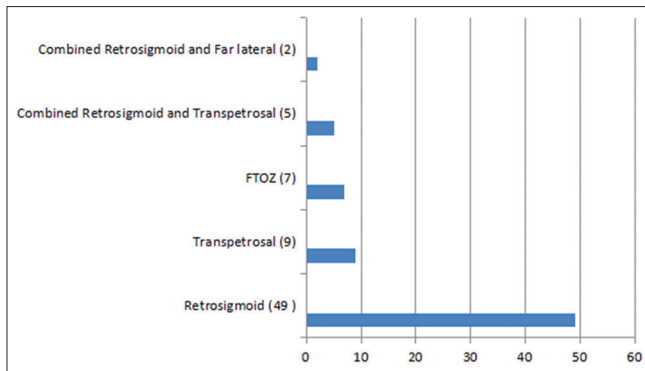


Figure 2: Different surgical approaches

recurrence after surgery, 18 patients had not recurred after Gamma Knife and 4 patients had recurrence after Gamma Knife.

### Cranial nerve

Thirty-two (44.44%) of the 72 patients had deficits of one or more CNs preoperatively. At a mean follow-up of 66.65 months 20 (27.77%) patients had persistent CN deficits. CNs VII and V were more likely to improve from preoperative status, while CN VI was the most at risk for permanent deficit. Immediate postoperative improvement occurred in 20 CNs only [Table 3]. New CN deficits were more common in patients in whom a total resection was performed and occurred immediately postoperatively in 14 patients. When new or worsened CN deficits were analyzed in relation to grade of resection, there were markedly fewer CN deficits in patients with NTR or subtotal removal followed by Gamma Knife and there was better improvement in this group on follow-up.

### Complications

Two patients suffered postoperative cerebrospinal fluid (CSF) otorrhea needing repair. One patient had pontine hemorrhage and four patients developed postoperative hydrocephalus requiring insertion of ventriculoperitoneal Shunt. Tarsorrhaphy was done in one patient.

### Discussion

Up to 1970, PCMs were considered inoperable; as only 10 of the 26 patients reported in the literature survived surgery and only one had a total excision.<sup>[25]</sup> Parallel advances in microneurosurgery and the introduction of innovative skull-base approaches in the late 1980s led to a renewed enthusiasm about radical excision of PCMs and several successful series were published.<sup>[1,3,13,15,26-28]</sup> Many neurosurgeons practicing skull base surgery (including this author) were carried away by the possibility of total excision with a very low mortality rate and a great postoperative scan and accepted the accompanying morbidity as inevitable. Only a few wise men dared to question this approach lest they be frowned upon as incompetent.<sup>[29]</sup>

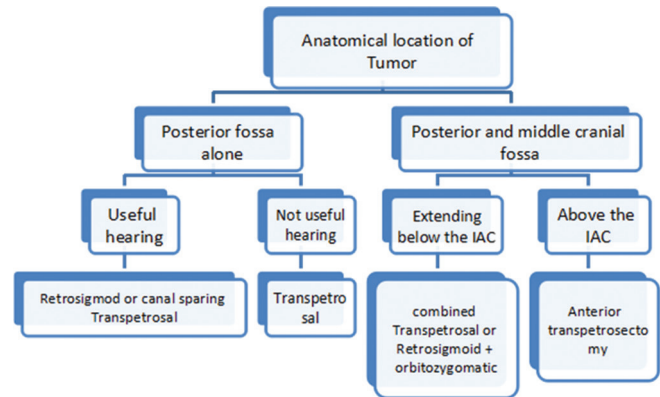


Figure 3: Algorithm illustrating important considerations in determining surgical approaches for petroclival meningioma

Total excision, including the dural attachment and bone (Simpson Grade I), is rarely possible in patients with PCMs, especially. By the time patients present to the surgeon, most PCMs have reached a large size with a wide attachment, and the tumor often invades the exit foramina of multiple CNs. Total excision of the tumor with its dura and bony attachment is not possible in such cases without significant risks and unacceptable morbidity. In several cases, the difficulty of excision is further compounded by arterial and brain stem involvement.<sup>[7,25-30]</sup>

A review of the literature clearly demonstrates the trend toward less radical surgery and an emphasis on the functional outcome, as reported in various series [Table 1]. The total excision rates dropped over the years from a high of 70%–80% to the low 40%. The total excision rates in the earlier literature reported by Samii *et al.*,<sup>[13]</sup> Al Mefty and Smith,<sup>[31]</sup> Misra *et al.*,<sup>[28]</sup> Kawase *et al.*,<sup>[27]</sup> and Bricolo *et al.*,<sup>[3]</sup> were 71%, 83%, 82%, 70%, and 79%, respectively. The total excision rates for PCMs in the recent reported series are much lower: 20% by Jung *et al.*,<sup>[21]</sup> 40% by Little *et al.*,<sup>[5]</sup> and 41% by Mathiesen *et al.*<sup>[22]</sup> The total excision rate in the series of Sekhar *et al.*<sup>[7,26]</sup> dropped from a high of 78% in 1990 to 32% in 2007. Similarly, the group from Barrow Neurological Institute reported a total excision rate of 91% in 1992 but only 43% in 2007.<sup>[2,15]</sup> The trend toward a less radical approach in almost all recent series is aimed at a better QOL for the patient. That this attempt is successful is proven by lower postoperative morbidity rates reported in the recent series. The authors had a similar experience, operating on 124 patients with PCMs, mostly large and giant, between 1988 and 2017. A comparison of postoperative function of patients in our series between those operated on before 2001 (radical approach) and those operated on in 2001 or later (safe excision) demonstrated that the morbidity was significantly lower in the latter group [Figure 4].

The growth rate of subtotally resected PCMs without adjunct treatment seems to be low, and there is a suggestion that recurrence and growth rates are higher if a large residual tumor is left behind and in younger patients.<sup>[5,7,21]</sup>



The recurrence rate after complete and incomplete excision was almost the same, 4% and 5%, respectively, in the series of Natarajan *et al.*,<sup>[7]</sup> although a large number of patients with incomplete resection had adjunct radiation. In summary, many committed skull-base surgeons have a significant number of patients with PCMs in their series who undergo subtotal excision, resulting in reduced overall postoperative morbidity. The recurrence rate after near-total or subtotal excision is not alarming.

A moderate-sized PCM with a good plane of cleavage from the adjacent neurovascular structures and without a wide attachment can and should be totally excised. A planned subtotal excision is the way to go when the imaging findings suggest an excessive adhesiveness of neurovascular structures, a pial breach, brain stem edema, or a wide en plaque attachment of the tumor involving the exit foramina of multiple CNs. Similarly, the author recommends leaving an intracavernous extension of the tumor. Despite all the recent advances in imaging, surprises during surgery are not uncommon and a seemingly difficult meningioma can occasionally be totally excised.

Different surgical approaches have been used to expose and remove the tumors according to the location of the

epicenter of the tumor, direction of tumor extension, tumor size, patient age, medical comorbidity, and proposed radicality of resection. Personal experience, preferences, and the microneurosurgical technique can also affect the choice of surgical approach. We selected the retrosigmoid approach for majority of the patients, as a safe alternative to lateral approaches. A comparative evaluation of major approaches can be summarized in Table 4.

Although the combined transpetrosal approach provides a wider surgical field, it also has several disadvantages including increased risk of postoperative CSF leakage, damage to the facial nerve and functional hearing, temporal lobe retraction, increased risk of injury to the vein of Labbé, and increased operative time. The retrosigmoid approach can provide equivalent working area and angles of attack for petroclival lesions compared with a combined transpetrosal approach.<sup>[32]</sup> Furthermore, it has been shown that the retrosigmoid approach provides a significantly larger clival and brain stem working area than Kawase's approach.<sup>[33]</sup> Although using cerebellar retraction is a potential risk factor for intraoperative edema and cerebellar infarction, we have never encountered any such problem so far.

### The role of radiosurgery

Radiosurgery has become an accepted modality of treatment for patients with PCMs, both as an adjunct to microsurgery and as a primary modality.<sup>[7,12,21,22,34-39]</sup> Long-term follow-up data confirm the tumor control rate of more than 90% reported in earlier series with shorter follow-up. Zachenhofer *et al.*<sup>[38]</sup> reported a tumor control rate of 94% in patients with skull base meningiomas treated with GKR after a mean follow-up of 103 months. Tumor shrinkage and clinical improvement continued during the longer follow-up period. Kreil *et al.*<sup>[35]</sup> reported long-term follow-up of one of the largest series of benign skull-base meningiomas treated with GKR. In a series of 200 patients

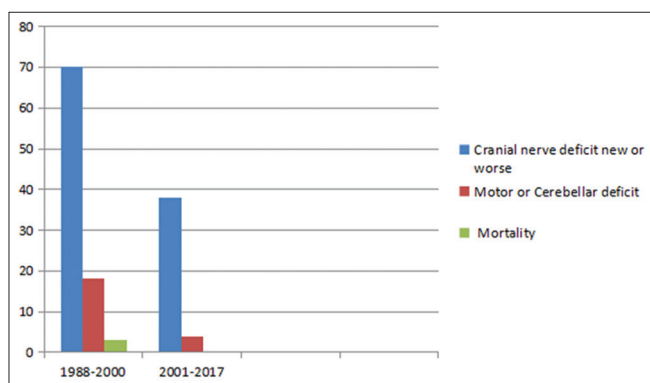


Figure 4: Trend in complications after microsurgery in the author's series

Table 4: A comparative evaluation of different surgical approaches to petroclival meningiomas

Combined transpetrosal approach	The presigmoid transpetrosal approach	Retrosigmoid approach
<p>Advantage: Much wider vision and shorter distance to access to the petroclival area, when they significantly grow equally into both the middle and posterior fossae</p> <p>Disadvantage: Advanced anatomic knowledge and surgical training. Timeconsuming, may cause more morbidities due to a large surgical wound, also increases a potential risk of injury to the vein of Labbe</p>	<p>Advantage: An extensive view of surgical field, short route lateral access, wide exposure of CNs and main arteries of posterior circulation and higher preservation chance of the vein of Labbe</p> <p>Disadvantage: Advanced anatomic knowledge and surgical training. Timeconsuming, may cause more morbidities due to a large surgical wound</p>	<p>Advantage: Lesser morbidity, familiarity and less time consumption, abundant exposure of operative sight without more traction of cerebellum and venous sinuses. Can be combined with suprameatal drilling and tentorial cutting to gain extended exposure to the whole region of clivus from dorsum sellae to foramen magnum region and middle fossa</p> <p>Disadvantage: The tumor could not be resected just only by this approach when the main part of tumor located at middle cranial fossa, or invaded into cavernous sinus, especially invading the internal structures of cavernous sinus. The resection of tumor was mainly achieved through numerous neurovascular intervals; therefore the risk of iatrogenic injury of neurovascular structures was relative higher</p>

CNs: Cranial nerves

with a follow-up of 5–12 years, 99 were treated with a combination of microsurgery and GKR and 101 patients underwent primary GKR. The authors reported an actuarial progression-free survival rate of 98.5% at 5 years and 97.2% at 10 years.<sup>[12]</sup> The neurologic status improved in 41.5%, remained unaltered in 54%, and deteriorated in 4.5% of patients, whereas only five patients (2.5%) required repeat microsurgical resection. In our series, a total of 22 patients had received GKR for residual or recurrence after surgery. There was no recurrence in 18 patients, and 4 patients had recurrence after GKR.

The authors do not generally favor primary radiosurgery for PCM because there is the possibility of a wrong diagnosis and the inability to grade the tumor. However, the authors have advised primary GKR in selected patients with a classic imaging morphology, especially in elderly or medically infirm patients with progressive CN deficits and a small-volume tumor based on the bone and dura or presenting en plaque.

Radiosurgery is not without risk either. The two main concerns are neurologic worsening and the risk of malignancy. Radiation-induced worsening is often delayed, requires active medication, and hence, requires long-term follow-up. Tissue tolerance to radiosurgery is often dose dependent, and recent series show that lower dose treatment has reduced the complication rates significantly.<sup>[22,35,37-40]</sup> Thus, it is critical that the tumor volume is reduced through safe microsurgery, the brainstem is decompressed, and any small residual volume is treated with radiosurgery to achieve the optimal outcome.<sup>[22,34,41]</sup> Facial pain was the most common new symptom after radiosurgery. The risk of malignant transformation following radiosurgery is there but small.

## Conclusions

Gross total excision had the best recurrence-free rate though with a higher morbidity. Upfront GKR is advisable in patients with residual tumor, if the preoperative temporal course had a rapid symptomatology, to reduce recurrence. Wait and watch for a small intracavernous residue and radiosurgery on growth is also a valid option as long as follow-up is not suspect. A flexible approach of individualizing the treatment protocol for a given patient goes a long way toward optimal outcome.

## Financial support and sponsorship

Nil.

## Conflicts of interest

There are no conflicts of interest.

## References

- Al-Mefty O, Fox JL, Smith RR. Petrosal approach for petroclival meningiomas. *Neurosurgery* 1988;22:510-7.
- Bambakidis NC, Kakarla UK, Kim LJ, Nakaji P, Porter RW, Daspt CP, *et al.* Evolution of surgical approaches in the treatment of petroclival meningiomas: A retrospective review. *Neurosurgery* 2007;61(5 Suppl 2):202-11.
- Bricolo AP, Turazzi S, Talacchi A, Cristofori L: Microsurgical removal of petroclival meningiomas: A report of 33 patients. *Neurosurgery* 1992;31:813-28.
- Couldwell WT, Fukushima T, Giannotta SL, Weiss MH. Petroclival meningiomas: Surgical experience in 109 cases. *J Neurosurg* 1996;84:20-8.
- Little KM, Friedman AH, Sampson JH, Wanibuchi M, Fukushima T. Surgical management of petroclival meningiomas: Defining resection goals based on risk of neurological morbidity and tumor recurrence rates in 137 patients. *Neurosurgery* 2005;56:546-59.
- Nanda A, Javalkar V, Banerjee AD. Petroclival meningiomas: Study on outcomes, complications and recurrence rates. *Clinical article. J Neurosurg* 2011;114:1268-77.
- Natarajan SK, Sekhar LN, Schessel D, Morita A. Petroclival meningiomas: Multimodality treatment and outcomes at longterm follow-up. *Neurosurgery* 2007;60:965-81.
- Park CK, Jung HW, Kim JE, Paek SH, Kim DG. The selection of the optimal therapeutic strategy for petroclival meningiomas. *Surg Neurol* 2006;66:160-6.
- Ramina R, Neto MC, Fernandes YB, Silva EB, Mattei TA, Aguiar PH. Surgical removal of small petroclival meningiomas. *Acta Neurochir (Wien)* 2008;150:431-9.
- Rhoton AL Jr. The temporal bone and transtemporal approaches. *Neurosurgery* 2000;47(3 Suppl):S211-65.
- Roberti F, Sekhar LN, Kalavakonda C, Wright DC. Posterior fossa meningiomas: Surgical experience in 161 cases. *Surg Neurol* 2001;56:8-21.
- Roche PH, Pellet W, Fuentes S, Thomassin JM, Régis J. Gamma knife radiosurgical management of petroclival meningiomas results and indications. *Acta Neurochir (Wien)* 2003;145:883-8.
- Samii M, Ammirati M, Mahrn A, Bini W, Sepehrnia A. Surgery of petroclival meningiomas: Report of 24 cases. *Neurosurgery* 1989;24:12-7.
- Seifert V. Clinical management of petroclival meningiomas and the eternal quest for preservation of quality of life: Personal experiences over a period of 20 years. *Acta Neurochir (Wien)* 2010;152:1099-116.
- Spetzler RF, Daspt CP, Pappas CT. The combined supra- and infratentorial approach for lesions of the petrous and clival regions: Experience with 46 cases. *J Neurosurg* 1992;76:588-99.
- Xu F, Karamelas I, Megerian CA, Selman WR, Bambakidis NC. Petroclival meningiomas: An update on surgical approaches, decision making, and treatment results. *Neurosurg Focus* 2013;35:E11.
- Almefty R, Dunn IF, Pravdenkova S, Abolfotoh M, Al-Mefty O. True petroclival meningiomas: Results of surgical management. *J Neurosurg* 2014;120:40-51.
- Koutourousiou M, Fernandez-Miranda JC, Vaz-Guimaraes Filho F, de Almeida JR, Wang EW, Snyderman CH, *et al.* Outcomes of endonasal and lateral approaches to petroclival meningiomas. *World Neurosurg* 2017;99:500-17.
- Gosal JS, Behari S, Joseph J, Jaiswal AK, Sardhara JC, Iqbal M, *et al.* Surgical excision of large-to-giant petroclival meningiomas focusing on the middle fossa approaches: The lessons learnt. *Neurol India* 2018;66:1434-46.
- Qiao L, Yu C, Zhang H, Zhang M, Qu Y, Ren M, *et al.* Clinical outcomes and survival analysis for petroclival meningioma patients receiving surgical resection: An analysis of 176 cases. *Cancer Manag Res* 2019;11:5949-59.

21. Jung HW, Yoo H, Paek SH, Choi KS. Long-term outcome and growth rate of subtotally resected petroclival meningiomas: Experience with 38 cases. *Neurosurgery* 2000;46:567-75.
22. Mathiesen T, Gerlich A, Kihlström L, Svensson M, BaggerSjöbäck D. Effects of using combined transpetrosal surgical approaches to treat petroclival meningiomas. *Neurosurgery* 2007;60:982-92.
23. Flannery TJ, Kano H, Lunsford LD, Sirin S, Tormenti M, Niranjana A, *et al.* Long-term control of petroclival meningiomas through radiosurgery. *J Neurosurg* 2010;112:957-64.
24. Erkmen K, Pravdenkova S, Al-Mefty O. Surgical management of petroclival meningiomas: Factors determining the choice of approach. *Neurosurg Focus* 2005;19:E7.
25. Misra BK. Intracranial meningioma. In: Ramamurthi B, Tandon PN, editors. *Textbook of Neurosurgery*, 2<sup>nd</sup> ed. New Delhi: Churchill Livingstone; 1996. p. 1077-110.
26. Sekhar LN, Jannetta PJ, Burkhart LE, Janosky JE. Meningiomas involving the clivus: A six-year experience with 41 patients. *Neurosurgery* 1990;27:764-81.
27. Kawase T, Shiobara R, Toya S. Anterior transpetrosal-transtentorial approach for sphenopetroclival meningiomas: Surgical method and results in 10 patients. *Neurosurgery* 1991;28:869-75.
28. Misra BK, Rout D, Rao VR, Rout A. Petroclival Meningioma: Surgical Experience with 11 Cases. Abstracts. 40<sup>th</sup> Annual Conference, Neurological Society of India, Manipal, India; 1991. p. 25.
29. Ojemann RG. Skull-base surgery: A perspective. *J Neurosurg* 1992;76:569-70.
30. Adachi K, Kawase T, Yoshida K, Yazaki T, Onozuka S. ABC surgical risk scale for skull base meningioma: A new scoring system for predicting the extent of tumor removal and neurological outcome. Clinical article. *J Neurosurg* 2009;111:1053-61.
31. Al Mefty O, Smith RR. Clival and petroclival meningiomas. In: Al-Mefty O, editor. *Meningiomas*. New York: Raven Press; 1991. p. 517-37.
32. Siwanuwatn R, Deshmukh P, Figueiredo EG, Crawford NR, Spetzler RF, Preul MC. Quantitative analysis of the working area and angle of attack for the retrosigmoid, combined petrosal, and transcochlear approaches to the petroclival region. *J Neurosurg* 2006;104:137-42.
33. Chang SW, Wu A, Gore P, Beres E, Porter RW, Preul MC, *et al.* Quantitative comparison of Kawase's approach versus the retrosigmoid approach: Implications for tumors involving both middle and posterior fossae. *Neurosurgery* 2009;64:44-51.
34. Misra BK. Management of central skull base tumors. In: Sindou M, editor. *Practical Handbook of Neurosurgery: From Leading Neurosurgeons*, Vol. 2. New York: Springer; 2009. p. 115-28.
35. Kreil W, Luggin J, Fuchs I, Weigl V, Eustacchio S, Papaefthymiou G. Long term experience of gamma knife radiosurgery for benign skull base meningiomas. *J Neurol Neurosurg Psychiatry* 2005;76:1425-30.
36. Iwai Y, Yamanaka K, Ikeda H. Gamma knife radiosurgery for skull base meningioma: Long-term results of low-dose treatment. *J Neurosurg* 2008;109:804-10.
37. Takanashi M, Fukuoka S, Hojyo A, Sasaki T, Nakagawara J, Nakamura H. Gamma knife radiosurgery for skull-base meningiomas. *Prog Neurol Surg* 2009;22:96-111.
38. Zachenhofer I, Wolfsberger S, Aichholzer M, Bertalanffy A, Roessler K, Kitz K, *et al.* Gamma-knife radiosurgery for cranial base meningiomas: Experience of tumor control, clinical course, and morbidity in a follow-up of more than 8 years. *Neurosurgery* 2006;58:28-36.
39. Misra BK. Surgical approaches to petroclival region. *Prog Clin Neurosci* 1999;14:183-92.
40. Morita A, Coffey RJ, Foote RL, Schiff D, Gorman D. Risk of injury to cranial nerves after gamma knife radiosurgery for skull base meningiomas: Experience in 88 patients. *J Neurosurg* 1999;90:42-9.
41. Misra BK. Management of petroclival meningioma: The role of excision and radiosurgery. In: Al-Mefty O, editor. *Controversies in Neurosurgery II*. 2<sup>nd</sup> ed. New York: Thieme Publishers; 2014. p. 30-6.