Article published online: 2022-08-16

Case Report

Fatal Subarachnoid Hemorrhage: A Rare Presentation of Ruptured A2 Dissecting Aneurysm

Abstract

Anterior cerebral artery dissection (ACAD), especially simultaneously presenting with subarachnoid hemorrhage (SAH) and cerebral infarction (CI), is rare. Only a few cases of severe SAH due to ACAD have been reported. Herein, we present an unusual case of severe SAH with simultaneous CI caused by ACAD. A 56-year-old male was brought to our hospital for severe disturbance of consciousness. Head computed tomography (CT) disclosed SAH with intracerebral hematoma. We suspected ruptured anterior communicating artery saccular aneurysm on CT angiography. Emergency craniotomy was performed to avoid cerebral herniation which confirmed the ruptured ACAD of right A2. The dissecting site was treated by wrapping with a Goretex sheet. ACAD of A2 may present with a severe hemorrhagic event.

Keywords: *A2 dissecting aneurysm, fatal subarachnoid hemorrhage, Goretex sheet, wrapping*

Shigeomi Yokoya, Ayaka Ogata, Akihiko Hino, Sho Nishii, Yukihiro Goto, Hideki Oka, Naoto Shiomi

Department of Neurosurgery, Saiseikai Shiga Hospital, Imperial Gift Foundation Inc., Shiga, Japan

Introduction

Anterior cerebral artery dissection (ACAD) is rare and comprises 5% of cases of spontaneous dissection of an intracranial artery. The most common onset presentation is with ischemia alone. Onset accompanied with ischemia and subarachnoid hemorrhage (SAH) is rare.[1,2]

In cases of concurrent cerebral infarction (CI) and SAH, dissection often occurs at the distal part of anterior cerebral artery (ACA) after vertical segment of the ACA (A2), and SAH tends to be minor.[1,3] A few patients with severe SAH combined with ischemia because of ACAD have been reported. We report a rare case of ruptured A2 dissecting aneurysm presenting with fatal SAH and ischemia. Because of an impending cerebral herniation, we did not perform digital subtraction angiography (DSA) and rushed the patient to the operation room. We assumed the rupture point to be an anterior communicating artery (Acom) saccular aneurysm and intended to perform direct clipping through left frontotemporal craniotomy. However, intraoperative examination revealed that right A2 dissection caused the fatal SAH. An antegrade flow was confirmed at the dissected site. The dissected A2 was treated by wrapping it with a Goretex sheet. We discuss the failure of direct clipping through frontotemporal craniotomy, which is a rescue maneuver.

Case Report

A 56-year-old male with hypertension and a history of resected pituitary adenoma was admitted to our hospital because of disturbance of consciousness. On admission, he showed decerebrate rigidity and anisocoria with dilation of the left pupil. His Glasgow Coma Scale score was 4. Initial computed tomography (CT) demonstrated large intracerebral hematoma (ICH) at the left anterior skull base with SAH [Figure 1]. A saccular aneurysm was suspected at the junction of the right horizontal portion of the ACA (A1) and the vertical segment of the ACA (A2) on CT angiography (CTA) [Figure 2]. The poor demonstration of intracranial arteries on CT led to a diagnosis of high intracranial pressure (ICP). Because of impending cerebral herniation, we skipped cerebral angiography and performed urgent decompressive craniotomy.

Through left frontotemporal craniotomy, ICH was evacuated, and the Acom

Address for correspondence:
Dr. Shigeomi Yokoya, 2-4-1 Ohashi, Ritto-City, Shiga 520-3046, Japan. E-mail: yokoya@ks.kyorin-u.ac.jp

Access this article online

Website: www.asianjns.org

DOI: 10.4103/ajns.AJNS_337_19

Quick Response Code:

How to cite this article: Yokoya S, Ogata A, Hino A, Nishii S, Goto Y, Oka H, *et al*. Fatal subarachnoid hemorrhage: A rare presentation of ruptured A2 dissecting aneurysm. Asian J Neurosurg 2020;15:418-20.

Submitted: 14-Nov-2019 **Revised:** 15-Jan-2020
Accepted: 31-Mar-2020 **Published:** 29-May-2020

complex was exposed. No saccular aneurysm was found in both right and left A2, and no vascular abnormality was observed in the left A2, but a dissecting aneurysm of the right A2 was recognized with an enlarged and dark red vessel wall [Figure 3 left]. We considered that the vessel tear due to arterial dissection was present on the left side wall of the right A2, which caused ICH and SAH in the left frontal lobe.

Patency of the right A2 was confirmed intraoperatively using an ultrasound Doppler flow meter. We stopped trapping the ruptured site, traced A2, and confirmed the end of the ACAD, where the anterior internal frontal artery arose from. We tried "wrapping on clipping" using the Goretex sheet (GORE® PRECLUDE®, W. L. Gore and Associates, Inc. Newark, Delaware, USA), which was placed circumferentially at the ACAD site, and a right-angled aneurysm clip was positioned to fix the Goretex sheet. However, the Goretx sheet could not be fixed tightly. The Goretex sheet was fixed with 8-0 nylon suture to avoid slipping [Figure 3 right]. Postoperative DSA demonstrated patency of the right ACA [Figure 4].

Immediately after the operation, CT showed CI in the right ACA territory [Figure 5]. ACAD simultaneously presenting with SAH and CI was diagnosed. Postoperatively, intracranial hemorrhage did not occur again but caused permanent disturbance of consciousness and left hemiparesis. The patient was transferred to an affiliated hospital with a modified Rankin scale score of 5.

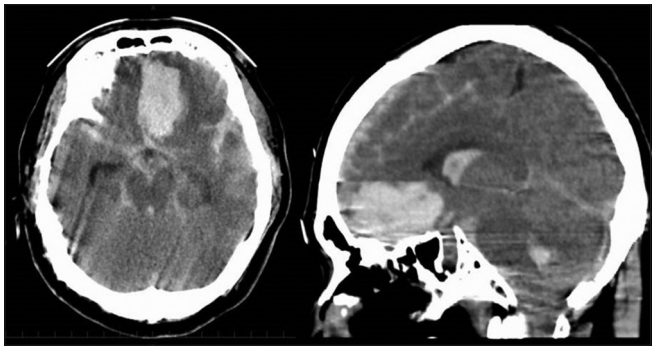

Figure 1: Preoperative computed tomography. CT scans demonstrating a subarachnoid hemorrhage (CT) on admission with a large intracerebral hematoma in the left frontal lobe

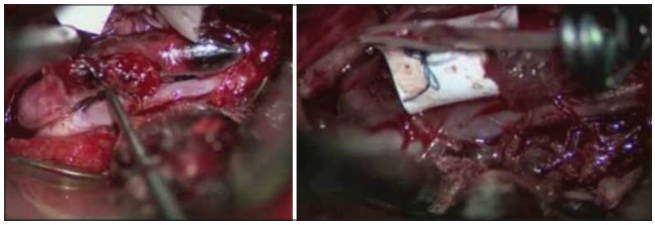

Figure 3: Intraoperative photograph. Intraoperative photograph revealing a dissecting aneurysm in the right A2 portion (left). The ruptured site was treated with "wrapping on clipping" using the Goretex sheet (right). Note that the 8-0 nylon suture has been positioned to fixed the Goretex sheet

Discussion

This case presents three clinical suggestions. First, ACAD in the A2 portion would present with severe SAH and a huge hematoma. Intraoperative findings and postoperative CT, in this case, confirmed that a dissecting aneurysm of the right A2 caused fatal SAH with CI. Previous reports suggested that a hemorrhagic event of ACAD tends to occur from the A1 segment and ischemic event, including simultaneous ischemia and hemorrhage cases, from a more peripheral portion of the ACA after A2.[1,3] This is why the pathological condition is usually divided between A1 and the distal segment of the ACA after A2. In other words, as A1 is relatively centrally located, high intravascular pressure and heavy blood flow are associated with severe bleeding. Examination of autopsy cases of fatal SAH demonstrated that only one (0.9%) of 111 dissection cases was caused by ruptured ACAD, and the ruptured site was the A1 portion.[4] Conversely, the peripheral portion of the ACA

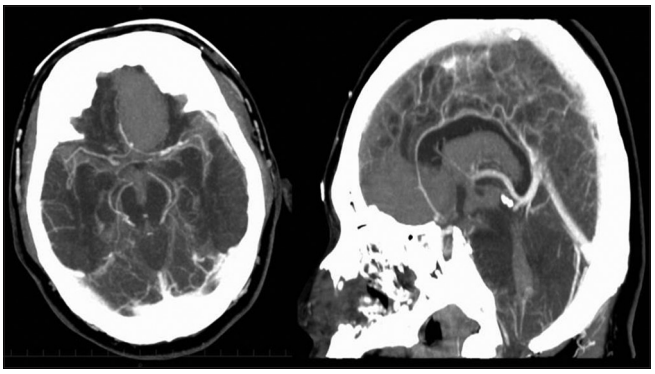

Figure 2: Preoperative maximum intensity projection (MIP) image of computed tomography angiography (CTA). MIP image of CTA demonstrating a small saccular vasculature in the A1–A2 junction. The vascular structure is in contact with the large hematoma

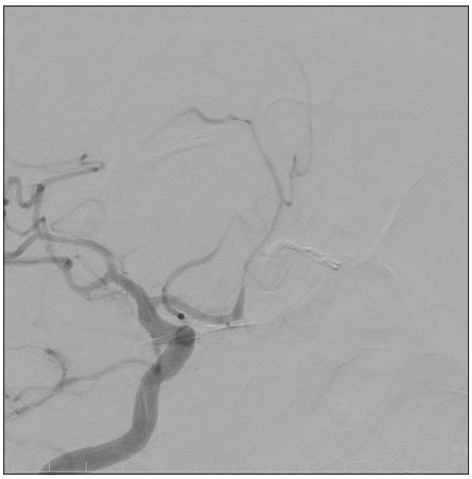

Figure 4: Postoperative digital subtraction angiography (DSA). DSA, performed postoperatively, showing the patency of the right anterior cerebral artery beyond the dissecting aneurysm which was subsequently treated via surgical clipping

Figure 5: Postoperative computed tomography (CT) scan. Postoperative CT scan demonstrating a low-density area in the right anterior cerebral artery territory

after A2 caused slight hemorrhage because of the low intravascular pressure and little blood flow.

Second, we should have chosen the interhemispheric approach if we were not able to evaluate the detailed image before the surgery and make a definitive diagnosis. It is easy to manage an unexpected blood vessel lesion while using the interhemispheric approach. In this case, brain herniation due to hematoma was imminent. We should prioritize decompressive craniotomy over identification of the rupture point and preventive measures for rebleeding. We did not have time to perform cerebral angiography for detailed vascular lesion examination. Based on the three-dimensional-CTA findings (CTA image was poor due to increased ICP), we assumed rupture of the saccular aneurysm at the junction of the right A1 and A2 and performed emergency frontotemporal craniotomy. From the intraoperative findings, we determined that the dissecting aneurysm of the A2 portion was the source of the hemorrhage. To identify the end of the dissecting aneurysm, we needed to retract the brain. If we chose the interhemispheric approach, we could also have chosen a surgical option, such as trapping with A3–A3 bypass.

Theoretically, superficial temporal artery (STA)–ACA bypass is an option as a procedure for revascularization of the ACA. However, we did not choose to perform STA–ACA bypass in this situation. Performing STA–ACA bypass in this situation would require many procedural steps: repositioning the head, shaving of the hair, disinfecting, draping again, dissecting the STA, and the addition of a new craniotomy. It was difficult to perform such extra procedures intraoperatively; therefore, we decided to perform wrapping on the ruptured site.

Third, wrapping with the Goretex sheet is an effective treatment measure. In this case, the ACA territory had already infarcted on CT immediately after the operation. Therefore, A2 trapping was sufficient as the treatment. However, intraoperative Doppler flowmeter showed antegrade blood flow of the dissected right A2. It was necessary to maintain the blood flow of A2 and wrap the dissecting portion with a Goretex sheet.

A Goretex sheet is often prepared as an artificial dura mater and can be used easily in an emergency operation. The Goretex sheet is strong and has low reactivity with tissues and good stability.[5] However, there is a disadvantage of a gap between the Goretex sheet and the aneurysm wall, which tends to cause reduction in adhesion, and the sheet slips out. It has low affinity to blood vessel walls and fibrin glue. As the sheet slipped, and the dissection site could not be fixed with the aneurysm clip, we fixed the sheet with a 8-0 nylon suture.

Conclusions

Clinicians should consider the possibility of ACA dissecting aneurysms of A2 or ACA located distal to A2 even when the patient has serious SAH. In such unexpected situations, we need to overcome the difficulties using alternative maneuvers.

Declaration of patient consent

The authors certify that they have obtained all appropriate patient consent forms. In the form the patient(s) has/have given his/her/their consent for his/her/their images and other clinical information to be reported in the journal. The patients understand that their names and initials will not be published and due efforts will be made to conceal their identity, but anonymity cannot be guaranteed.

Financial support and sponsorship

Nil.

Conflicts of interest

There are no conflicts of interest.

References

1. Uozumi Y, Katoh H, Tsuzuki N, Toyooka T, Miyazawa T, Nawashiro H, *et al*. Revascularization for anterior cerebral artery dissecting aneurysms – Three case reports. Neurol Med Chir (Tokyo) 2010;50:49-53.
2. Hensler J, Kondering JU, Ulmer S, Jansen O. Spontaneous dissections of the anterior cerebral artery: A meta-analysis of the literature and three recent cases. Neuroradiology 2016;58:997-1004.
3. Ohkuma H, Suzuki S, Kikkawa T, Shimamura N. Neuroradiologic and clinical features of arterial dissection of the anterior cerebral artery. AJNR Am J Neuroradiol 2003;24:691-9.
4. Mori S, Takahashi S, Hayakawa A, Saito K, Takada A, Fukunaga T. Fatal intracranial aneurysms and dissections causing subarachnoid hemorrhage: An epidemiological and pathological analysis of 607 legal autopsy cases. J Stroke Cerebrovasc Dis 2018;27:486-93.
5. Bederson JB, Zabramski JM, Spetzler RF. Treatment of fusiform intracranial aneurysms by circumferential wrapping with clip reinforcement. Technical note. J Neurosurg 1992;77:478-80.