

Familial Colloid Cysts of the Third Ventricle: Case Report and Literature Review

Abstract

Colloid cysts of the third ventricle are rare lesions. To our knowledge, only 23 familial cases of colloid cysts have been reported in the literature. The country of origin of the patients with familial cases had not been previously studied as a group. A 49-year-old female patient from Puerto Rico and her 21-year-old daughter underwent surgical resection for colloid cysts within a period of 5 years. The daughter presented with symptomatic hydrocephalus, while the mother only had mild chronic headaches. The occurrence of a colloid cyst in this family prompted us to perform a literature review and tabulate all the familial cases. This report presents the 24th case of a familial colloid cyst, and the fourth involving a mother and daughter. Australia is the country with the largest amount of reported cases. For smaller countries such as Sweden and Finland, two cases had been reported for each of them. Due to the unlikely probability of familial colloid cyst occurring at random, a genetic component is likely to be involved. The occurrence of several reports from patients from Australia, Finland, Sweden, and Puerto Rico where the population is smaller or more segregated may also suggest a genetic inheritance. Screening of first-degree-related subjects is recommended for families in which two or more members are affected. The presence of a colloid cyst in a twin mandates neuroimaging in the other twin, as there are five familial cases in twins reported in the literature.

Keywords: *Colloid cyst, familial, genetic, third ventricle*

Introduction

Colloid cysts are benign intracranial lesions located anterosuperior to the third ventricular roof, with only a small part protruding into the foramen of Monro.^[1] These lesions comprise about 0.5%–2% of all intracranial tumors and 15%–20% of all intraventricular tumors.^[1–3] The incidence of these lesions is at least 3.2/1 million/year.^[2] The first case was reported by Wallmann in 1858.^[4] Dandy successfully removed the first colloid cyst in 1921.^[5] They can be an incidental finding on imaging or present with headaches or with symptomatic hydrocephalus due to obstruction of cerebrospinal fluid flow. Although this type of lesion is rare, familial cases have been reported.^[6–28] They have been found in twins (monozygotic and dizygotic), brothers and/or sisters, and on a parent and siblings. This report represents, to the best of our knowledge, the 23rd case of familial colloid cysts [Table 1].

This is an open access journal, and articles are distributed under the terms of the Creative Commons Attribution-NonCommercial-ShareAlike 4.0 License, which allows others to remix, tweak, and build upon the work non-commercially, as long as appropriate credit is given and the new creations are licensed under the identical terms.

For reprints contact: reprints@medknow.com

Case Report

A 49-year-old female patient from Puerto Rico complained of chronic headache for several months and her primary physician ordered a brain magnetic resonance imaging (MRI) which showed a colloid cyst measuring 13 mm without ventriculomegaly [Figure 1]. She was consulted with a neurosurgeon, and due to the large size, the surgery was recommended. The cyst was removed through a right transcallosal approach. The patient made an excellent recovery and was discharged 3 days later. Five years prior, her 21-year-old daughter presented to the emergency room with a severe headache over the last week. A brain MRI revealed a colloid cyst measuring 10 mm with obstructive hydrocephalus with an asymmetric large left ventricle [Figure 2]. The cyst was removed successfully through a left transcallosal approach. She was discharged after 3 days and returned to her daily routine the following month. The mother denied that any other family member

**Carlos Calderón,
Ricardo Jose
Fernandez-de
Thomas,
Orlando De Jesus**

Department of Surgery, Section of Neurosurgery, School of Medicine, University of Puerto Rico, San Juan, PR

Address for correspondence:
Dr. Orlando De Jesus,
Section of Neurosurgery, School of Medicine, University of Puerto Rico, Po Box 365067, San Juan, PR.
E-mail: drodejesus@aol.com

Access this article online

Website: www.asianjns.org

DOI: 10.4103/ajns.AJNS_332_19

Quick Response Code:



How to cite this article: Calderón C, Fernandez-de Thomas RJ, De Jesus O. Familial colloid cysts of the third ventricle: Case report and literature review. *Asian J Neurosurg* 2020;15:414-7.

Submitted: 08-Nov-2019 Revised: 21-Dec-2019
Accepted: 18-Feb-2020 Published: 07-Apr-2020

Table 1: Familial colloid cysts reported in the literature

Authors and year	Family members	Sex	Country of origin
Ibrahim <i>et al.</i> , 1986 ^[6]	Monozygotic twin brothers	Male/male	Saudi Arabia
Bengtson <i>et al.</i> , 1990 ^[7]	Nontwin brothers	Male/male	United States
Vandertop <i>et al.</i> , 1995 ^[8]	Three sisters	Female/female/female	Netherlands
Akins <i>et al.</i> , 1996 ^[9]	Father and son	Male/male	United States
Mathiesen <i>et al.</i> , 1997 ^[10]	Mother and son	Female/male	Sweden
van Gelder <i>et al.</i> , 1998 ^[11]	Nontwin opposite sex	Female/male	Australia
Stoodley <i>et al.</i> , 1999 ^[12]	Nontwin opposite sex	Female/male	Australia
Aggarwal <i>et al.</i> , 1999 ^[13]	Mother and son	Female/male	Australia
Nader-Sepahi and Hamlyn 2000 ^[14]	Mother and two daughters	Female/female/female	United Kingdom
Ahmed and Stanworth 2002 ^[15]	Monozygotic twin brothers	Male/male	United Kingdom
Socin <i>et al.</i> 2002 ^[16]	Two half-sisters	Female/female	Belgium
Sadeghi <i>et al.</i> , 2003 ^[17]	Brother and two sisters	Male/female/female	Iran
Partington and Bookalil 2004 ^[18]	Father and daughter	Male/female	Australia
Joshi <i>et al.</i> , 2005 ^[19]	Nontwin sisters	Female/female	South Asian
Bavil and Vahedi 2007 ^[20]	Nontwin sisters	Female/female	Iran
Romani <i>et al.</i> , 2008 ^[21]	Dizygotic twin brothers	Male/male	Finland
Saarinen <i>et al.</i> , 2012 ^[22]	Nontwin brothers	Male/male	Finland
Salaud <i>et al.</i> , 2013 ^[23]	Mother and daughter	Female/female	France
Benoiton <i>et al.</i> , 2014 ^[24]	Mother and daughter	Female/female	New Zealand
Ronne-Engström and Popek 2015 ^[25]	Monozygotic twin sisters	Female/female	Sweden
Niknejad <i>et al.</i> , 2015 ^[26]	Nontwin brothers	Male/male	Saudi Arabia
Yaish <i>et al.</i> , 2017 ^[27]	Monozygotic twin brothers	Male/male	Germany
Weisbrod <i>et al.</i> , 2018 ^[28]	Nontwin brothers	Male/male	United States
Current report	Mother and daughter	Female/female	Puerto Rico

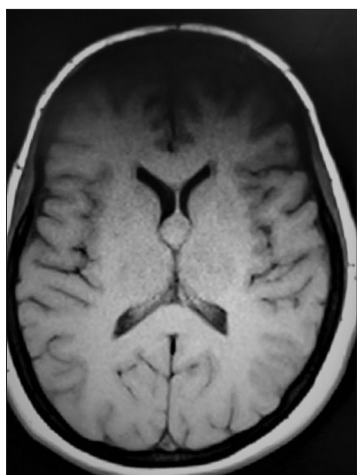


Figure 1: T1-weighted axial magnetic resonance imaging showing a 13 mm anterior third ventricular colloid cyst

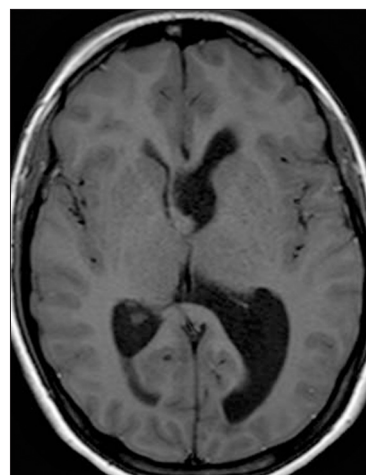


Figure 2: T1-weighted axial magnetic resonance imaging showing a 10 mm anterior third ventricular colloid cyst with asymmetric dilatation of the left lateral ventricle

has had a brain surgery, sudden death, or been diagnosed with a colloid cyst. Congenital defects in the family and consanguinity between father and mother have been denied.

Discussion

Colloid cysts of the third ventricle are a slow-growing intraventricular lesion. They contain colloid material and are located anterosuperior to the third ventricular roof with only a small part protruding into the foramen of Monro.^[1] Although a neuroepithelial origin has become increasingly accepted, other sources have been suggested.^[6,7,26] Recently,

histopathologic and electron microscope studies have suggested an endodermal origin.^[21,26]

Colloid cysts usually occur as sporadic cases. To our knowledge, only 23 familial cases of colloid cysts have been reported.^[6-28] This report presents the 24th case of familial colloid cysts. Table 1 shows all the reported cases, including ours. This is the fourth report of familial colloid cysts that occurred between a mother and daughter, and the first case of familial colloid cyst reported in Puerto Rico. The probability of this lesion occurring at random

within the same family is 1 in 10,000,000,000.^[13,29] The occurrence of colloid cysts in identical twins suggests a possible genetic inheritance in familial cases.^[6] Vandertop *et al.* reported the occurrence of a colloid cyst in three sisters of a family and concluded that a monogeneous Mendelian mode of inheritance may be involved in familial colloid cysts.^[8] Some authors have advocated an autosomal dominant pattern of inheritance.^[13,18,19,22-24,27] Other authors think that an autosomal recessive inheritance is more likely.^[11,15,16] A multifactorial inheritance has also been proposed.^[11,12] The genetic inheritance for familial colloid cysts is far from clear. Further genetic testing needs to be made to elucidate the pattern of inheritance.

Familial colloid cysts reports have a worldwide distribution [Table 1]. Australian patients have been reported four times.^[11-13,18] Three families in the USA had also been reported.^[7,9,28] Saudi Arabia, Sweden, United Kingdom, Iran, and Finland had been reported twice. For the largest countries in the world where the population is over 100 million, only the United States has reported cases. This could be the effect of a better scientific reporting system in the United States compared to other countries. The absence of reports from any other of the largest countries may be due to the diversity of the population but may also be due to a gap in the reporting system. The high incidence of reported cases in Australia and in small populated and segregated countries such as Sweden and Finland also suggests a genetic inheritance. The population in Puerto Rico is smaller than any of the other countries with reported cases. Although in our case and in the majority of the cases, no consanguinity was noted, the occurrence of these familial cases may be due to inbreeding in these small countries.

Chang *et al.* reported on a young patient with a nasal dermoid sinus cyst and a colloid cyst and proposed that a colloid cyst is a congenital midline defect associated with the anterior neuropore closure.^[30] Saarinen *et al.* identify a family with familial nasal dermoid sinus cysts in which two out of the six affected members had a colloid cyst and suggested an autosomal dominant inheritance with complete penetrance in familial cases.^[22] Kurwale *et al.* reported a patient with a suprasellar dermoid cyst who also had a colloid cyst and proposed that both cysts occur as a congenital midline defect associated with the anterior neuropore closure.^[31] Akins *et al.* recognized that colloid cysts may be associated to several midline developmental malformations which represent a spectrum of neural tube closure defects.^[9] Whether these cases may help to elucidate the inheritance for familial colloid cyst remains unclear.

Conclusion and Recommendations

Screening by MRI of first-degree-related subjects is recommended for families in which two or more members are affected. The presence of a colloid cyst in a twin mandates an MRI in the other twins as there are five

familial cases in twins reported in the literature. A thorough family history is of great value to understand the type of inheritance by which familial colloid cysts are transmitted. Colloid cysts can be associated with other midline developmental malformations or lesions.

Declaration of patient consent

The authors certify that they have obtained all appropriate patient consent forms. In the form the patient(s) has/have given his/her/their consent for his/her/their images and other clinical information to be reported in the journal. The patients understand that their names and initials will not be published and due efforts will be made to conceal their identity, but anonymity cannot be guaranteed.

Financial support and sponsorship

Nil.

Conflicts of interest

There are no conflicts of interest.

References

- Hernesniemi J, Romani R, Dashti R, Albayrak BS, Savolainen S, Ramsey C 3rd, *et al.* Microsurgical treatment of third ventricular colloid cysts by interhemispheric far lateral transcallosal approach—experience of 134 patients. *Surg Neurol* 2008;69:447-53.
- Hernesniemi J, Leivo S. Management outcome in third ventricular colloid cysts in a defined population: A series of 40 patients treated mainly by transcallosal microsurgery. *Surg Neurol* 1996;45:2-14.
- Little JR, MacCarty CS. Colloid cysts of the third ventricle. *J Neurosurg* 1974;40:230-5.
- Wallmann H. Eine Colloideyste im dritten Hirnventrikel und ein Lipom im Plexus choroideus. *Virchows Arch Pathol Anat* 1858;11:385-8.
- Dandy WE. Diagnosis localization and removal of tumors of the third ventricle. *Bull Johns Hopkins Hosp* 1922;33:188-9.
- Ibrahim AW, Farag H, Naguib M, Ibrahim E. Neuro-epithelial (colloid) cyst of the third ventricle in identical twins. *J Neurosurg* 1986;65:401-3.
- Bengtson BP, Hedeman LS, Bauserman SC. Symptomatic neuroepithelial (colloid) cysts of the third ventricle. A unique case report in nontwin brothers. *Cancer* 1990;66:779-85.
- Vandertop WP, Gosselaar PH, Nesselrooij B. Three sisters with colloid cyst of third ventricle. *Lancet* 1995;346:643-4.
- Akins PT, Roberts R, Coxe WS, Kaufman BA. Familial colloid cyst of the third ventricle: Case report and review of associated conditions. *Neurosurgery* 1996;38:392-5.
- Mathiesen T, Grane P, Lindgren L, Lindquist C. Third ventricle colloid cysts: A consecutive 12-year series. *J Neurosurg* 1997;86:5-12.
- van Gelder JM, Dahlstrom JE, Newcombe RL. Colloid cyst of the third ventricle in opposite sex, non-twin siblings. *J Clin Neurosci* 1998;5:207-9.
- Stoodley MA, Nguyen TP, Robbins P. Familial fatal and near-fatal third ventricle colloid cysts. *Aust N Z J Surg* 1999;69:733-6.
- Aggarwal A, Corbett A, Graham J. Familial colloid cyst of the third ventricle. *J Clin Neurosci* 1999;6:520-2.

14. Nader-Sepahi A, Hamlyn PJ. Familial colloid cysts of the third ventricle: Case report. *Neurosurgery* 2000;46:751-3.
15. Ahmed SK, Stanworth PA. Colloid cysts of the third ventricle in identical twins. *Br J Neurosurg* 2002;16:303-7.
16. Socin HV, Born J, Wallemacq C, Betea D, Legros JJ, Beckers A. Familial colloid cyst of the third ventricle: Neuroendocrinological follow-up and review of the literature. *Clin Neurol Neurosurg* 2002;104:367-70.
17. Sadeghi S, Sharifi G, Aliasgari A. Familial colloid cyst of the third ventricle: A case report and review of the literature. *Med J Islam Repub Iran* 2003;17:267-9.
18. Partington MW, Bookalil AJ. Familial colloid cysts of the third ventricle. *Clin Genet* 2004;66:473-5.
19. Joshi SM, Gnanalingham KK, Mohaghegh P, Wilson A, Elsmore A. A case of familial third ventricular colloid cyst. *Emerg Med J* 2005;22:909-10.
20. Bavit MS, Vahedi P. Familial colloid cyst of the third ventricle in non-twin sisters: Case report, review of the literature, controversies, and screening strategies. *Clin Neurol Neurosurg* 2007;109:597-601.
21. Romani R, Niemelä M, Korja M, Hernesniemi JA. Dizygotic twins with a colloid cyst of the third ventricle: Case report. *Neurosurgery* 2008;63:E1003.
22. Saarinen I, Karppinen A, Saarinen P, Hytönen M, Klockars T. Inheritance of nasal dermoid sinus cyst and evidence for association with third ventricle colloid cyst. *Childs Nerv Syst* 2012;28:117-20.
23. Salaud C, Hamel O, Buffenoir-Billet K, Nguyen JP. [Familial colloid cyst of the third ventricle: Case report and review of the literature]. *Neurochirurgie* 2013;59:81-4.
24. Benoiton LA, Correia J, Kamat AS, Wickremesekera A. Familial colloid cyst. *J Clin Neurosci* 2014;21:533-5.
25. Ronne-Engström E, Popek E. Symptomatic colloid cysts in the third ventricle of monozygotic twins. *Ups J Med Sci* 2015;120:59-62.
26. Niknejad HR, Samii A, Shen SH, Samii M. Huge familial colloid cyst of the third ventricle: An extraordinary presentation. *Surg Neurol Int* 2015;6:S349-53.
27. Yaish M, Török L, Zanotti B, Alfieri A. Familial colloid cyst of the third ventricle in monozygotic twins. *J Neurol Stroke* 2017;6:219.
28. Weisbrod LJ, Smith KA, Chamoun RB. Familial colloid of the third ventricle. *Interdiscip Neurosurg* 2018;14:186-7.
29. Vandertop WP. Familial colloid cyst of the third ventricle: Case report and review of associated conditions. *Neurosurgery* 1996;39:421.
30. Cheng ML, Chang SD, Pang D, Adler JR. Intracranial nasal dermoid sinus cyst associated with colloid cyst of the third ventricle. Case report and new concepts. *Pediatr Neurosurg* 1999;31:201-6.
31. Kurwale N, Kumar R, Sharma MC, Sharma BS. Suprasellar dermoid cyst associated with colloid cyst of the third ventricle: Disordered embryogenesis or a mere coincidence? *J Neurosci Rural Pract* 2013;4:345-7.