

Purely Suprasellar (Hypothalamic) Atypical Teratoid Rhabdoid Tumor Presenting with Diabetes Insipidus and Panhypopituitarism in an Adult Male: A Case Report and Review of Literature

Abstract

Atypical teratoid rhabdoid tumor (ATRT) is a rare primary malignant tumor of the central nervous system. Little knowledge is available about natural history, behavior, prognosis, and best management guidelines of such tumor. Its occurrence in adults is very rare and more predominant in females. Locations in adults are mainly cerebral hemispheres, but recently, more cases are reported in sellar/suprasellar cisterns. We are reporting a case of purely suprasellar ATRT of a middle aged male who presented initially with diabetes insipidus (DI).

Keywords: *Atypical teratoid rhabdoid tumor, diabetes insipidus, suprasellar*

Introduction

Atypical teratoid rhabdoid tumor (ATRT) is a rare primary malignant tumor of the central nervous system. It occurs mainly in children below 3 years old in posterior fossa.^[1] To our knowledge, about fifty cases are reported in adult population, mainly in females. The cases reported in sellar/suprasellar region have a sellar component with suprasellar extension.^[2] According to the World Health Organization classification of central nervous system tumors 2016, ATRT is Grade 4. Diagnosis is mainly pathological through immunohistochemistry either by alterations or loss of integrase interactor 1 (INI1) protein or BRG1 protein.^[3] Due to limited number of reported cases, little knowledge is available about natural history, behavior, prognosis, and best management guidelines of such tumor. Hence, we present a unique case of purely suprasellar ATRT without sellar component. We are reporting a case of purely suprasellar ATRT of a middle aged male who presented initially with diabetes insipidus (DI).

Case Report

A 46-year-old male presented with sudden-onset anorexia, nausea, fatigue,

dry mouth, thirst, polyuria, polydipsia, and dizziness on standing for 10 days. There was no other complaint. On examination, the patient was confused Glasgow Coma Scale 14, dry mouth, dry tongue, bitemporal hemianopia, moving all limbs. Workup found increased urine output (more than 3 L/day), high serum sodium (159 mmol/L), high serum osmolarity (356 mosm/kg) with relatively low urine osmolarity (125 mosm/kg), and high creatinine (160 μ mol/L) (acute kidney injury due to dehydration) which improved after few days of proper hydration. Hormonal profile revealed panhypopituitarism. Radiological images revealed [Figure 2a and b] suprasellar mass lesion. The patient was diagnosed as a case of central diabetes insipidus with panhypopituitarism. He was started on desmopressin, hydrocortisone, and thyroxine which resulted in improvement of his symptoms, signs, and sodium levels.

Ophthalmology examination preoperative revealed visual acuity 6/9 aided (glasses) in both eyes [Figure 1a and b].

After stabilization of patient medical conditions, he underwent right supraorbital craniotomy and resection of suprasellar

**Ahmed Shaaban¹,
Amro Al Hajali¹,
Orwa Elaiwy²,
Ahmed El
Sotouhy^{3,4},
Issam Al-Bozom^{2,4},
Ali Ayyad^{1,4,5}**

Departments of ¹Neurosurgery, ³Radiology and ²Pathology, Hamad Medical Corporation, ⁴Departments of Neurosurgery, Radiology and Pathology, Weill Cornell Medical College, Doha, Qatar; ⁵Department of Neurosurgery, Saarland University Hospital, Homburg, Germany

Address for correspondence:

Dr. Ahmed Shaaban,
Department of Neurosurgery,
Hamad Medical
Corporation, Doha, Qatar.
E-mail: aashaaban4@hamad.qa

Access this article online

Website: www.asianjns.org

DOI: 10.4103/ajns.AJNS_328_20

Quick Response Code:



How to cite this article: Shaaban A, Al Hajali A, Elaiwy O, El Sotouhy A, Al-Bozom I, Ayyad A. Purely suprasellar (Hypothalamic) atypical teratoid rhabdoid tumor presenting with diabetes insipidus and panhypopituitarism in an adult male: A case report and review of literature. *Asian J Neurosurg* 2021;16:846-9.

Submitted: 04-Jul-2020

Revised: 02-Oct-2020

Accepted: 26-Apr-2021

Published: 18-Dec-2021

This is an open access journal, and articles are distributed under the terms of the Creative Commons Attribution-NonCommercial-ShareAlike 4.0 License, which allows others to remix, tweak, and build upon the work non-commercially, as long as appropriate credit is given and the new creations are licensed under the identical terms.

For reprints contact: WKHLRPMedknow_reprints@wolterskluwer.com

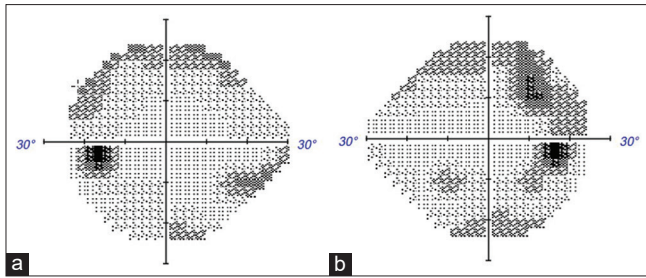


Figure 1:(a,b) visual field examination of left eye on the left side and right eye on the right side

lesion [Figure 5a and b]. Frozen section intraoperative was suggestive of high-grade malignant lesion. Final pathology revealed ATRT [Figures 3 and 4a-d]. Postoperative day 1, magnetic resonance imaging showed almost total resection of the tumor [Figure 2c].

The case was discussed in a multidisciplinary meeting and planned for adjuvant chemoradiotherapy.

Pathological description of atypical teratoid/rhabdoid tumor

Sections show highly cellular tumor consisting of sheets, nests, and papillary structures. The tumor cells have heterogeneous morphology, in some areas they appear small primitive, while in others, they appear large polygonal with abundant dense eosinophilic cytoplasm, and in most of the areas, they have rhabdoid appearance with eccentrically placed vesicular nuclei, prominent nucleoli, and abundant eosinophilic inclusion-like cytoplasm [Figure 3]. By immunohistochemistry, tumor cells show immunophenotypic heterogeneity characterized by positivity with epithelial membrane antigen [Figure 4a], cytokeratin AE1/AE3 [Figures 4b], glial fibrillary acidic protein [Figure 4c], S100, smooth muscle actin, Olig2, synaptophysin, and vimentin, but most importantly, they show loss of nuclear staining by INI1 [Figure 4d].

Discussion

ATRT is embryonal tumors containing rhabdoid component (eccentric round nuclei, large cell body, small-to-medium size nucleoli, and open chromatin) in addition to primitive neuroectodermal, mesenchymal, epithelial features. It was first described 1978 in the kidneys. Brain tumors similar to primitive neuroectodermal tumor with rhabdoid component were first described 1987 and named “atypical teratoid tumors of infancy.”^[1] Diagnosis is mainly pathological through immunohistochemistry either by alterations or loss of INI1 protein or BRG1 protein in addition to rhabdoid components.^[1,3]

Based on our literature review, only fifty cases are reported in adults, with more than two-third of cases in females.^[3] The average age of diagnosis is 36.7.^[3] The most common locations include cerebral hemispheres and sellar/suprasellar regions. To our knowledge, all reported cases

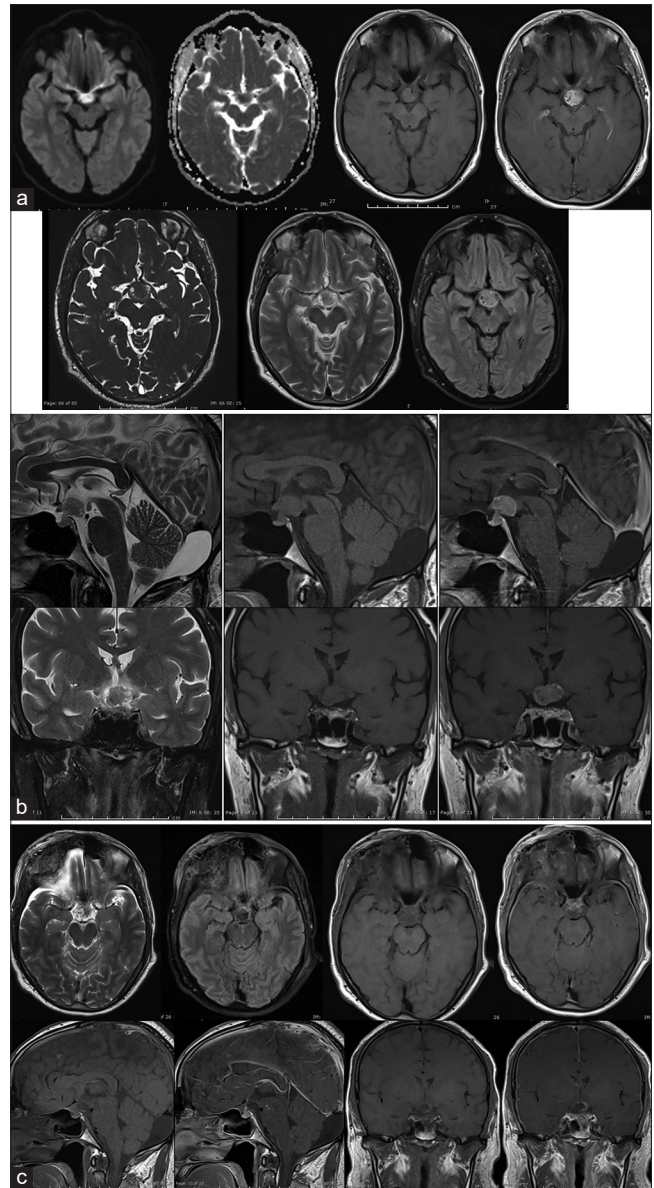


Figure 2: (a) Axial DWI, T1 pre and post IV contrast, CISS, T2 and FLAIR MR images of the brain showing midline intracranial extra-axial mass lesion centered on the supra-sellar cistern of intermediate signal intensity in T1 and T2 WI and relatively high signal intensity in FLAIR WI that shows intense non-homogenous post contrast enhancement pattern as well as evidence of restricted diffusion pattern that indicates high cellularity of the lesion. The differential diagnosis includes germ cell tumor, hypothalamic glioma, meningioma and atypical teratoma. (b) Sagittal and Coronal thin sellar section T2 and T1 WI before and after IV contrast administration clearly showing the lesion in the supra-sellar region indenting the floor of the third ventricle and being separable from the pituitary gland and optic chiasm. (c) 1st day Post-operative MR imaging in Axial T2, FLAIR and T1 pre and post IV contrast, Sagittal and Coronal Thin sellar sections in T1 WI pre and post IV contrast showing almost total resection of the mass lesion with expected post-operative changes; histopathological diagnosis of Atypical Teratoid Rhabdoid tumor (ATRT) was given and the patient was referred to medical oncology care.

in sellar/suprasellar regions occurred in females and all of them have sellar component with suprasellar extension.^[2,4-16] Our case is the first reported case to occur in middle-aged males with purely suprasellar location without any sellar components. Intraoperative lesion appeared to be arising

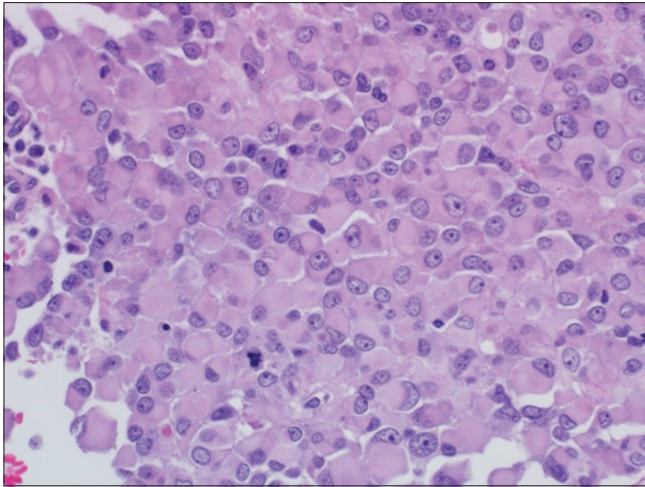


Figure 3: Microscopic view showing sheets of rhabdoid cells with dense eosinophilic inclusion-like cytoplasm (H&E x400)

from hypothalamus. Hence, it can direct research toward pathogenesis and origins of such tumors.

Clinical presentation varies based on patient age, location, and tumor size. All cases reported in sellar/suprasellar region presented mainly with headache and diplopia.^[2,4-16] Two of the reported cases presented with subarachnoid hemorrhage associated with intraventricular extension.^[2,11] As our case is purely suprasellar (hypothalamic) with compression of pituitary stalk, so presentation was a little bit different as diabetes insipidus and panhypopituitarism.

We preferred right supraorbital craniotomy approach based on many reasons. First, it is a minimally invasive approach. Second, exposure is almost similar to other approaches (pterional and interhemispheric). Third, you can work in different windows including interoptic window, carotico-optic window, translamina terminalis, and lateral to carotid window. In addition, our surgery included both microscopic and endoscopic techniques. Putting in mind, you do not have to manipulate the optic nerve in supraorbital approach. Right supraorbital approach is preferred as it is nondominant hemisphere, and we can decompress optic nerve as there is more deficit on right side. On the other hand, interhemispheric approach not superior to supraorbital approaches, it gives you access only to midline windows including interoptic window and translamina terminalis but not lateral to carotid window.^[17,18]

Based on genetic studies, ATRT arises as a result of chromosome 22 deletion including area INI1/hSNF5 tumor suppressor gene required to suppress rhabdoid tumor.^[1,19] There is still no agreement about the best management guidelines. However, like our case, treatment started with surgical resection followed by chemoradiotherapy.^[2]

Prognosis is poor, and majority of sellar/suprasellar cases die within 2 years of diagnosis.^[2] There is no previous case as purely suprasellar (hypothalamic). Thus, we have no data about the prognosis of purely suprasellar lesions.

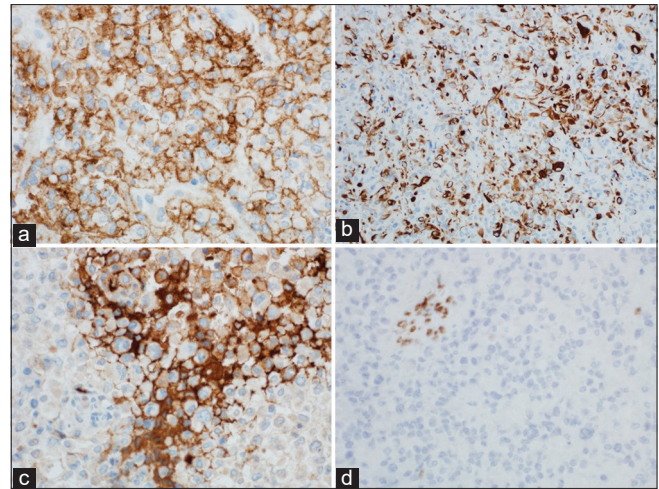


Figure 4: (a) Tumor cells are diffusely positive with epithelial membrane antigen (EMA), (immunohistochemistry x200) (b) Tumor cells are significantly positive with cytokeratin AE1/AE3 (immunohistochemistry x200) (c) Tumor cells are focally expressing glial fibrillary acidic protein (GFAP) (immunohistochemistry x400) (d) Loss of nuclear staining by INI-1 while blood vessels show retained nuclear staining (immunohistochemistry x400)

ATRT is rarely considered in the differential diagnosis either radiologically, intraoperative. Preoperative radiological differential diagnoses were germ cell tumor, hypothalamic glioma, meningioma, and atypical teratoma. Our impression intraoperative was high-grade glioma arising either from optic chiasm or hypothalamus. Fresh frozen sample sent for pathology intraoperative and impression was highly malignant lesion either glioma or metastasis. On the contrast, final pathology report was ATRT.

Therefore, we should to start consider ATRT in our differential diagnosis for suprasellar lesions as it will affect our management either early surgical intervention for resection and pathological diagnosis or follow-up with serial imaging. More basic and clinical research is needed on multicenter level as a number of cases are limited to address issues of natural history, behavior, radiological distinguishing specific features, prognosis, and management strategy.

Conclusion

Our case is the first reported purely suprasellar (hypothalamic) ATRT without sellar component in an adult male. We should consider ATRT in our differential diagnosis of suprasellar lesions. We recommend gross total resection of such malignant lesion followed by chemoradiotherapy. Reevaluation of our understanding of pathogenesis and molecular genetics should be done to broaden our knowledge about actual origin of these tumors. More research is needed to address natural history, behavior, radiological distinguishing specific features, prognosis, and management strategy.

Financial support and sponsorship

Nil.

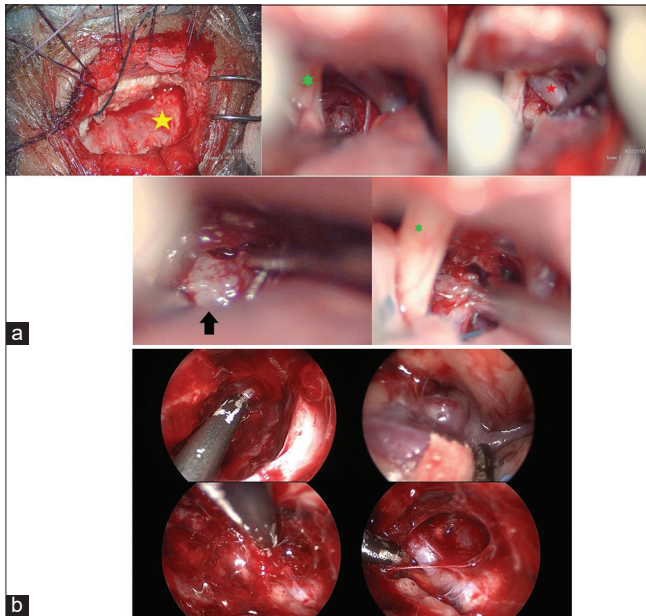


Figure 5: (a) Microscopic images showing right supraorbital craniotomy approach and resection of suprasellar lesion (atypical teratoid/rhabdoid tumor) yellow star: Dura, green star: Right optic nerve, red star: Internal carotid artery black arrow atypical teratoid rhabdoid tumor. (b) Endoscopic images showing right supraorbital craniotomy approach and resection of suprasellar lesion (atypical teratoid/ rhabdoid tumor)

Conflicts of interest

There are no conflicts of interest.

References

- Nesvick CL, Nageswara Rao AA, Raghunathan A, Biegel JA, Daniels DJ. Case-based review: Atypical teratoid/rhabdoid tumor. *Neurooncol Pract* 2019;6:163-78.
- Siddiqui M, Thoms D, Samples D, Caron J. Atypical teratoid/rhabdoid tumor presenting with subarachnoid and intraventricular hemorrhage. *Surg Neurol Int* 2019;10:139.
- Chan V, Marro A, Findlay JM, Schmitt LM, Das S. A systematic review of atypical teratoid rhabdoid tumor in adults. *Front Oncol* 2018;8:567.
- Arita K, Sugiyama K, Sano T, Oka H. Atypical teratoid/rhabdoid tumour in sella turcica in an adult. *Acta Neurochir (Wien)* 2008;150:491-5.
- Kuge A, Kayama T, Tsuchiya D, Kawakami K, Saito S, Nakazato Y, *et al.* Suprasellar primary malignant rhabdoid tumor in an adult: A case report. *No Shinkei Geka* 2000;28:351-8.
- Las Heras F, Pritzker KP. Adult variant of atypical teratoid/rhabdoid tumor: Immunohistochemical and ultrastructural confirmation of a rare tumor in the sella tursica. *Pathol Res Pract* 2010;206:788-91.
- Park HG, Yoon JH, Kim SH, Cho KH, Park HJ, Kim SH, *et al.* Adult-onset sellar and suprasellar atypical teratoid rhabdoid tumor treated with a multimodal approach: A case report. *Brain Tumor Res Treat* 2014;2:108-13.
- Raisanen J, Biegel JA, Hatanpaa KJ, Judkins A, White CL, Perry A. Chromosome 22q deletions in atypical teratoid/rhabdoid tumors in adults. *Brain Pathol* 2005;15:23-8.
- Shitara S, Akiyama Y. Atypical teratoid/rhabdoid tumor in sellar turcica in an adult: A case report and review of the literature. *Surg Neurol Int* 2014;5:75.
- Almalki MH, Alrogi A, Al-Rabie A, Al-Dandan S, Altwairgi A, Orz Y. Atypical teratoid/rhabdoid tumor of the sellar region in an adult with long survival: Case report and review of the literature. *J Clin Med Res* 2017;9:216-20.
- Asmaro K, Arshad M, Massie L, Griffith B, Lee I. Sellar atypical teratoid/rhabdoid tumor presenting with subarachnoid and intraventricular hemorrhage. *World Neurosurg* 2019;123:e31-8.
- Barresi V, Lioni S, Raso A, Esposito F, Cannavò S, Angileri FF. Pituitary atypical teratoid rhabdoid tumor in a patient with prolactinoma: A unique description. *Neuropathology* 2018;38:260-7.
- Moretti C, Lupoi D, Spasaro F, Chioma L, Di Giacinto P, Colicchia M, *et al.* Sella turcica atypical teratoid/rhabdoid tumor complicated with lung metastasis in an adult female. *Clin Med Insights Case Rep* 2013;6:177-82.
- Nakata S, Nobusawa S, Hirose T, Ito S, Inoshita N, Ichi S, *et al.* Sellar atypical teratoid/rhabdoid tumor (AT/RT): A clinicopathologically and genetically distinct variant of AT/RT. *Am J Surg Pathol* 2017;41:932-40.
- Nishikawa A, Ogiwara T, Nagm A, Sano K, Okada M, Chiba A, *et al.* Atypical teratoid/rhabdoid tumor of the sellar region in adult women: Is it a sex-related disease? *J Clin Neurosci* 2018;49:16-21.
- Schneiderhan TM, Beseoglu K, Bergmann M, Neubauer U, Macht S, Hänggi D, *et al.* Sellar atypical teratoid/rhabdoid tumours in adults. *Neuropathol Appl Neurobiol* 2011;37:326-9.
- Reisch R, Perneczky A, Filippi R. Surgical technique of the supraorbital key-hole craniotomy. *Surg Neurol* 2003;59:223-7.
- Rychen J, Croci D, Roethlisberger M, Nossek E, Potts M, Radovanovic I, *et al.* Minimally invasive alternative approaches to pterional craniotomy: A systematic review of the literature. *World Neurosurg* 2018;113:163-79.
- Lev I, Fan X, Yu R. Sellar atypical teratoid/rhabdoid tumor: Any preoperative diagnostic clues? *AACE Clin Case Rep* 2015;1:e2-7.