

## Morphometric Analysis of the Corpus Callosum Using Cadaveric Brain: An Anatomical Study

### Abstract

**Purpose:** The present study was conducted to measure the longitudinal and vertical lengths of the brain hemisphere, longitudinal length of the corpus callosum (CC), and distances of CC from the frontal and occipital poles, in order to define its topographic location within the brain hemispheres. **Materials and Methods:** Fifty formalin-fixed human brains were dissected in the midsagittal plane. The parameters measured were as follows: (i) straight distance between frontal and occipital pole (AB); (ii) vertical distance (height) between the upper and lower surface of the brain hemisphere (CD); (iii) frontal pole to anterior-most point of CC (EG); (iv) occipital pole to posterior-most point of CC (ZO); (v) anterior-most point to posterior-most point of CC (EZ); and (v) anterior edge of genu to the upper end of lamina terminalis (EF). **Results:** The mean value of AB, CD, EG, ZO, EZ, and EF was  $15.47 \pm 0.94$  cm,  $9.48 \pm 0.83$  cm,  $3.31 \pm 0.29$  cm,  $5.65 \pm 0.54$  cm,  $6.96 \pm 0.55$  cm, and  $2.1 \pm 0.39$  cm, respectively. AB had the strongest positive correlation with ZO (0.79), whereas CD (height) had it with EZ (0.59). Both AB and CD had a strong positive correlation with EZ. The ratios  $EZ/AB = 0.45$  ( $P = 0.001$ ) and  $EZ/CD = 0.73$  ( $P = 0.003$ ) illustrated a steady and significant proportions, present in all the brains studied. Although the mean values of all the parameters were greater in males than in females, only two parameters (ZO and EZ) showed statistically significant ( $P < 0.05$ ) gender differences. **Conclusion:** The precise anatomical knowledge regarding the morphometry of CC will provide baseline data for the diagnosis and progression of disease affecting it.

**Keywords:** Callosotomy, corpus callosum, intractable epilepsy, length, morphometry

### Introduction

The corpus callosum (CC) is a thick bundle of white matter fiber tract connecting the two cerebral hemispheres.<sup>[1]</sup> Each hemisphere is functionally different from the other, and they perceive the world differently. It is the CC, which helps our brain to amalgamate these two thoughts into a single world view. CC consists of four parts. Its anterior end is called the genu or “knee,” central part is the trunk, posterior bulbous part forms the splenium, and rostrum is a prolongation from the genu to the upper end of the lamina terminalis. The nerve fibers of the CC, interconnecting the corresponding parts of two hemispheres, are organized topographically and represent the cortical regions to be connected. Topographically, the fibers passing through the rostrum interconnect the orbital surfaces of the frontal lobes. A fork-like bundle of fibers known as forceps minor

passes through the genu, interconnect the frontal lobes. The fibers passing through the splenium interconnect the occipital lobes using another fork-like bundle called forceps major. A large number of fibers interconnect the parietal lobes passes transversely through the trunk and also intersect the fibers of corona radiata. The contribution of CC in brain function remains a matter of conflict. In general, CC mediates the communication between the two hemispheres of the brain, and hence, seizures may spread rapidly from one hemisphere to the other by the way of the CC. Removing a part or whole of the CC greatly reduces this spread and also stops or decreases the frequency of “drop attacks” from certain types of generalized seizures (atonic seizures). Corpus callosotomy (callosal sectioning) is quite effective in reducing the seizure frequency in patients who have generalized epilepsy with drop attacks.<sup>[2]</sup> The procedure is

This is an open access journal, and articles are distributed under the terms of the Creative Commons Attribution-NonCommercial-ShareAlike 4.0 License, which allows others to remix, tweak, and build upon the work non-commercially, as long as appropriate credit is given and the new creations are licensed under the identical terms.

For reprints contact: reprints@medknow.com

Apurba Patra,  
Rajan Kumar  
Singla<sup>1</sup>,  
Priti Chaudhary,  
Vishal Malhotra<sup>1,2</sup>

Department of Anatomy, AIIMS,  
Bathinda, Departments of  
<sup>1</sup>Anatomy and <sup>2</sup>Department  
of SPM and Biostatistics,  
Government Medical College,  
Patiala, Punjab, India

Address for correspondence:  
Dr. Priti Chaudhary,  
Department of Anatomy, AIIMS,  
Bathinda, Punjab, India.  
E-mail: drpritiarora@gmail.com

#### Access this article online

Website: www.asianjns.org

DOI: 10.4103/ajns.AJNS\_328\_19

#### Quick Response Code:



**How to cite this article:** Patra A, Singla RK, Chaudhary P, Malhotra V. Morphometric analysis of the corpus callosum using cadaveric brain: An anatomical study. Asian J Neurosurg 2020;15:322-7.

Submitted: 06-Nov-2019 Revised: 08-Feb-2020

Accepted: 11-Mar-2020 Published: 29-May-2020

thought to disrupt the rapid spread of seizure, responsible for the sudden loss of consciousness or loss of posture, without warning.<sup>[3]</sup> Even though corpus callosotomy has been known and in practice since 1940, the optimal extent of the callosal section is an unresolved issue in clinical practice.

This morphometric study of CC was undertaken to delineate the topographic location or geomorphology of CC within cerebral hemispheres and the way these anatomical structures interact to each other.

## Materials and Methods

Fifty midsagittal sections (38 males and 12 females) of cadaveric brain, fixed in formalin were used in this study. Participants were aged between 45 and 65 years, with a mean value of age was  $55.84 \pm 7.74$  years. Cadavers with any history of intracranial lesions, head injury, recorded brain pathology, and visible brain abnormalities were excluded from the study. The method used as follows: in removing the brain, the calvarium was exposed, and the skull cap was cut away with a circumferential incision. As the thickness of the skull varies from one area to another, caution must be taken. The depth of the cut must be regulated by the hand to prevent damage to the brain. After the removal of the skull cap, the dura mater was carefully lifted from the cerebral hemispheres, and using a pointed scissors, it was cut along the line of incision. Finally, the whole brain and remaining spinal cord were gently lifted out of the cranium and placed in the brain box.

Immediately, after removal from the cranial vault, they were fixed with basilar suspension in 10% formalin solution for 4 weeks.<sup>[4]</sup> To carry out morphometric study, the brain should be fixed in a satisfactory manner, so that the specimen exhibits a natural form after fixation and all the anatomic components be completely and uniformly fixed. There should be no distortion of the natural shape and border of fixed section. In a dissection study, formalin is universally used for fixing tissues. However, the formalin embalming process is regarded to cause brain volume shrinkage.<sup>[5]</sup> Hence, cautions are required for the clinical application of quantitatively measured data in the embalmed brain. To compensate the defect of this study, we have used 10% formol solution (the actual amount of dissolved formaldehyde in the 10% formalin is 3.7%–4%) for 4 weeks as it is considered as a standardized method of fixation. Thereafter, brains were dissected by using the midsagittal line as an anatomical landmark. The brains were carefully sectioned with brain knife in the midsagittal plane passing through the body of CC, the interhemispheric fissure, septum pellucidum, cavity of the third ventricle, and cerebral aqueduct [Figure 1]. The various morphometric features of CC, longitudinal, and vertical length of brain hemispheres were measured on these midsagittal sections and recorded.

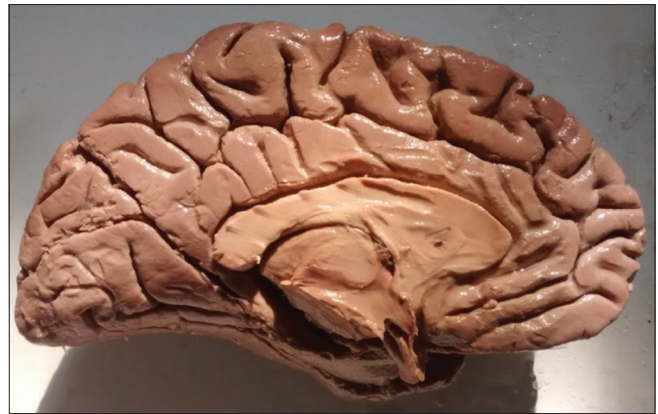


Figure 1: Midsagittal view of the corpus callosum in a cadaveric brain

The parameters measured were as follows: (i) straight distance between the anterior and posterior surface of the brain hemisphere (AB), plane of measurement passing through the lower border of splenium and rostrum of CC; (ii) vertical distance between the upper and lower surface of brain hemisphere (CD), to be specific it was a vertical tangent starting from a point © lying just in front of central sulcus on superomedial border, passing through the midpoint of longitudinal distance of CC (EZ) and reaching up to the inferomedial border (D); (iii) frontal pole of the brain to anterior-most point of CC (EG); (iv) occipital pole of the brain to posterior-most point of CC (ZO); (v) anterior-most point to posterior-most point of CC (EZ); (v) anterior edge of genu to upper end of the lamina terminalis (EF) [Figure 2].

All the measurements were taken using digital Vernier calipers (Mitutoyo, Japan) with least count of 0.01 mm. The measurements were repeated three times, and the mean was taken as final for further analysis. The results were expressed as mean  $\pm$  standard deviation (SD).

CC was divided into seven segments as proposed in Witelson's<sup>[6]</sup> topology. According to this straight-line-based topology, CC consists of seven segments named from the anterior to posterior, as rostrum, genu, rostral body, anterior midbody, posterior midbody, isthmus, and splenium.<sup>[7]</sup> In our study, out of these seven segments, three were taken into account as fibers passing through these segments interconnect important functional cortical areas of two hemispheres: rostrum (EF) contains fibers connecting orbital cortices; genu (the anterior third of EZ) contains fibers connecting prefrontal cortices; and the posterior third is divided into the posterior fifth or splenium (EZ/5) which gives passage to the occipital visual fibers.

## Statistical analysis

Statistical analysis was performed using the Microsoft Office Excel software version 16.0 for Windows 10 to inspect whether any subsequent correlation was present between the longitudinal length of CC with the vertical and longitudinal length of cerebral hemispheres.

We assessed the correlation coefficient of the variable parameters according to Spearman as well as Wilcoxon signed-rank test.  $P < 0.05$  was considered to be statistically significant. The six correlated statistical parameters were as follows: AB, CD, EG, ZO, EZ (EZ/3 or EZ/5), and EF. The correlations between the lengths of different anatomical parts of CC, as well as the correlation between the longitudinal lengths of CC with the vertical and longitudinal lengths of cerebral hemispheres, were examined to detect any stable topographical relationship between these anatomical structures.

## Results

The mean value of the longitudinal diameter of the brain (AB) was  $15.47 \pm 0.94$  cm, whereas the mean value of the longitudinal diameter of the CC (EZ) was  $6.96 \pm 0.55$  cm. The mean value of the vertical diameter (CD) covered a distance of  $9.48 \pm 0.83$  cm. The distance between the frontal pole of the brain to anterior-most point of CC (EG) had a mean value of  $3.31 \pm 0.29$  cm, whereas the distance between occipital pole of the brain to posterior-most point of CC (ZO) was  $5.65 \pm 0.54$  cm. The mean value of the distance between the anterior edge of genu to the upper end of lamina terminalis (EF) was  $2.10 \pm 0.39$  cm [Table 1].

Statistical analysis showed that there was a positive linear correlation between AB and all the other measured

parameters such as CD, EG, ZO, EZ, and EF. Among them, the strongest positive correlation was with ZO (0.79) and weakest with EF (0.42). Similarly, CD had a positive linear correlation with all other measured parameters, but the strongest was with EZ (0.59) followed closely by EF (0.57) and weakest with EG (0.34). EZ had a strong positive linear correlation with AB and CD [Figures 3 and 4], but weakly positive with EG (0.21), EF (0.31), and ZO (0.36). Although all the measured parameters had positive linear correlations with each other, it was the weakest between EF and EG (0.07) [Table 2].

The ratios  $EZ/AB = 0.45$  ( $P = 0.001$ ) and  $EZ/CD = 0.73$  ( $P = 0.003$ ) were present in all the brain specimens studied and represented a fixed, statistically significant proportions [Figure 5a and b].

## Discussion

CC being the major structural connection between the hemispheres is likely to be affected by physiological as well as pathological changes in the cortical and sub-cortical regions of the brain. The fiber system that connects the corresponding cerebral hemispheres travels through the specific regions of the CC. Hence, any morphological changes in CC may give a clue which will help in the diagnosis of specific pathological conditions. When medical treatment is ineffective in severe epileptic patients, surgical intervention in the form of sectioning of the CC can help in reducing the interhemispheric transmission of abnormal electrical discharges.

In the present study, the measurements were within definite limits in all brains. As evident from Table 1, values of SD were found to be very small ( $<1$ ) for each measured parameters, which means that the values in our statistical data set were close to the mean. Hence, the amount of variability or dispersion among the specimens was negligible.

A positive linear association was found between the longitudinal (AB) and vertical lengths (CD) of the brain as well as between the other measured parameters of the brain such as distances of genu of CC from the frontal pole (EG), splenium to occipital pole (ZO), and length of rostrum (EF), which means that increment of one parameter was associated with the increment of the other in a parallel manner, so that the symmetry of the brain was maintained.

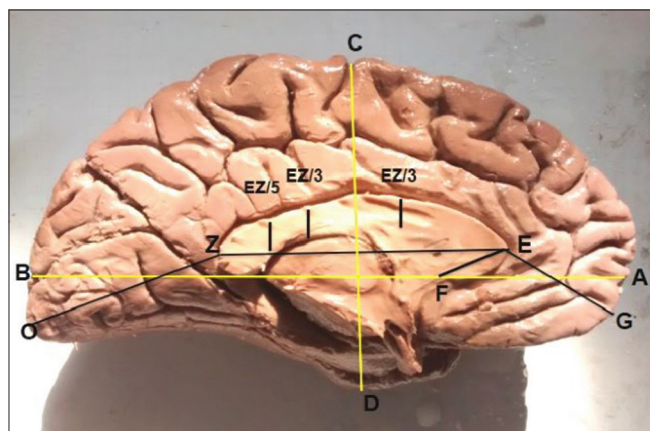


Figure 2: Diagram showing the measurement of longitudinal (AB), vertical length (CD) of cerebral hemisphere, morphometry of the corpus callosum (EZ, EF), and distances of the corpus callosum from the tip of the frontal (EG) and occipital pole (ZO)

Table 1: The mean value, range, and standard deviations of different measured diameters

Diameters	Mean (cm)	Range	SD
AB (straight distance between the anterior and posterior surface of the brain)	15.47	12.80-17.40	0.94
CD (vertical distance between the upper and lower surface of the brain hemisphere)	9.48	7.80-11.00	0.83
EG (frontal pole of the brain to anterior-most point of CC)	3.31	2.70-3.70	0.29
ZO (occipital pole of the brain to posterior-most point of CC)	5.65	4.60-6.80	0.54
EZ (anterior-most point to posterior-most point of CC)	6.96	5.60-8.12	0.55
EF (anterior edge of genu to the upper end of lamina terminalis)	2.10	1.50-3.20	0.39

SD – Standard deviation; CC – Corpus callosum



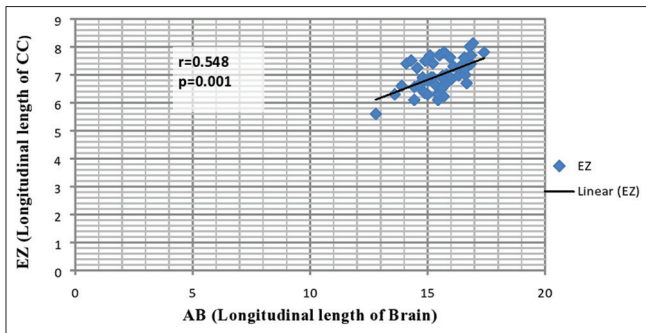


Figure 3: Graph illustrating the correlation between the longitudinal length of the brain (AB) and longitudinal length of the corpus callosum (EZ)

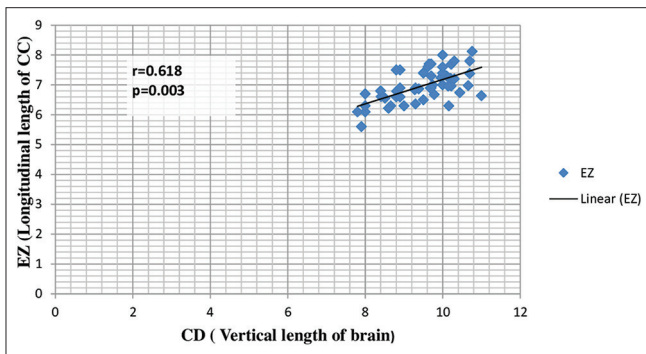


Figure 4: Graph illustrating the correlation between the vertical length of the brain (CD) and the longitudinal length of the corpus callosum (EZ)

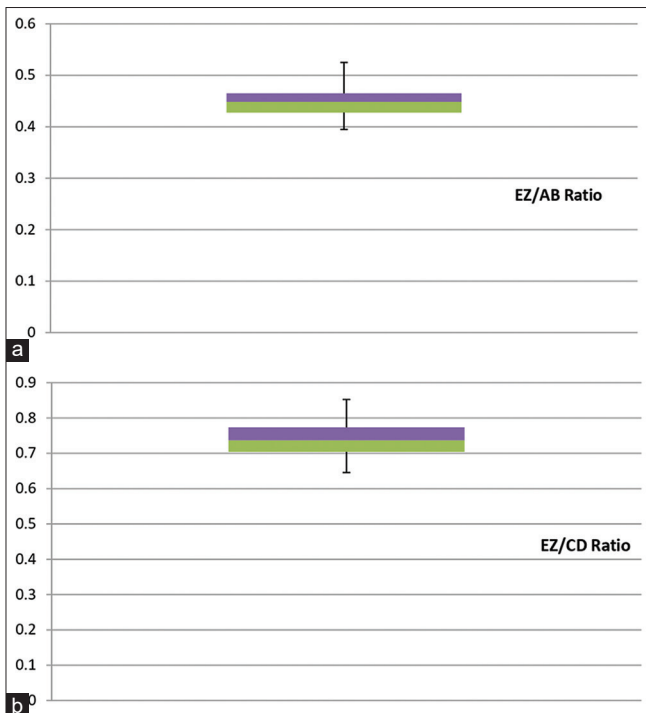


Figure 5: Box whisker plot of: (a) EZ/AB ratio, (b) EZ/CD ratio showing the median is intersecting the rectangle defining the first and third quartile in two halves, indicating that the data are normally distributed in the population and are quite stable

This association was, however, found to be weakest between the length of rostrum (EF) and the distance of CC

Table 2: Correlation-coefficient between the measured diameters, Spearman, rho (n=50)

	CD	EG	ZO	EZ	EF
AB	0.58**	0.60**	0.79**	0.48**	0.42**
CD		0.34*	0.43**	0.59**	0.57**
EG			0.68**	0.21	0.07
ZO				0.36*	0.28
EZ					0.31*

\*\*Correlation is significant at the 0.01 level (two-tailed);

\*Correlation is significant at the 0.05 level (two-tailed)

from the frontal pole (EG), indicating that the symmetry of the brain will be affected the least with any increase in the length of rostrum.

The longitudinal length of the brain (AB) had the strongest correlation with the distance between the splenium to the occipital pole (ZO), which is in agreement with the findings of Anagnostopoulou *et al.*<sup>[4]</sup> According to them, this strong association maybe because of the importance of the visual cortices fiber distribution.

The vertical length of the brain (CD) showed the strongest correlation with the longitudinal length of CC (EZ), which may represent the magnitude of influence of vertical length in maintaining longitudinal length and position of CC within the brain. Contrary to our findings, Anagnostopoulou *et al.*<sup>[4]</sup> found no relation between CD and EZ.

The distance of the genu from the frontal pole (EG) had a positive linear correlation with the distance of splenium from the occipital pole (ZO) and both the lengths had linear relation with the longitudinal length of CC. These findings suggest that these lengths not only play a pivotal role in the maintenance of the symmetrical size of the brain but also influence the position of CC within the brain. Contrary to our findings, Anagnostopoulou *et al.*<sup>[4]</sup> showed that the distance of the genu from the frontal pole and the distance of splenium from the occipital pole had no relation with the longitudinal length of the brain and these lengths can only affect the symmetrical size of the brain but have no influence in the position of CC.

While studying the ratios between the lengths of CC and those of brain hemispheres, we found the ratio between EZ and AB to be 0.43 which was nearly similar to the findings of Anagnostopoulou *et al.* (EZ/AB = 0.47).<sup>[4]</sup> Both the ratios EZ/AB = 0.43 and EZ/CD = 0.73 were found to be stable and statistically significant analogies in every individual brain studied. This indicates that CC had a fixed position in brain hemispheres, which was maintained in every brain studied. These ratios should be considered as stable anatomical data before performing any neurosurgical procedures involving CC,<sup>[8]</sup> and thus, any undesired clinical outcomes could be avoided.<sup>[1]</sup>

While scrutinizing the relationship between the longitudinal length of CC (EZ) and the lengths of brain, we found that

both the longitudinal (AB) and vertical (CD) lengths of the brain had a statistically significant correlation with the longitudinal length of CC (EZ). Although Anagnostopoulou *et al.*<sup>[4]</sup> found a significant linear association between EZ and AB, no such association was found between EZ and CD. Anatomically, this finding of the present study suggests that both the lengths of the brain interact for the horizontal site of CC and are equally important in defining the stable proportion or stable quotation in every brain studied.

In a nutshell, our study suggests a positive correlation between the size of the CC and respective size of the brain, a finding which is consistent with the findings of Anagnostopoulou *et al.*,<sup>[4]</sup> who had done the similar study on formalin-fixed cadaveric brain to determine the position of CC within the brain. Estruch *et al.*<sup>[9]</sup> studied CC atrophy among alcoholic patients with severe cortical damage and imposed that the size of CC depends on the size of the brain. Ankolekar *et al.*<sup>[10]</sup> studied the morphometry of formalin-fixed fetal brains and showed a positive correlation between various brain parameters and CC, indicating the growth of CC proportionate to the size of the brain.

From the clinical perspective, all these explorations advocate that the location of CC is obvious within the cerebral hemisphere, and it can be found in a certain place depending on the size itself and that of the brain. This certainty of the location of CC is very beneficial in callosotomy procedures for intractable epilepsy cases.<sup>[11,12]</sup> The extent of callosal resection remains a matter of controversy for a long time. From this perspective, several authors have probed into the surgical outcomes of their series, but the optimal extent of the callosal section remains unresolved.<sup>[13]</sup> Some prior studies had suggested that complete callosotomy was more likely to abolish severe seizures than partial callosotomy.<sup>[14-16]</sup> However, complete callosotomy may have a higher rate of surgical complications, particularly for disconnection syndromes. Tanriverdi *et al.*<sup>[17]</sup> suggested that since anterior two-thirds callosotomy is of benefit for the majority of patients, it should be performed the first and complete resection should be reserved for patients who fail to benefit from it. Patients with epileptogenic focus located in frontal cortices, benefit from anterior callosotomy.<sup>[18,19]</sup> By comparing patients with a division of the anterior half (46.3%) and those who had two-thirds or greater disconnection, they found a favorable outcome to be more likely, for both drop attacks and generalized tonic-clonic seizures, among those patients who had the larger callosotomies.<sup>[13]</sup> Total or subtotal callosotomy can lead to some neuropsychological sequel, which may be less pronounced if some of the CC, particularly the splenium is preserved.<sup>[18,19]</sup> Recently, researchers are giving more attention to the execution of more targeted callosal interventions such as stereotactic coagulation of genu of the CC, particularly in aggressive patients.<sup>[20]</sup>

These anatomical relationships should be taken into account in every instance of callosotomies, particularly while performing targeted callosal interventions (surgical, stereotactic) as a first-choice therapy, prior to total callosotomy.

## Conclusion

This study demonstrated that each anatomical parts of CC share a stable proportion to each other and the topographic location of CC within the brain is stable, mostly in its horizontal position. The brain not only keeps the possession of its symmetry but can also influence the size and position of CC to some extent. By applying these stable proportions, ratios and resulting analogies to radiological (magnetic resonance imaging) images, the neurosurgeons would be able to plan callosal interventions for intractable epilepsy or other targeted neurosurgical procedures in a better and safe way.

## Acknowledgment

The authors would like to thank and pay respect to all those kind hearts who have donated their body for research and education purposes without whom this work would not have been accomplished.

## Financial support and sponsorship

Nil.

## Conflicts of interest

There are no conflicts of interest.

## References

1. Aboitiz F, Scheibel AB, Fisher RS, Zaidel E. Fiber composition of the human corpus callosum. *Brain Res* 1992;598:143-53.
2. Blume H. The surgical treatment of epilepsy. In: Schachter SC, Schomer DL, editors. *The Comprehensive Evaluation and Treatment of Epilepsy*. San Diego, CA: Academic Press; 1997. p. 197-206.
3. Asadi-Pooya AA, Sharan A, Nei M, Sperling MR. Corpus callosotomy. *Epilepsy Behav* 2008;13:271-8.
4. Anagnostopoulou S, Mourgel S, Katritsis D. Morphometry of corpus callosum: An anatomical study. *Neuroanat* 2006;5:20-3.
5. Schulz G, Crooijmans HJ, Germann M, Scheffler K, Müller-Gerbl M, Müller B. Three-dimensional strain fields in human brain resulting from formalin fixation. *J Neurosci Methods* 2011;202:17-27.
6. Witelson SF. Hand and sex differences in the isthmus and genu of the human corpus callosum. A postmortem morphological study. *Brain* 1989;112(Pt 3):799-835.
7. Machado AM, Simon TJ, Nguyen V, McDonald-McGinn DM, Zackai EH, Gee JC. Corpus callosum morphology and ventricular size in chromosome 22q11.2 deletion syndrome. *Brain Res* 2007;1131:197-210.
8. Gonçalves-Ferreira AJ, Herculano-Carvalho M, Melancia JP, Farias JP, Gomes L. Corpus callosum: Microsurgical anatomy and MRI. *Surg Radiol Anat* 2001;23:409-14.
9. Estruch R, Nicolás JM, Salamero M, Aragón C, Sacanella E, Fernández-Solà J, *et al.* Atrophy of the corpus callosum in

- chronic alcoholism. *J Neurol Sci* 1997;146:145-51.
10. Ankolekar VH, Dsouza A, Hosapatna M, Dsouza AS. Morphometric analysis of corpus callosum in relation to brain size in fetuses of South Indian population. *Int J Res Med Sci* 2014;2:108-11.
  11. Cowell PE, Allen LS, Kertesz A, Zalatimo NS, Denenberg VH. Human corpus callosum: A stable mathematical model of regional neuroanatomy. *Brain Cogn* 1994;25:52-66.
  12. Morino M, Shimizu H, Ohata K, Tanaka K, Hara M. Anatomical analysis of different hemispherotomy procedures based on dissection of cadaveric brains. *J Neurosurg* 2002;97:423-31.
  13. Abou-Khalil BW. When should corpus callosotomy be offered as palliative therapy? *Epilepsy Curr* 2010;10:9-10.
  14. Spencer SS, Spencer DD, Sass K, Westerveld M, Katz A, Mattson R. Anterior, total, and two-stage corpus callosum section: Differential and incremental seizure responses. *Epilepsia* 1993;34:561-7.
  15. Maehara T, Shimizu H. Surgical outcome of corpus callosotomy in patients with drop attacks. *Epilepsia* 2001;42:67-71.
  16. Rahimi SY, Park YD, Witcher MR, Lee KH, Marrufó M, Lee MR. Corpus callosotomy for treatment of pediatric epilepsy in the modern era. *Pediatr Neurosurg* 2007;43:202-8.
  17. Tanriverdi T, Olivier A, Poulin N, Andermann F, Dubeau F. Long-term seizure outcome after corpus callosotomy: A retrospective analysis of 95 patients. *J Neurosurg* 2009;110:332-42.
  18. Kawai K, Shimizu H, Yagishita A, Maehara T, Tamagawa K. Clinical outcomes after corpus callosotomy in patients with bihemispheric malformations of cortical development. *J Neurosurg* 2004;101:7-15.
  19. Kim DS, Yang KH, Kim TG, Chang JH, Chang JW, Choi JU, *et al.* The surgical effect of callosotomy in the treatment of intractable seizure. *Yonsei Med J* 2004;45:233-40.
  20. Nádvořník P, Krupa P, Chrástina J, Smrčka V, Novák Z, Zborilová E. Circular stereotactic callosotomy: A preliminary report. Technical note. *Acta Neurochir (Wien)* 1997;139:359-60.