

The Effectiveness of Dural Venous Sinus Sacrifice as a Treatment of Aggressive Type Cranial Dural Arteriovenous Fistulas

Abstract

Objective: To evaluate the effectiveness of dural venous sinus sacrifice as a treatment of aggressive type cranial dural arteriovenous fistulas (dAVFs) in terms of both clinical outcome and angiographic outcome. **Materials and Methods:** One hundred and twenty-eight patients with 163 aggressive type cranial dAVFs who were treated with dural sinus sacrifice were retrospectively reviewed. Clinical and angiographic outcomes were analyzed. Procedural complications were also recorded. Only 103 patients (80.5%) who had been following up for at least 90 days were analyzed for clinical outcome. **Results:** There were 53 males and 75 females with age ranging from 20 years to 93 years (mean age 55.44 years). The overall angiographic cure rate of dural venous sinus sacrifice as a part of the treatment of aggressive dAVFs was 81.6%. Considering clinical outcome (average duration of follow-up was 2 years and 6 months), 75 patients (72.8%) had clinical improvement and 21 (20.4%) were clinically stable. Worsening of the presenting symptoms was observed in 7 patients (6.8%). Procedural complications were found in 5 patients (3.9%). **Conclusion:** Dural venous sinus sacrifice is a safe and effective treatment strategy with high angiographic cure rate, good clinical outcome, and low incidence of procedural-related complication.

Keywords: Aggressive cranial dural arteriovenous fistula, angiographic outcome, clinical outcome, dural venous sinus sacrifice

Introduction

Cranial dural arteriovenous fistulas (dAVFs) can be classified into benign and aggressive type regarding the characteristic of the venous drainage of the shunts.^[1,2] The risk for hemorrhage or nonhemorrhagic neurological deficit in patients with aggressive shunts is 15% rate per year if left untreated.^[3] These accentuate the need for active and curative treatment of the aggressive dAVFs.

There are attempts to treat only the diseased compartment of the sinus through various methods.^[4,5] These require expensive devices and a skillful hand. The objective of this study is to evaluate the effectiveness of dural venous sinus sacrifice as a simple treatment of aggressive type cranial dAVFs.

Materials and Methods

The institutional review board approved this retrospective study. The interventional neuroradiology records in our institution were reviewed for diagnosis of aggressive dAVFs over the period of 2001–2016. These

patients were then reviewed to determine those who underwent diseased venous sinus sacrifice as a part of the treatment. The endovascular procedures were performed by either transvenous or transarterial accesses or combined, after informed consent. The embolic materials were included fibred coils and/or liquid embolic materials.

Both angiographic and clinical outcomes were recorded and categorized as shown in Tables 1 and 2. All lesions were evaluated for angiographic outcome immediately after the procedure and on follow-up, if available. Only patients who had been following up for at least 90 days were analyzed for the clinical outcome.

Other clinical data including age, sex, presenting symptoms, location of the shunts, type of the shunts, treatment complications, new shunt formation on follow-up, and duration of clinical follow-up were also obtained.

Location of the shunts was categorized based on anatomical classification by Geibprasert *et al.*^[6]

Anchalee Churojana, Ornkamol Chailerd, Atitthep Mongkolratnan, Boonrer Sangpetngam, Pattarawit Withayasuk, Ekawut Chankaew¹, Thaweesak Aurboonyawat¹, Dittapong Songsaeng

Department of Radiology, Faculty of Medicine, Siriraj Hospital, Mahidol University, ¹Department of Surgery, Division of Neurosurgery, Faculty of Medicine Siriraj Hospital, Mahidol University, Bangkok, Thailand

Address for correspondence:

Prof. Anchalee Churojana, Department of Radiology, Faculty of Medicine, Siriraj Hospital, Mahidol University, Bangkok, Thailand. E-mail: achurojana@gmail.com

Access this article online

Website: www.asianjns.org

DOI: 10.4103/ajns.AJNS_31_18

Quick Response Code:



How to cite this article: Churojana A, Chailerd O, Mongkolratnan A, Sangpetngam B, Withayasuk P, Chankaew E, *et al.* The effectiveness of dural venous sinus sacrifice as a treatment of aggressive type cranial dural arteriovenous fistulas. *Asian J Neurosurg* 2018;13:749-53.

This is an open access journal, and articles are distributed under the terms of the Creative Commons Attribution-NonCommercial-ShareAlike 4.0 License, which allows others to remix, tweak, and build upon the work non-commercially, as long as appropriate credit is given and the new creations are licensed under the identical terms.

For reprints contact: reprints@medknow.com

Definition of type of the shunts was subjected to connection between the diseased portion of the dural venous sinus to the normally functioning one. If such connection was present, the shunt was termed nonisolated sinus. If not, it was defined as isolated sinus.

Number of the patients and proportion were reported.

Results

One hundred and twenty-eight patients with 163 aggressive type cranial dAVFs who were treated with dural sinus sacrifice at our institute were recruited for analysis. Of these, 16 shunts (9.8%) underwent surgery as definite treatment while the other 147 (90.2%) were treated with endovascular approach. The demographic data and clinical presentation of the patients were listed in Table 3.

Table 1: Definition of angiographic outcome

Outcome	Characteristics
Cure	No venous drainage from preexisting shunt(s)
Not cure	Unchanged pattern of venous drainage of the preexisting shunt(s)
Progress	New pattern of venous drainage of the preexisting shunt(s) and/or new shunt formation

Table 2: Definition of clinical outcome

Outcome	Characteristics
Improve	Absence of preexisting symptom(s) and no new symptoms developed
Stable	Preexisting symptom(s) remained and no new symptoms developed
Worse	Worsening of preexisting symptom(s) and/or development of at least 1 new symptom

Table 3: Characteristic features of patients with aggressive dural arteriovenous fistulas (n=128)

Features	No.
Sex	
Male	53
Female	75
Average age (years)	55.44
Presenting symptom (%)	
Signs of increased intraocular pressure*	63 (49.2)
Headache	44 (34.4)
Tinnitus	39 (30.5)
Seizures or alteration of consciousness	27 (21.1)
Motor deficits	10 (7.8)
Visual field defects or progressive visual loss	10 (7.8)
Others**	10 (7.8)
Dementia	9 (7.0)
Aphasia	3 (2.3)
Sensory deficits	2 (1.6)

*Signs of increased intraocular pressure, i.e., chemosis, proptosis, diplopia, and ptosis; **Agraphia and alexia 1, ataxia 2, behavioral change 1, dizziness 2, hearing loss 1, asymptomatic 1, memory deficit 1, motor retardation 1, tremor, dysarthria, and urinary incontinence 1

There were 53 males and 75 females with age ranging from 20 to 93 years and mean age of 55.44 years. Majority of them had benign clinical presentation. Three most common presenting symptoms were signs of increased intraocular pressure (63/128, 49.2%), headache (44/128, 34.3%), and tinnitus (39/128, 30.5%), respectively.

The most affected dural venous sinuses were those in dorsal epidural group (91/163, 55.8%), followed by ventral epidural group (65/163, 39.9%) and lateral epidural group (7/163, 4.3%), respectively [Table 4]. The most common locations were transverse-sigmoid sinus (TSS) (61/163, 37.5%) [Figure 1], basisphenoid, and adjacent sphenoid wings which include the cavernous sinuses (65/163, 39.8%) and superior sagittal sinus (SSS) (18/163, 11.1%).

The overall angiographic cure rate of dural venous sinus sacrifice as a part of the treatment of aggressive dAVFs was 81.6% [Table 5]. Subgroup analysis was performed to separate the angiographic cure rate of the lesions affecting nonisolated sinus from those occurring in isolated sinus which was 80.1% and 94.1%, respectively. None of the shunts showed progression after treatment.

Further analysis of angiographic cure rate of the treated shunts in nonisolated sinus in each location [Table 6] showed high cure rate in lesions occurring in marginal sinus and anterior condylar vein (100% each), followed by torcula herophili (90.9%) and basisphenoid and adjacent sphenoid wings (86.2%), respectively. Relatively lower cure rate was observed in SSS (64.3%) and TSS (73.5%).

In dAVFs occurring in an isolated sinus, almost all lesions were completely obliterated, except for one lesion in anterior condylar vein [Table 7].

Of 103 patients (80.5%) who had been following up for at least 90 days (duration of follow-up ranging from 1 day to 17 years and 4 months with average at 2 years and 6 months), 75 (72.8%) had clinical improvement [Table 8] and 21 (20.4%) were clinically stable. Worsening of the presenting symptoms was observed in 7 patients (6.8%).

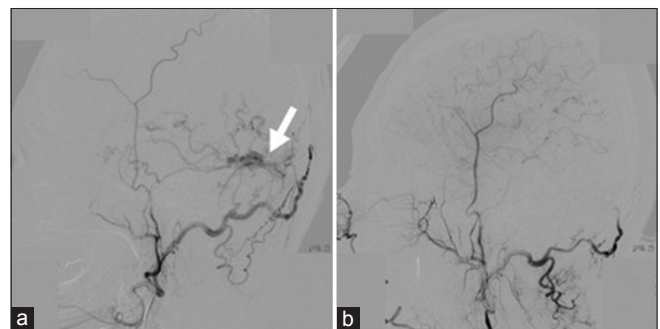


Figure 1: A 67-year-old-woman with known history of colonic cancer and cerebral venous sinus thrombosis had aggressive dural arteriovenous fistulas at right transverse-sigmoid junction (arrow in a). After treatment with diseased sinus sacrifice (b), the control angiography showed complete fistulas occlusion

Table 4: Location of the aggressive dural arteriovenous fistulas treated with endovascular and/or surgical dural venous sinus sacrifice (n=163)

Shunt location	Total, n (%)	Affected sinus	
		Nonisolated, n (%)	Isolated, n (%)
Dorsal epidural group			
Transverse-sigmoid sinus	61 (37.5)	49 (33.5)	12 (70.6)
Superior sagittal sinus	18 (11.1)	14 (9.6)	4 (23.5)
Torcula herophili	11 (6.7)	11 (7.5)	0
Marginal sinus	1 (0.6)	1 (0.7)	0
Ventral epidural group			
Basisphenoid and adjacent sphenoid wings	65 (39.8)	65 (44.5)	0
Lateral epidural group			
Falcotentorial sinus	4 (2.5)	4 (2.7)	0
Anterior condylar vein	3 (1.8)	2 (1.4)	1 (5.9)
Total	163 (100.0)	146 (89.6)	17 (10.4)

Table 5: Angiographic outcome of the aggressive dural arteriovenous fistulas treated with endovascular and/or surgical dural venous sinus sacrifice (n=163)

Angiographic outcome	Affected sinus		Total, n (%)
	Nonisolated, n (%)	Isolated, n (%)	
Cured	117 (80.1)	16 (94.1)	133 (81.6)
Not cured	29 (19.9)	1 (5.9)	30 (18.4)
Progressed	0	0	0

Analysis of long-term clinical outcome of 59 patients (46.1%) who had been following up for at least 1 year revealed rate of clinical improvement, clinical stability, and clinical worsening at 72.9%, 20.3%, and 6.8%, respectively, as shown in Table 9.

New shunt formation was observed in 16 patients (16/128, 12.5%) during follow-up with duration ranging from 33 days to 2 years and 8 months (mean 1 year and 5 months). Of these, different location of the new lesion was noted in 12 patients (75.0%).

Procedural complications were found in 5 patients (5/128, 3.9%) which include asymptomatic air embolism; dysphagia and ataxia from nontarget embolization at ascending pharyngeal artery; radiation-induced alopecia; right hemihypesthesia from left middle cerebral artery embolism; and asymptomatic subarachnoid hemorrhage from wire perforation. All of them occurred in nonisolated sinus dAVF group. No complication was encountered during treatment of dAVFs located in an isolated sinus.

Discussion

High overall angiographic cure rate of dural venous sinus sacrifice as a part of the treatment of aggressive dAVFs is demonstrated in our study. Minute effect is observed after excluding those lesions affecting the isolated sinus. Relatively lower angiographic cure rate of the shunts in SSS and TSS is detected.

Being a drainage of most venous outflow of the cerebral hemispheres, surgical resection of SSS may be intolerable

due to high risk of neurological deficits, particularly when the procedure involves a partially patent part of its posterior one-third. Multiplicity and tortuosity of the potential feeding arteries are also noted as technical limitations for endovascular treatment of lesions in this sinus.^[7] These may be attributable to relatively lower angiographic cure rate of the shunts in SSS.

There are case series reporting an excellent angiographic cure rate of sinus sacrifice as a treatment of aggressive dAVFs involving TSS. Carlson *et al.* claimed in their study a 100% angiographic cure rate of 7 shunts treated by endovascular sinus occlusion in this area.^[8] In another case series by Dawson *et al.*, 100% angiographic cure was also observed in all aggressive dAVFs treated with transvenous coiling.^[9] These are in contrary to the result in our study which can be resulted from a smaller number of the lesions analyzed and different definition of aggressiveness and type of the shunts. If we combine angiographic cure rate of both nonisolated and isolated types of the affected sinus, the angiographic cure rate in this region in our study will be increased to 78.7%.

Good clinical outcome and low procedure-related complication rate are shown in our study. However, during long-term follow-up, 16 patients (12.5%) have new shunt formation. Twelve of these (75.0%) have new lesion in different dural venous sinus. Kubo *et al.* has reported 3 cases of new shunt formation in the treated dAVFs (1 aggressive and 2 benign) with minimum period of detection at 8 months and suggested angiographic follow-up at least 1 year after transvenous embolization^[10] which is in concordance with our clinical practice. Future research is needed to determine causal relationship between new shunt formation after treatment and dural venous sinus sacrifice.

To the best of our knowledge, this is the first study to describe the effectiveness of dural venous sinus sacrifice as a treatment of aggressive dAVFs in all epidural groups in a large cohort. Main limitation of this study is the external validity. Although similarly classified into

Table 6: Angiographic outcome of sinus sacrifice as a treatment of aggressive dural arteriovenous fistulas in nonisolated sinus in each location (n=146)

Shunt location	Angiographic outcome		Total, n (%)
	Cured, n (%)	Not cured, n (%)	
Dorsal epidural group			
Transverse-sigmoid sinus	36 (73.5)	13 (26.5)	49
Superior sagittal sinus	9 (64.3)	5 (35.7)	14
Torcula herophili	10 (90.9)	1 (9.1)	11
Marginal sinus	1 (100.0)	0	1
Ventral epidural group			
Basisphenoid and adjacent sphenoid wings	56 (86.2)	9 (13.8)	65
Lateral epidural group			
Falcotentorial sinus	3 (75.0)	1 (25.0)	4
Anterior condylar vein	2 (100.0)	0	2
Total	117 (80.1)	29 (19.9)	146

Table 7: Angiographic outcome of sinus sacrifice as a treatment of aggressive dural arteriovenous fistulas in isolated sinus in each location (n=17)

Shunt location	Angiographic outcome		Total, n (%)
	Cured, n (%)	Not cured, n (%)	
Dorsal epidural group			
Transverse-sigmoid sinus	12 (100.0)	0	12
Superior sagittal sinus	4 (100.0)	0	4
Torcula herophili	0 (N/A)	0 (N/A)	0
Marginal sinus	0 (N/A)	0 (N/A)	0
Ventral epidural group			
Basisphenoid and adjacent sphenoid wings	0 (N/A)	0 (N/A)	0
Lateral epidural group			
Falcotentorial sinus	0 (N/A)	0 (N/A)	0
Anterior condylar vein	0	1 (100.0)	1
Total	16 (94.1)	1 (5.9)	17

N/A – Not applicable

Table 8: Clinical outcome of the patients with aggressive dural arteriovenous fistulas treated with endovascular and/or surgical dural venous sinus sacrifice (n=103)

Clinical outcome	n (%)
Improved	75 (72.8)
Stable	21 (20.4)
Worse	7 (6.8)
Total	103 (100.0)

Table 9: Long-term clinical outcome of the patients with aggressive dural arteriovenous fistulas treated with endovascular and/or surgical dural venous sinus sacrifice (n=59)

Clinical outcome	n (%)
Improved	43 (72.9)
Stable	12 (20.3)
Worse	4 (6.8)
Total	59 (100.0)

benign and aggressive lesions, the definition of benign and aggressive dAVFs in our study is different from

previously described study of Davies *et al.* in 1997.^[1,2] They used the presence of cortical venous drainage (CVD) to determine aggressiveness of the shunts, and hence, the lesions with only retrograde venous sinus drainage and no CVD (Grade IIa according to Cognard classification) were defined as a benign one.^[11] In our study, this type of venous drainage is one of the aggressive features of the dAVFs. In our opinion, the sequelae of chronic increased intracranial pressure from retrograded venous sinus drainage, although no CVD, may occur, with the consequence of nonhemorrhagic neurological events, varying from mild neurological symptoms to blindness.

Conclusion

Treatment of aggressive dAVFs should be tailored to each patient. With proper patient selection, dural venous sinus sacrifice is a safe and effective treatment strategy with high angiographic cure rate, good clinical outcome, and low incidence of procedural-related complication.

Declaration of patient consent

The authors certify that they have obtained all appropriate patient consent forms. In the form the patient(s) has/have given his/her/their consent for his/her/their images and other clinical information to be reported in the journal. The patients understand that their names and initials will not be published and due efforts will be made to conceal their identity, but anonymity cannot be guaranteed.

Financial support and sponsorship

Nil.

Conflicts of interest

There are no conflicts of interest.

References

1. Davies MA, Saleh J, Ter Brugge K, Willinsky R, Wallace MC. The natural history and management of intracranial dural arteriovenous fistulae. Part 1: Benign lesions. *Interv Neuroradiol* 1997;3:295-302.
2. Davies MA, Ter Brugge K, Willinsky R, Wallace MC. The natural history and management of intracranial dural arteriovenous fistulae. Part 2: Aggressive lesions. *Interv Neuroradiol* 1997;3:303-11.
3. van Dijk JM, terBrugge KG, Willinsky RA, Wallace MC. Clinical course of cranial dural arteriovenous fistulas with long-term persistent cortical venous reflux. *Stroke* 2002;33:1233-6.
4. Zhang Y, Li Q, Huang QH. Embolization of a superior sagittal sinus dural arteriovenous fistula under intrasinus balloon protection: A case report. *Interv Neuroradiol* 2015;21:94-100.
5. Choi BJ, Lee TH, Kim CW, Choi CH. Reconstructive treatment using a stent graft for a dural arteriovenous fistula of the transverse sinus in the case of hypoplasia of the contralateral venous sinuses: Technical case report. *Neurosurgery* 2009;65:E994-6.
6. Geibprasert S, Pereira V, Krings T, Jiarakongmun P, Toulgoat F, Pongpech S, *et al.* Dural arteriovenous shunts: A new classification of craniospinal epidural venous anatomical bases and clinical correlations. *Stroke* 2008;39:2783-94.
7. Halbach VV, Higashida RT, Hieshima GB, Rosenblum M, Cahan L. Treatment of dural arteriovenous malformations involving the superior sagittal sinus. *AJNR Am J Neuroradiol* 1988;9:337-43.
8. Carlson AP, Alaraj A, Amin-Hanjani S, Charbel FT, Aletich V. Endovascular approach and technique for treatment of transverse-sigmoid dural arteriovenous fistula with cortical reflux: The importance of venous sinus sacrifice. *J Neurointerv Surg* 2013;5:566-72.
9. Dawson RC 3rd, Joseph GJ, Owens DS, Barrow DL. Transvenous embolization as the primary therapy for arteriovenous fistulas of the lateral and sigmoid sinuses. *AJNR Am J Neuroradiol* 1998;19:571-6.
10. Kubo M, Kuwayama N, Hirashima Y, Kurimoto M, Takaku A, Endo S, *et al.* Dural arteriovenous fistulae developing at different locations after resolution of previous fistulae: Report of three cases and review of the literature. *AJNR Am J Neuroradiol* 2002;23:787-9.
11. Cognard C, Gobin YP, Pierot L, Bailly AL, Houdart E, Casasco A, *et al.* Cerebral dural arteriovenous fistulas: Clinical and angiographic correlation with a revised classification of venous drainage. *Radiology* 1995;194:671-80.