

## Case Report

# Major Depression and Obsessive-compulsive Disorder Treated with Deep Brain Stimulation of Bilateral Nucleus Accumbens: The First Case of Turkey

## Abstract

Deep brain stimulation (DBS) is a new alternative treatment for treatment-resistant major depression (MD) and obsessive-compulsive disorder (OCD). Various DBS targets were defined for MD and OCD. Nucleus accumbens (NAcc) comes out among the other targets in patients with MD and comorbid OCD when physiopathology and limited side effects are taken into account. We report a 27-year-old male with MD and OCD who was treated by bilateral NAcc-DBS. The aim of this study is to discuss NAcc as a DBS target in patients with MD and OCD and to report the first case of a psychiatric disorder treated with DBS in Turkey.

**Keywords:** Deep brain stimulation, major depression, nucleus accumbens, obsessive-compulsive disorder

**Sabri Aydın,  
Huseyin Canaz,  
Baris Topcular<sup>1</sup>,  
Zuzana Benackova<sup>2</sup>**

*Departments of Neurosurgery  
and <sup>1</sup>Neurology, Istanbul Bilim  
University, Istanbul, Turkey,  
<sup>2</sup>Clinic of Psychiatry, Kosice,  
Slovakia*

## Introduction

Obsessive-compulsive disorder (OCD) and major depression (MD) are common and disabling psychiatric disorders.<sup>[1,2]</sup> Patients with MD or OCD may not response satisfactory to pharmacological, psychotherapeutic, or somatic treatments.<sup>[3]</sup> After nonresponse to two competent treatment steps, a patient is diagnosed with treatment-resistant depression, which is associated with illness chronicity, a reduced quality of life, and a higher risk for suicide.<sup>[4]</sup>

The majority of neurosurgical procedures to treat psychiatric illnesses were targeted to disconnect the frontal lobe from the basal ganglia or to intercept the anatomic pathways within the limbic system. In recent years, deep brain stimulation (DBS) has been intended in the treatment of MD and OCD. DBS aims to modulate dysfunctional neuronal networks involved in depression. Three targets were defined in a hypothesis-driven way for MD: nucleus accumbens (NAcc), subgenual cingulate cortex (Cg25), and the anterior limb of the capsula interna. Between supposed targets, NAcc is especially interesting because of its major involvement in the pathophysiology of both OCD and MD. Among three

regions, DBS to the NAcc has supplied relieved antidepressant effects over up to 4 years.<sup>[5,6]</sup>

In this article, we present the case of a patient who was diagnosed as MD and OCD and was treated with NAcc-DBS. To the best of our knowledge, this is the first case of a psychiatric disorder treated with DBS in Turkey.

## Case Report

Our patient was a 27-year-old male who had suffered from severe MD with mild anxiety and OCD since 2006. His symptoms were depressed mood, profound anhedonia, decreased sleep, decreased appetite, fatigue, significant psychomotor retardation, feelings of worthlessness and guilt, and poor concentration. He had attempted suicide three times. He has been hospitalized six times since he was 12 years old. He was administered electroconvulsive therapy four times. His psychiatric diagnosis was a severe depressive episode without psychotic symptoms, moderate generalized anxiety disorder, and moderate OCD according to Tenth Revision of the International Statistical Classification of Diseases and Related Health Problems, when he was referred to us. His Hamilton Depression Rating Scale (HDRS) score was 35 and

### Address for correspondence:

Dr. Huseyin Canaz,  
Şişli Florence Nightingale  
Hastanesi, Abide-i Hürriyet  
Cad. No: 164, Şişli, Istanbul,  
Turkey.  
E-mail: huseyin.canaz@istanbulbilim.edu.tr

### Access this article online

**Website:** www.asianjns.org

**DOI:** 10.4103/ajns.AJNS\_319\_16

### Quick Response Code:



**How to cite this article:** Aydın S, Canaz H, Topcular B, Benackova Z. Major depression and obsessive-compulsive disorder treated with deep brain stimulation of bilateral nucleus accumbens: The first case of Turkey. Asian J Neurosurg 2018;13:842-4.

This is an open access journal, and articles are distributed under the terms of the Creative Commons Attribution-NonCommercial-ShareAlike 4.0 License, which allows others to remix, tweak, and build upon the work non-commercially, as long as appropriate credit is given and the new creations are licensed under the identical terms.

For reprints contact: reprints@medknow.com

Yale-Brown Obsessive-Compulsive Scale (Y-BOCS) score was 20. He was under follow-up with venlafaxine 300 mg/day and psychotherapy. His MD was not controlled with various antidepressants, electroconvulsive therapy, transcranial magnetic stimulation, and cognitive behavioral therapy.

In August 2015, surgical treatment with DBS was performed. The surgical procedure was performed under local anesthesia and sedation using the Leksell (Elekta, Stockholm, Sweden) stereotactic frame with ring system. The surgical targets were bilateral NAcc. Their positions were localized anatomically by direct visualizing on T2-weighted and inversion recovery magnetic resonance (MR) imaging. FrameLink 2.0 software (Medtronic, Inc., Minneapolis, MN, USA) was used for the application of computed tomography-MR fusion technique and reformatted the MR image to the anterior commissure-posterior commissure (AC-PC) plane to yield the calculated coordinates for the NAcc, with the aid of Schaltenbrand and Wahren stereotactic atlas [Figure 1a-c]. Quadripolar electrodes (Model 3389, Medtronic, Inc.) were implanted in the bilateral NAcc in a single session. Only macrostimulation was performed without microelectrode recording (MER) for both NAcc. The patient had smiled and his breathing speed had accelerated during the macrostimulation of right NAcc. He told that he could not stop smiling. Although no side effects were seen during the macrostimulation of left NAcc, the patient told that he had a feeling and he was unable to define that it was not negative. The final stereotactic X, Y, Z coordinates were 87.7, 102.8, 103, respectively, for right NAcc and 106.2, 102.8, 100.6, respectively, for left NAcc. A dual-channel pulse generator (Kinetra Model 7428, Medtronic, Inc.) was connected to the leads and implanted subclavicularly in the right chest wall during the same surgical procedure. No complication occurred during or after the surgery. The activation of the electrodes took place 7 days after the surgery. The stimulation parameters were amplitude 2V, pulse width 90 ms, and frequency 130 Hz with permanent pulse-train square wave stimulation.

In the 6-month follow-up after surgery, his psychological symptoms were improved. He was able to express his self-better. He had turned back to his old school and had a new girlfriend. He was still under antidepressant medication. There was reduction of the obsessions and

compulsions. His HDRS score was 15 and Y-BOCS score was 8, 10 months after surgery.

Consent of the patient was taken to have his data published. This publication is approved by our Institution's Ethics Committee.

## Discussion

MD is a common and potentially life-threatening disorder characterized by various symptoms, including depressed mood, anhedonia, fatigue, hopelessness, psychomotor retardation, anxiety, apathy, cognitive deficits, and suicidal tendency. Nearly 20% of patients with MD do not respond to pharmacotherapy and psychotherapy.<sup>[7]</sup>

DBS is a useful alternative treatment for treatment-resistant MD.<sup>[8]</sup> Different targets have been used in the treatment of behavior disorders, including the temporal lobe amygdala, hypothalamus, subcaudate white matter, NAcc, Cg25, and cingulate gyrus.<sup>[9]</sup> Among these targets, NAcc is an important intersection point in the pathophysiology of both MD and OCD.

It is hypothesized that the NAcc plays an important role in the abnormal reward process and motivations in MD.<sup>[10]</sup> NAcc takes projections from anterior cingulate cortex, agranular insular cortex, and orbitofrontal cortex. Since the center of NAcc receives input from all of these areas, the pod receives input mainly from subgenual and pregenual cingulate cortices. NAcc then projects to the dorsomedial nucleus of thalamus by the ventral tegmental area, ventral pallidum, and substantia nigra – which in turn projects back to the prefrontal cortex, orbitofrontal cortex, anterior cingulate cortex, amygdala, and hypothalamus; this figures the limbic ring of basal ganglia. The association of the NAcc with areas affected in depression makes it an appropriate target for DBS.<sup>[11]</sup> It is shown that NAcc-DBS modulates NAcc activity and frontostriatal connectivity, and thereby reverses disease related hyperactivity of the cortical–striatal–thalamo–cortico loop in OCD patients.<sup>[1]</sup> On the other hand, no serious adverse effects due to stimulation of NAcc was reported. In the guidance of these previous studies, we decided NAcc as our target for this patient with MD and OCD.

There is not a defined MER pattern for NAcc, so emotional and motor responses in macrostimulation are important for confirmation of the target as in our case. Smiling, palpitation, and acceleration of breathing speed were motor side effects of NAcc for this patient.

## Conclusion

Various studies showed that DBS is a promising alternative nonablative treatment for MD and OCD. On the other hand, further research with larger groups of patients with MD and comorbid OCD are still needed to take place in standard treatment algorithms.

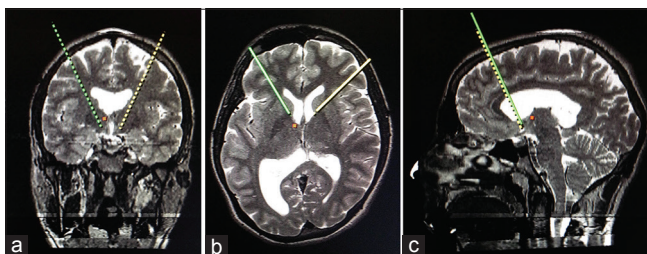


Figure 1: (a-c) Stereotactic targeting images of bilateral nucleus accumbens

## Financial support and sponsorship

Nil.

## Conflicts of interest

There are no conflicts of interest.

## References

1. Kohl S, Gruendler TO, Huys D, Sildatke E, Dembek TA, Hellmich M, *et al.* Effects of deep brain stimulation on prepulse inhibition in obsessive-compulsive disorder. *Transl Psychiatry* 2015;5:e675.
2. Rush AJ, Trivedi MH, Wisniewski SR, Nierenberg AA, Stewart JW, Warden D, *et al.* Acute and longer-term outcomes in depressed outpatients requiring one or several treatment steps: A STAR\*D report. *Am J Psychiatry* 2006;163:1905-17.
3. Bewernick B, Schlaepfer TE. Update on neuromodulation for treatment-resistant depression. *F1000Res* 2015;4. pii:F1000 Rev-1389.
4. Rush AJ, Warden D, Wisniewski SR, Fava M, Trivedi MH, Gaynes BN, *et al.* STAR\*D: Revising conventional wisdom. *CNS Drugs* 2009;23:627-47.
5. Bewernick BH, Kayser S, Sturm V, Schlaepfer TE. Long-term effects of nucleus accumbens deep brain stimulation in treatment-resistant depression: Evidence for sustained efficacy. *Neuropsychopharmacology* 2012;37:1975-85.
6. Aouizerate B, Cuny E, Bardinet E, Yelnik J, Martin-Guehl C, Rotge JY, *et al.* Distinct striatal targets in treating obsessive-compulsive disorder and major depression. *J Neurosurg* 2009;111:775-9.
7. Cleary DR, Ozpinar A, Raslan AM, Ko AL. Deep brain stimulation for psychiatric disorders: Where we are now. *Neurosurg Focus* 2015;38:E2.
8. Millet B, Jaafari N, Polosan M, Baup N, Giordana B, Haegelen C, *et al.* Limbic versus cognitive target for deep brain stimulation in treatment-resistant depression: Accumbens more promising than caudate. *Eur Neuropsychopharmacol* 2014;24:1229-39.
9. Jimenez F, Nicolini H, Lozano AM, Piedimonte F, Salin R, Velasco F. Electrical stimulation of the inferior thalamic peduncle in the treatment of major depression and obsessive compulsive disorders. *World Neurosurg* 2013;80:S30.e17-25.
10. Morishita T, Fayad SM, Higuchi MA, Nestor KA, Foote KD. Deep brain stimulation for treatment-resistant depression: Systematic review of clinical outcomes. *Neurotherapeutics* 2014;11:475-84.
11. Hauptman JS, DeSalles AA, Espinoza R, Sedrak M, Ishida W. Potential surgical targets for deep brain stimulation in treatment-resistant depression. *Neurosurg Focus* 2008;25:E3.