

Functional Outcome of Right-sided Thoracotomy for Tuberculosis of the Dorsal Spine

Abstract

Introduction: In pathologies of the spine involving dorsal vertebrae, it is a routine practice to go for left-sided thoracotomy. It is so because in this approach, we encounter the aorta before reaching the concerned dorsal vertebra which is easy to handle as compared to the inferior vena cava on the right-sided approach. This is because the aorta is a structure with thick muscular wall. However, there are conditions which demand right-sided thoracotomy for better outcome such as idiopathic scoliosis and dorsal spine tuberculosis (TB). The selection of side of thoracotomy should be done on case-to-case basis. **Study Design:** This was a prospective study of 10-year duration. **Purpose:** The purpose of the study was to analyze whether it is more rational to do thoracotomy from the right side than left for dorsal spine TB. **Materials and Methods:** The study was performed on 102 dorsal Koch patients with neurological deficit who required surgical decompression. Magnetic resonance imaging of those patients was analyzed. Seventy-two patients had predominant right-sided lesion. Left and central types of predominant results were in 19 and 11 patients, respectively. Among these 102 patients, 82 were operated with right-sided thoracotomy, whereas 20 were operated for left-sided thoracotomy. Preoperative and postoperative kyphosis angle (K angle), average surgical time, mean blood loss, and visual analog scale (VAS) score were calculated. The SPSS 17 software was used for the statistical analysis. **Results:** Right thoracic approach turned out to be better approach than left in dorsal Koch spine. The average surgical time and mean blood loss were less in the right thoracotomy than left. Postoperative K angle and VAS were improved in the right thoracic approach as compared to left. **Conclusion:** Tubercular debris in the dorsal spine predominantly is on the right side, and right thoracotomy gives better results as there is better decompression of lesion.

Keywords: Anterior decompression, dorsal spine, thoracotomy, tuberculosis

Introduction

Spinal tuberculosis (TB) is known to mankind for decades and has been found in Egyptian mummies dating back in 3400 BC. Spinal deformity and paralysis due to TB was first described by Percival Potts, hence also known as Pott's spine.^[1] TB is a disease of concern in many countries in the world. Pulmonary TB is the most common form of TB. Still, extrapulmonary TB accounts for 15%–20% of all TB cases.^[2] India has the maximum number of patients suffering from TB. The skeletal system is involved in 1%–2% of all cases. Spinal TB is the most common form of skeletal TB, constituting about 50% of all cases of skeletal TB.^[3] Spinal TB is a very dreaded entity as it involves neurological complications which occurs in 10%–43% of cases. TB of the dorsal spine is commonly associated with

neurological deficits due to the narrower spinal canal and physiological kyphosis, which forces necrotic tissue into the spinal canal.

The trend of treatment modalities has progressed from “reducing the mortality” to “reducing the morbidity” to “reducing the deformity.” The objective of treatment was to attain disease quiescence by natural immunity before 1950. With the revolutionary advent of effective combination chemotherapy in the 1950s, the mortality rate among patients with spinal TB has reduced. Despite the efficacy of antitubercular drugs, there was a resulting kyphosis. Now, the aim of treatment is to cure the disease, with no sequel of neural complications and an almost near normal spine. The work of Oga *et al.* demonstrated that *Mycobacterium* spp. does not form extensive biofilms. When antitubercular

**Sudhir Srivastava,
Nandan Marathe,
Sunil Bhosale,
Aditya Raj,
Kiran Dhole,
Harsh Agarwal**

*Department of Orthopaedics,
Seth G.S. Medical College
and K.E.M Hospital, Mumbai,
Maharashtra, India*

Address for correspondence:

*Dr. Nandan Marathe,
Department of Orthopaedics,
6th Floor MSB, Seth G.S.
Medical College and K.E.M
Hospital, Aurobindo Marg,
Parel, Mumbai - 400 012,
Maharashtra, India.
E-mail: nandanmarathe88@
gmail.com*

Access this article online

Website: www.asianjns.org

DOI: 10.4103/ajns.AJNS_311_19

Quick Response Code:



How to cite this article: Srivastava S, Marathe N, Bhosale S, Raj A, Dhole K, Agarwal H. Functional outcome of right-sided thoracotomy for tuberculosis of the dorsal spine. *Asian J Neurosurg* 2020;15:311-4.

Submitted: 16-Oct-2019

Revised: 05-Feb-2020

Accepted: 08-Feb-2020

Published: 07-Apr-2020

This is an open access journal, and articles are distributed under the terms of the Creative Commons Attribution-NonCommercial-ShareAlike 4.0 License, which allows others to remix, tweak, and build upon the work non-commercially, as long as appropriate credit is given and the new creations are licensed under the identical terms.

For reprints contact: reprints@medknow.com

chemotherapy regimen is being used, the use of an implant is considered safe and is well accepted at present.^[4,5]

Conventionally, for anterior decompression in TB of the dorsal spine, left-sided thoracotomy was the preferred approach as the aorta on the left side has a thicker muscular wall and is easier to handle. However, when we consider other entities in dorsal spine, right-sided thoracic curve is the most common idiopathic scoliotic curve. Anterior release and instrumentation are commonly performed through a right thoracotomy. Even thoracoscopic release and instrumentation is done from the right side. Thus, right thoracotomy is an equally safe and a time-tested approach, and there are numerous references in literature to suggest the same.^[6]

The aim of this study is to study the merit of right-sided approach and its functional outcome in TB of the dorsal spine. Classical dorsal Koch with deficit has anterior compression with the compressive elements being tense abscess, granulation tissue, and necrotic disc/bony tissue. Out of this, the pus is always drained out regardless of whether a right- or left-sided approach is taken for the thoracotomy. However, the other elements causing the compression are predominantly on one side. Tubercular pus and the other compressive elements follow the path of least resistance. Thus, vena cava on the right side exerts lesser resistance as compared to the aorta. Hence, the collection should be more on the right side due to lesser resistance offered by the vena cava on the right side.

Materials and Methods

This was a prospective study carried out at a tertiary care center with follow-up period of 10 years. The institutional review board approval was obtained before the commencement of the study. This study did not receive any funding. None of the authors have any conflicts of interest to declare. Hundred and two patients with biopsy-proven dorsal spine TB with neurological deficit requiring surgery were included in the study. Patients with additional lesion in cervical or lumbar spine, patients without neurodeficit, or patients with previous spine surgery were excluded. All patients were operated by single surgeon. Study participants were radiologically assessed by means of magnetic resonance imaging (MRI). Patients were divided into three groups (Left/right and center) on the basis of lesion. Right-sided lesion was located in 72 patients, left sided in 19 patients, and central in 11 patients. The analysis of the operation theater reports, patient records, and radiographs was performed. As per the institutional protocol, all patients with Frankel Grade C or D were on bed rest and underwent chemotherapy for a minimum period of 3–6 weeks, respectively, before being considered for surgery. This minimum period of 3 weeks is considered the “middle path regime” popularized by Tuli.^[7] Surgery is considered if patients fail to improve after 3–4-weeks of the “middle path regime.” Patients with Frankel Grade A

or B underwent surgery as early as possible. In the surgical procedure, thoracotomy and decompression were done followed by sublaminar wire fixation. Right-sided thoracotomy was done in 82 patients and left-sided thoracotomy was done in 20 patients. Case record form included patient's age, gender, diagnosis, vertebral levels involved, levels fused, preoperative and postoperative kyphosis angles (K angle), preoperative and postoperative neurological status (Frankel Grading), estimated blood loss, surgical time, and postoperative complications were noted.

Radiographic evaluation

Preoperative radiographs included standing anteroposterior (AP) and lateral views of the dorsal spine. In patients with no ambulatory power in their lower limbs and imminent paralysis, supine radiographs were acquired. Preoperative MRI was performed for all patients. AP and lateral radiographs of the dorsal spine were performed postoperatively and during follow-up at 3, 6, 12, and 24 months. The K angle was calculated by drawing lines from the upper to the lower border of the first normal vertebra above and below the diseased area, respectively. Computed tomography was performed 1 year postoperatively in patients in whom fusion could not be assessed on X-ray. Anterior fusion was assessed by the presence of bone bridging the vertebrae immediately proximal and distal to the reconstructed area.

Surgical procedure

The surgeon who operated all the cases in our study decided to do thoracotomy according to predominant side of lesion. In 11 cases with central type of lesion, ten were operated with right thoracotomy and one with left thoracotomy. In all patients, semilunar incision was taken in the paramedian region [Figure 1]. This incision is good enough for anterior decompression as well as posterior fixation. In right-sided thoracotomy approach, once ribs were excised, abscess was reached directly without encountering vessels. Abscess wall was cut vertically and the anteromedial part of wall was used to protect vessels. In left-sided thoracotomy, abscess was delineated, and plane was developed between anterior longitudinal ligament and aorta. Malleable retractor was used to retract and protect great vessels. Diseased spine was resected and thecal sac was exposed for adequate decompression. Autologous bone graft was put between healthy bone ends [Figure 2]. In the end, posterior fixation with sublaminar wire and Hartshill loop rectangle was done. Closure was done in layers over intercostal drain. The patient was mobilized after chest drain removal using a thoracolumbosacral orthosis. Standing and walking were started once the patient regains ambulatory power. Intraoperative samples from all patients were sent for culture and sensitivity. Antituberculous chemotherapy was administered for 18 months. In cases of drug-resistant TB, antituberculous chemotherapy was administered for 2 years.

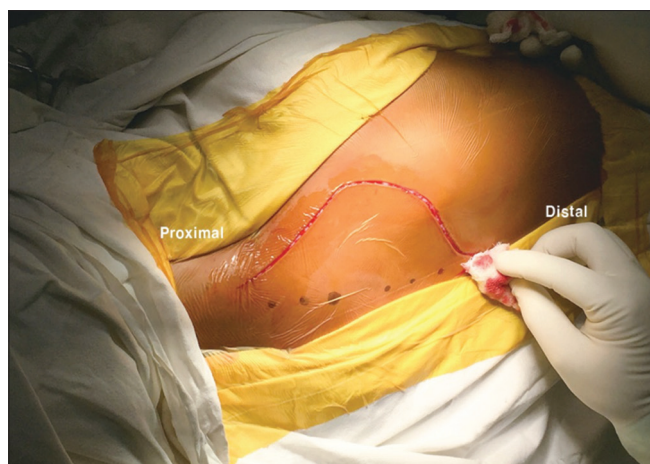


Figure 1: Semilunar incision: Ends of the incision slant toward the midline

Results

All 102 patients underwent a minimum follow-up of 18 months, with a mean follow-up of 48.23 ± 22.5 months (range, 18–145 months). During the presentation, the mean value of preoperative kyphosis was $21.02^\circ \pm 7.58^\circ$ (range, 8° – 47°). The average number of vertebral bodies involved was 3.25 ± 0.39 (range, 2–4) with D5–6 being the most common involved level [Table 1].

Out of 102, predominant site of lesion was on the right side (72 patients). Lesion was on the left side in 19 patients and central in 11 patients. The mean immediate postoperative K angle was $8.7^\circ \pm 4.16^\circ$ (range, 1° – 23°) in right-sided thoracotomy group as compared to $13^\circ \pm 5.15^\circ$ (range, 3° – 27°) in left thoracotomy group. The average surgical time in right-sided thoracotomy group was 125 min (90 – 195 ± 30.7) as compared to 162 min (100 – 210 ± 45.7) in left-sided thoracotomy. The mean blood loss was 685 ml in right thoracotomy, whereas 860 ml in left thoracotomy.

All ten patients with Frankel Grade D recovered completely. Out of 65 patients with Frankel Grade C, 52 patients recovered fully and 12 patients recovered to Grade D, whereas one patient remained as Grade C. Out of 27 patients with Frankel Grades A and B, twenty patients recovered completely, six patients recovered to Grade D, and one patient remained paraplegic. No patient deteriorated following surgery [Table 2]. Fusion was achieved in all cases.

Descriptive statistics, including the means and standard deviations, were calculated for variables using SPSS software 17.0 (SPSS Inc., Chicago, IL, USA). The preoperative K angle and visual analog scale score were compared with postoperative values using a paired *t*-test.

Discussion

The dorsal spine is the most affected site in spinal TB. Lesion involves paradiscal anterior column predominantly. The optimum surgical treatment of dorsal TB has always

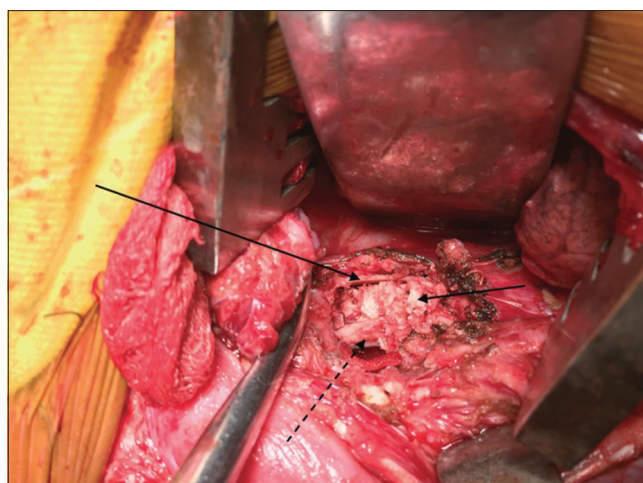


Figure 2: Anterior reconstruction with strut graft between the proximal and distal bone ends

Table 1: Vertebral level of affection

Levels affected	Frequency (%)
D1-2	5 (4.90)
D2-3	9 (8.82)
D2-4	3 (2.94)
D2-5	3 (2.94)
D3-4	5 (4.90)
D3-5	3 (2.94)
D3-6	2 (1.96)
D4-5	9 (8.82)
D4-6	2 (1.96)
D5-6	26 (25.49)
D5-7	5 (4.96)
D6-7	2 (1.96)
D6-8	8 (7.84)
D7-8	7 (6.86)
D8-10	3 (2.94)
D8-9	5 (4.96)
D9-10	4 (3.92)
D10-12	1 (0.98)

Table 2: Neurological status

Number of patients	
Preoperative Frankel stage	Postoperative Frankel stage
A (10)	E (4), D (5), A (1)
B (17)	E (6), D (11)
C (65)	E (52), D (12), C (1)
D (10)	E (10)
E (0)	

been a controversial issue.^[8] Radical anterior decompression and bone grafting was successfully demonstrated in 1956 by Hodgson and Stock.^[9] Anterior decompression is routinely done through left thoracotomy approach. Approaching for lesion in the anterior part of the dorsal spine from the left side, the structure we encounter is the aorta. It has a thicker wall and is thus easier to handle and less traumatic. In case

of right-sided thoracotomy, the inferior vena cava which has a thinner wall is to be handled carefully. Thus, there is more chance of damage. However, in case of classical dorsal Koch spine with deficit, we suggest with our study that right-sided thoracotomy is more beneficial than left.

In most cases of dorsal Koch spine, side of lesion is predominantly on the right side. This is so because pus formed in TB follows a path of least resistance which is exerted by vena cava as compared to higher resistance in the left side due to the thick walls of the aorta. Other compressing elements in dorsal Koch spine with deficit, granulation tissue, and necrotic disc are on right side predominantly. Hence, it is better to do right thoracotomy for adequate anterior decompression.

In our study, we observed that tubercular abscess has thicker wall. Opening the wall from predominant side will reach lesion directly. Vertical incision in abscess wall and reflecting the anteromedial wall of abscess helped us to protect vascular structures. Another thing which came to our observation was thrombosed segmental vessels. Thus, less time was spent in securing segmental vessels. Overall decompression from the predominant side of lesion was safer and quicker. In our study, fixation after anterior decompression was done mainly with the help of sublaminar wire and Hartshill loop rectangle. This is because of difficulties faced in passing pedicular screws in lateral position. Passing sublaminar wire from the right side is easier for right-handed person [Figure 3].

Our study showed positive results for right-sided thoracotomy. The average surgical time and the mean blood loss were significantly less for right-sided thoracotomy as compared to the left. Neurological recovery after the right

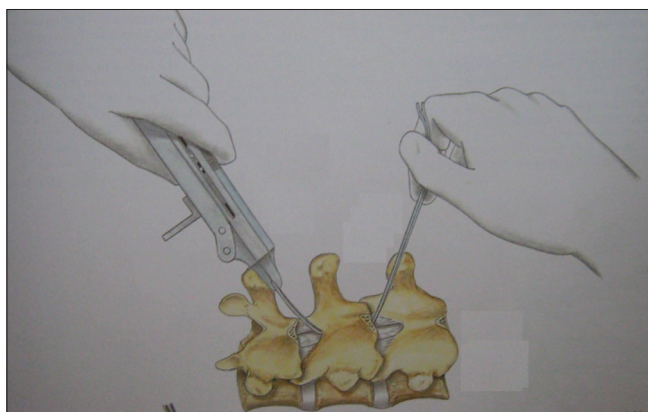


Figure 3: Sublaminar wiring: Note ease of right-sided sublaminar wiring

thoracotomy was also superior to the left thoracotomy. No patient remained nonambulatory (Frankel Grades A–C) after the right thoracotomy approach as compared to two patients out of twenty in left thoracotomy.

Thus, right-sided thoracotomy can be more beneficial in the dorsal Koch spine with neurodeficit provided predominant side of lesion being taken into consideration. However, a multicenter, multisurgeon study with a larger sample size is needed to further validate our findings.

Conclusion

In most cases of tuberculosis of the thoracic spine, the debris are predominantly on the right side following the path of least resistance i.e. the inferior vena cava. Also, passing sublaminar wire is easier from the right side for a right handed surgeon. Hence, preoperative MRI should be assessed to check site of maximum compression and side of thoracotomy approach should be decided accordingly.

Financial support and sponsorship

Nil.

Conflicts of interest

There are no conflicts of interest.

References

1. Sai Kiran NA, Vaishya S, Kale SS, Sharma BS, Mahapatra AK. Surgical results in patients with tuberculosis of the spine and severe lower-extremity motor deficits: A retrospective study of 48 patients. *J Neurosurg Spine* 2007;6:320-6.
2. Fanning A. Tuberculosis: 6. Extrapulmonary disease. *CMAJ* 1999;160:1597-603.
3. Moon MS. Tuberculosis of spine: Current views in diagnosis and management. *Asian Spine J* 2014;8:97-111.
4. Oga M, Arizono T, Takasita M, Sugioka Y. Evaluation of the risk of instrumentation as a foreign body in spinal tuberculosis. *Clinical and biologic study. Spine (Phila Pa 1976)* 1993;18:1890-4.
5. Ha KY, Chung YG, Ryoo SJ. Adherence and biofilm formation of *Staphylococcus epidermis* and *Mycobacterium tuberculosis* on various spinal implants. *Spine* 2004;29:1-6.
6. Pessereau G, Bourdet P, Vittori J, Scarbouchi L. Right thoracotomy at onset in the transpleural approach to dorsal Pott's disease. *Lyon Chir* 1962;58:474-9.
7. Tuli SM. Results of treatment of spinal tuberculosis by "middle-path" regime. *J Bone Joint Surg Br* 1975;57:13-23.
8. Khoo LT, Mikawa K, Fessler RG. A surgical revisit of Pott distemper of the spine. *Spine J* 2003;3:130-45.
9. Hodgson AR, Stock FE. Anterior spinal fusion a preliminary communication on the radical treatment of Pott's disease and Pott's paraplegia. *Br J Surg* 1956;44:266-75.