

A Rare Case of Spinal Extradural Arachnoid Cyst with Cord Compression

Abstract

Spinal extradural arachnoid cysts are rare lesions which typically involve the thoracic spine and are an asymptomatic condition of unknown origin. They may also produce symptoms by compressing the spinal cord or nerve roots. Surgery is the treatment of choice in such lesions, but asymptomatic patients can be managed conservatively. We present a case of symptomatic, probable traumatic origin, spinal arachnoid cyst at our center in Hospital Kuala Lumpur, Malaysia. Magnetic resonance imaging spine showed well-defined, nonenhancing extradural cystic lesion from T5 to T6 vertebrae level compressing spinal cord anteriorly. The patient underwent T5, T6 laminoplasty, T4 partial laminectomy and excision of the cyst. Histologically, the cyst wall comprised of collagen and meningothelial cells. This surgical intervention achieved neurological improvement in terms of motor power in our follow-up of this patient.

Keywords: Extradural arachnoid cyst, paraparesis, spinal cord lesions

Introduction

Spinal arachnoid cysts are an uncommon entity, commonly seen in patients who are 30–50 years of age, with slight female predominance. They are cerebrospinal fluid (CSF) filled meningeal cysts which are intradural, extradural, or perineural spaces. The most common location is mid-thoracic and thoracolumbar region, and usually located posteriorly. Arachnoid cysts are developmental lesions that arise from the splitting of the arachnoid membrane and contain fluid that have similar consistency to the CSF. Rarely, it may follow infection or trauma. These cysts seldom cause spinal cord compression. In the spine region, they almost always communicate with the intrathecal subarachnoid space through a small defect in the dura. The standard of treatment of patients with neurological symptoms is surgery which includes complete resection of cyst wall and drainage of the cyst. We present a case of symptomatic spinal arachnoid cyst which required surgical intervention.

Case Report

A 35-year-old male patient with no known medical illness presented with a history of bilateral lower limb ascending weakness for the past 2 months associated with numbness

of the lower limbs and instability during walking. The onset of the symptoms was insidious and gradual progressive in nature. There were no history of trauma, spinal surgery, infection, or spinal anesthesia. There was no urinary or bowel involvement. On examination, the power of both lower limbs was 4/5. Deep tendon reflex was bilaterally brisk, Babinski's down going. There was reduced sensation from T6 below. Magnetic resonance imaging (MRI) of the spine revealed well-defined, nonenhancing extradural cystic lesion within the spinal canal measuring 1.8 cm × 2.7 cm × 5.2 cm extending from mid T5 to T6 vertebrae segment. It appeared hypointense on T1 and hyperintense on T2, compressing spinal canal anteriorly [Figure 1]. Patient underwent T5, T6 laminoplasty, T4 partial laminectomy and excision of cyst on June 6, 2016. The cystic membrane was exposed and excised [Figure 2]. After excision of the cyst the dorsal portion of the cord gradually regained its normal diameter and adequate cord pulsation returned. The postoperative period was uneventful. The patient had a complete neurological recovery with the power of both lower limbs 5/5 on the 3rd postoperative day. Histopathological examination of the resected specimen confirmed the diagnosis of an arachnoid cyst [Figure 3]. On regular follow up, he could walk without difficulty with no limb weakness.

This is an open access journal, and articles are distributed under the terms of the Creative Commons Attribution-NonCommercial-ShareAlike 4.0 License, which allows others to remix, tweak, and build upon the work non-commercially, as long as appropriate credit is given and the new creations are licensed under the identical terms.

For reprints contact: reprints@medknow.com

How to cite this article: Lin LC, Jason R. A rare case of spinal extradural arachnoid cyst with cord compression. *Asian J Neurosurg* 2018;13:468-70.

**Lee Chun Lin,
R. Jason**

*Department of Neurosurgery,
Hospital Kuala Lumpur,
Malaysia*

Address for correspondence:

*Dr. Lee Chun Lin,
Department of Neurosurgery,
Hospital Kuala Lumpur,
Jalan Pahang, 50586 Wilayah
Persekutuan, Malaysia.
E-mail: istante88@gmail.com*

Access this article online

Website: www.asianjns.org

DOI: 10.4103/ajns.AJNS_310_16

Quick Response Code:



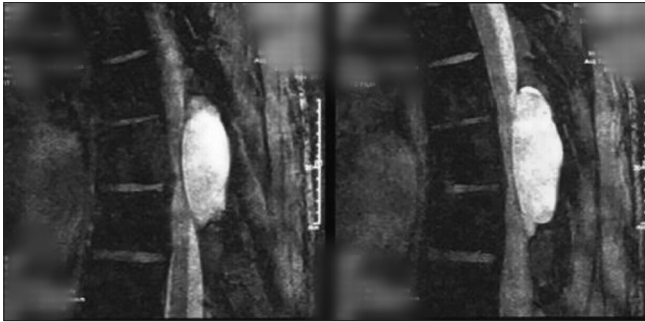


Figure 1: Magnetic resonance imaging spine (axial and sagittal) showed well-defined extradural cystic lesion at level of T5 and T6

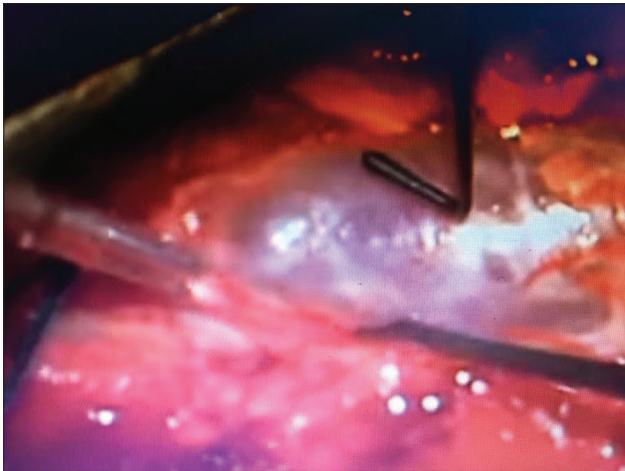


Figure 2: Intraoperative findings of extradural cystic lesion

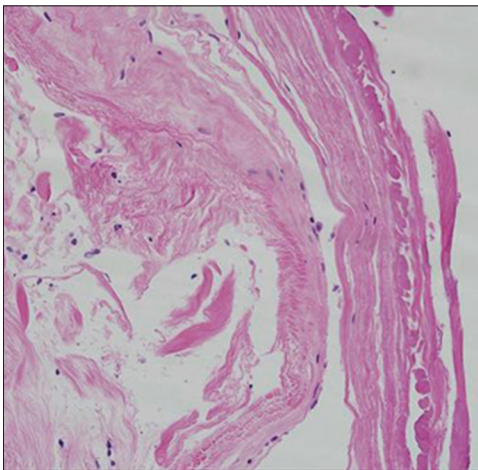


Figure 3: Histology – arachnoid cyst with collagenous fibers & membrane with flat lining cells

Discussion

Spinal arachnoid cysts were first described by Spiller in 1903, although the first reported case can be traced back to 1898 by Nonne (an autopsy finding). Most reported cases are solitary lesion and occur most frequently in the thoracic spine (65%), followed by lumbar and lumbosacral (13%), thoracolumbar (12%), sacral (6.6%), and cervical (3.3%) regions.^[1-5] They could occur either dorsal or ventral to

the cord, with the former being more common. Thoracic extradural cysts occur mainly in adolescents, whereas lumbar and sacral cysts are more often found in adults.^[6,7] These lesions have been reported in all age groups with a slight preponderance in females.^[6] Their precise pathogenesis and etiology remain uncertain; however, congenital, traumatic, or inflammatory^[8] mechanisms have been proposed. Pulsatile CSF dynamics^[8] osmotic gradient between the subarachnoid space and cyst as well as the one-way valve-like mechanism that develops at the narrow conduit between the cyst and dural sac and it may also play an important role in the enlargement of spinal extradural arachnoid cysts.^[9] They develop as a result of outpouching of the arachnoid layer, most commonly in the thoracic spine.

Symptoms vary according to the level of compression of the spinal cord or the nerve roots, and such cases generally present with remissions and exacerbations. Backache and leg weakness are the most common symptoms. Urinary incontinence, sexual disturbances, as well as numbness of legs may also be present.

Plain X-rays might show signs of the probable space of the occupying lesion. Computed tomography (CT) myelography usually shows a compressed thoracic cord displaced anteriorly. Importantly, CT myelography is essential to disclose the communication between the cyst and the subarachnoid space that is necessary for the accurate diagnosis.^[10] MRI, on the other hand, shows a nonenhancing extramedullary loculated cyst displacing the cord and nerve roots with signal intensity similar to CSF.^[11] Therefore, MRI may fail to demonstrate intradural arachnoid cysts unless the cord appears displaced and flattened.^[3,11,12]

Histopathological confirmation of the nature of the cell wall (arachnoid) is not always possible; hence, they are named meningeal cysts. Foci of calcification may be seen. The cyst contains clear fluid-like CSF. The grading system proposed by Nabors *et al.* includes 3 types: extradural cysts without spinal nerve root fibers (Type I), subdivided into extradural arachnoid cysts (Type IA) and sacral meningoceles (Type IB); extradural cysts with spinal nerve root fibers (Type II); and intradural cysts (Type III).^[13]

Treatment methods for arachnoid cysts include for asymptomatic patients, conservative treatment with observation is recommended.^[10] Whereas for symptomatic cases, complete excision of the cyst is recommended whenever possible to prevent reaccumulation of the cyst.^[2,3,9,14-16] Total excision by laminectomy followed by obliteration of the communicating pedicle and watertight repair of the dura defect is performed to achieve closure of the ball valve mechanism. Percutaneous cyst puncture using CT or MRI guidance was also done unfortunately the cyst readily reaccumulate following the cyst puncture.

Financial support and sponsorship

Nil.

Conflicts of interest

There are no conflicts of interest.

References

1. Cilluffo JM, Gomez MR, Reese DF, Onofrio BM, Miller RH. Idiopathic ("congenital") spinal arachnoid diverticula. Clinical diagnosis and surgical results. *Mayo Clin Proc* 1981;56:93-101.
2. Gortvai P. Extradural cysts of the spinal canal. *J Neurol Neurosurg Psychiatry* 1963;26:223-30.
3. Khosla A, Wippold FJ 2nd. CT myelography and MR imaging of extramedullary cysts of the spinal canal in adult and pediatric patients. *AJR Am J Roentgenol* 2002;178:201-7.
4. McCrum C, Williams B. Spinal extradural arachnoid pouches. Report of two cases. *J Neurosurg* 1982;57:849-52.
5. Myles LM, Gupta N, Armstrong D, Rutka JT. Multiple extradural arachnoid cysts as a cause of spinal cord compression in a child. Case report. *J Neurosurg* 1999;91:116-20.
6. Cloward RB. Congenital spinal extradural cysts: Case report with review of literature. *Ann Surg* 1968;168:851-64.
7. DiSclafani A 2nd, Canale DJ. Communicating spinal arachnoid cysts: Diagnosis by delayed metrizamide computed tomography. *Surg Neurol* 1985;23:428-30.
8. Cilluffo JM, Gomez MR, Reese DF, Onofrio BM, Miller RH. Idiopathic spinal arachnoid diverticula. *Mayo Clin Proc* 1981;56:93-101.
9. Rohrer DC, Burchiel KJ, Gruber DP. Intraspinous extradural meningeal cyst demonstrating ball-valve mechanism of formation. Case report. *J Neurosurg* 1993;78:122-5.
10. Rabb CH, McComb JG, Raffel C, Kennedy JG. Spinal arachnoid cysts in the pediatric age group: An association with neural tube defects. *J Neurosurg* 1992;77:369-72.
11. Sato K, Nagata K, Sugita Y. Spinal extradural meningeal cyst: Correct radiological and histopathological diagnosis. *Neurosurg Focus* 2002;13:eep1.
12. Bergland RM. Congenital intraspinal extradural cyst. Report of three cases in one family. *J Neurosurg* 1968;28:495-9.
13. Nabors MW, Pait TG, Byrd EB, Karim NO, Davis DO, Koblinski AI, *et al.* Updated assessment and current classification of spinal meningeal cysts. *J Neurosurg* 1988;68:366-77.
14. Spiegelmann R, Rappaport ZH, Sahar A. Spinal arachnoid cyst with unusual presentation. Case report. *J Neurosurg* 1984;60:613-6.
15. Stechison MT, Hendrick EB, Cohen E. Spinal extradural arachnoid cyst. *Pediatr Neurosci* 1989;15:36-8.
16. Chynn KY. Congenital spinal extradural cyst in two siblings. *Am J Roentgenol Radium Ther Nucl Med* 1967;101:204-15.