

Multiple Lesions Accompanied by Postoperative Spontaneous Intracystic Hemorrhage in a Pediatric Patient with Pilocytic Astrocytoma

Abstract

Pilocytic astrocytoma is the most common primary brain tumor in the pediatric population and has a classic imaging manifestation of a solitary, cyst-like mass with a strong contrast-enhancing mural nodule. Here, we report a case of multiple lesions in pilocytic astrocytoma in a pediatric patient accompanied by postoperative spontaneous intracystic hemorrhage. We describe the case of a 14-year-old female patient with a history of surgery for right cerebellar tumor 6 years ago. Computed tomography (CT) and magnetic resonance imaging showed cystic lesion with a mural nodule in the cerebellum and right retrothalamic area, suggesting a pilocytic astrocytoma. Emergency surgery was done. Pathology confirmed a pilocytic astrocytoma World Health Organization Grade 1. During postoperative course, clinical outcomes of the patient did not improve. Follow-up CT showed cystic remnant compressing the brain stem with spontaneous intracystic hemorrhage. The second surgery was done to evacuate the hemorrhage and to remove the cyst. Serial CT was made after the second surgery with no cyst growth nor hemorrhage present. Only three other pediatric multiple pilocytic astrocytomas have been reported previously, and there were only 11 publications about spontaneous intracystic hemorrhage in pediatric pilocytic astrocytoma. Our review of all previously reported cases found that the patients were predominantly male, and some had a history of neurofibromatosis type 1.

Keywords: Intracystic hemorrhage, intratumoral hemorrhage, multiple lesion, pediatric neurosurgery, pilocytic astrocytoma

Introduction

Pilocytic astrocytoma is categorized as World Health Organization (WHO) Grade I glioma.^[1] This tumor is a slow-growing neuroglioma, found among children and adolescents, usually located at the posterior cranial fossa, and has a classic imaging manifestation of a solitary, cyst-like mass with a strong contrast-enhancing mural nodule.^[2-5] Multiple pilocytic astrocytomas in a single patient is a less common manifestation.^[3,6] According to our knowledge, there has only been three publications on multiple involvement of pilocytic astrocytoma and 11 published articles on spontaneous intracystic hemorrhage in pediatric patients. In this article, we report the first documented case of multiple pilocytic astrocytoma accompanied by spontaneous intracystic hemorrhage.

Case Report

A 14-year-old female patient was admitted to our hospital with ataxia and postural imbalance. She also complained

of headache, vomiting, and right-sided hearing difficulty, occurring over a period of 1 month. No signs of neurofibromatosis type 1 (NF1) were found. She had a history of surgery for right cerebellar tumor and insertion of ventriculoperitoneal (VP) shunt 6 years ago. The pathology result was pilocytic astrocytoma WHO Grade 1.

She underwent computed tomography (CT) and magnetic resonance imaging (MRI) of the brain. Her CT showed hypodense lesion in the posterior cranial fossa with small hyperdense calcified lesion on the right border of the lesion, suggesting a cystic mass with a mural nodule. Another calcified lesion was also found in the right retrothalamic area. MRI showed a cystic lesion with a mural nodule in the cerebellum and right retrothalamic area, suggesting a pilocytic astrocytoma [Figure 1]. We planned for removal of the cerebellar mass. Meanwhile, the mural nodule in the right retrothalamic area was kept in observation.

This is an open access journal, and articles are distributed under the terms of the Creative Commons Attribution-NonCommercial-ShareAlike 4.0 License, which allows others to remix, tweak, and build upon the work non-commercially, as long as appropriate credit is given and the new creations are licensed under the identical terms.

For reprints contact: reprints@medknow.com

How to cite this article: Parenrengi MA, Aji YK. Multiple lesions accompanied by postoperative spontaneous intracystic hemorrhage in a pediatric patient with pilocytic astrocytoma. *Asian J Neurosurg* 2020;15:409-13.

Submitted: 10-Oct-2019 **Revised:** 30-Nov-2019
Accepted: 18-Mar-2020 **Published:** 29-May-2020

Muhammad Arifin Parenrengi, Yunus Kuntawi Aji¹

Department of Neurosurgery, Division of Pediatric Neurosurgery, Faculty of Medicine, Universitas Airlangga/Dr. Soetomo General Academic Hospital, ¹Department of Neurosurgery, Faculty of Medicine, Universitas Airlangga/Dr. Soetomo General Academic Hospital, Surabaya, Indonesia

Address for correspondence:

Dr. Yunus Kuntawi Aji, Department of Neurosurgery, Faculty of Medicine, Universitas Airlangga/Dr. Soetomo General Academic Hospital, Surabaya, Indonesia. E-mail: yunus.neurosurgery@gmail.com

Access this article online

Website: www.asianjns.org

DOI: 10.4103/ajns.AJNS_308_19

Quick Response Code:



Operative note

A midline posterior suboccipital craniotomy was performed under general anesthesia for tumor resection. The dura mater was opened to release the cerebrospinal fluid and expose the cerebellar hemisphere. The cystic and solid components of the tumor were removed completely. Postoperatively, the histopathological examination of the specimen was consistent with the previous result, suggesting a pilocytic astrocytoma WHO Grade 1.

Histological findings

The histopathological finding [Figure 2] showed a half-dense and half-loose (microcystic) tumor tissue arrangement which consisted of cell proliferation with oval-to-spindle nucleus and smooth chromatin. In the solid area, Rosenthal fibers were found with a mitotic rate of 0/10 high-power fields. This finding was consistent with pilocytic astrocytoma WHO Grade 1. No abnormal vascular structures were found.

Postoperative course

Early postoperative CT showed gross total removal of the tumor. Unfortunately, clinical outcomes of the patient did not improve after surgery. We then decided to perform

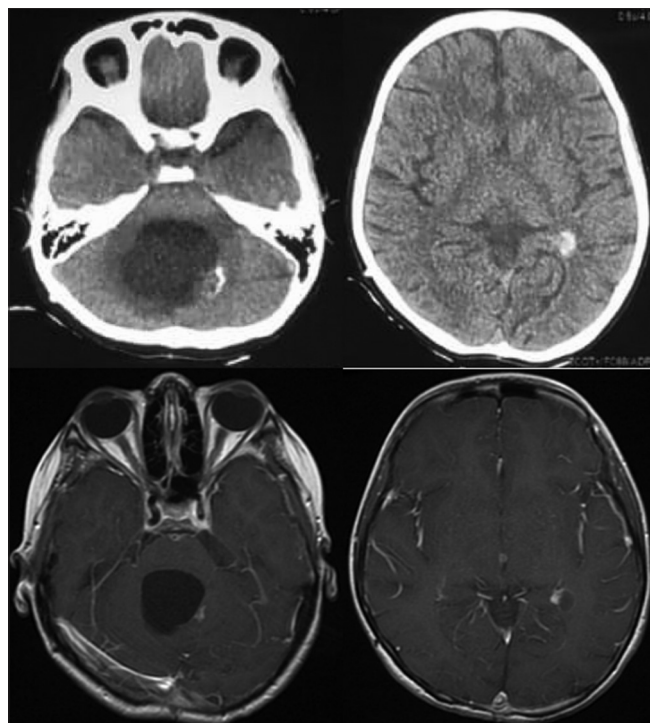


Figure 1: A 14-year-old female with a history of surgery for posterior cranial fossa mass 6 years ago. Axial computed tomography shows hypodense lesion in the posterior cranial fossa with hyperdense calcified lesion in the right border of the lesion, suggesting a cystic mass with a mural nodule (above, left). Another hyperdense calcified lesion also found in the right retrothalamal area (above, right). Axial postcontrast-enhanced T1-weighted images of the magnetic resonance imaging show a cystic lesion with a mural nodule in the cerebellum and right retrothalamal area, suggesting a pilocytic astrocytoma (below)

another CT on postoperative day 7, which showed a cystic remnant compressing the brain stem with spontaneous intracystic hemorrhage [Figure 3]. The posteroinferior side of the cystic remnant may be the source of hemorrhage. The second emergency surgery was performed to evacuate the hematomas and to remove the cyst. We put ventricular drain and connected its chamber to the fourth ventricle in case the cyst remained and grew again. If so, we planned to perform another surgery to put a Y-connector connecting this fourth ventricle shunt to the previous VP shunt in order to drain the cyst.

Early postoperative CT of the second surgery showed complete removal of the cyst and the hemorrhage. Clinical outcome of the patient improved after surgery. No cyst growth was present on serial postoperative CT 7 days later [Figure 4].

Discussion

Pilocytic astrocytoma is the most common primary brain tumor in pediatric population, comprising about 30% of all pediatric central nervous system tumors, 85% of all posterior fossa astrocytomas, and 10% of all cerebral astrocytomas in children.^[1,2,4,7,8] The cerebellum, the brainstem, the optic nerve and chiasm, and the thalamus/basal ganglia region are the most common locations of the lesion, with predilection within or near the midline sections.^[2,5,8,9] Signs and symptoms commonly found in cerebellar pilocytic astrocytoma include headache, neck pain, vomiting, ataxia, and diplopia.^[8,10] In the cerebellum, pilocytic astrocytoma has a typical neuroimaging presentation: expansive cystic mass with mural enhancing nodule.^[5] This typical imaging finding generally allows an easy preoperative diagnosis of pilocytic astrocytoma. Misdiagnosis is easier in other locations where the growth pattern and contrast enhancement can resemble more aggressive lesions.^[5]

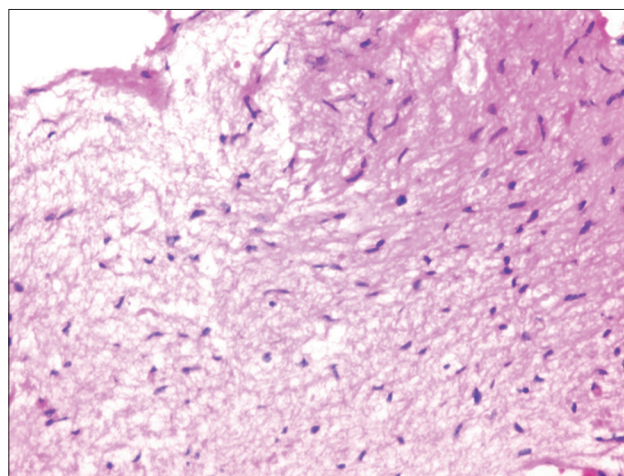


Figure 2: Photomicrograph showing the histopathological findings with features consistent with a diagnosis of World Health Organization Grade 1 pilocytic astrocytoma

Surgical resection is considered to be the treatment of choice and is considered curative if gross removals of the tumor are achieved.^[7,8,10] In most cases, no further chemotherapy or radiation therapy is required.^[7] The prognosis for patients with a pilocytic astrocytoma is excellent, with a 94% of 10-year survival rates and a 79% of 20-year survival rates.^[8]

Multiple involvement of pilocytic astrocytomas in children are rare.^[3] Most patients commonly present with NF1. Children with NF1 have an increased propensity to develop WHO Grade I and Grade II astrocytomas.^[9] However, reports regarding multiple types of pilocytic astrocytomas are lacking in literature.

Previously reported cases of multiple pilocytic astrocytomas in children are described in Table 1. All the cases presented were male. Headache, vomiting, and ataxia were the most common signs and symptoms. Two cases were related with NF1, whereas the other had a previous history of otitis media and prenatal hydrocephalus. All cases had lesion in the cerebellum, but only one case had an additional lesion in the periventricular area.

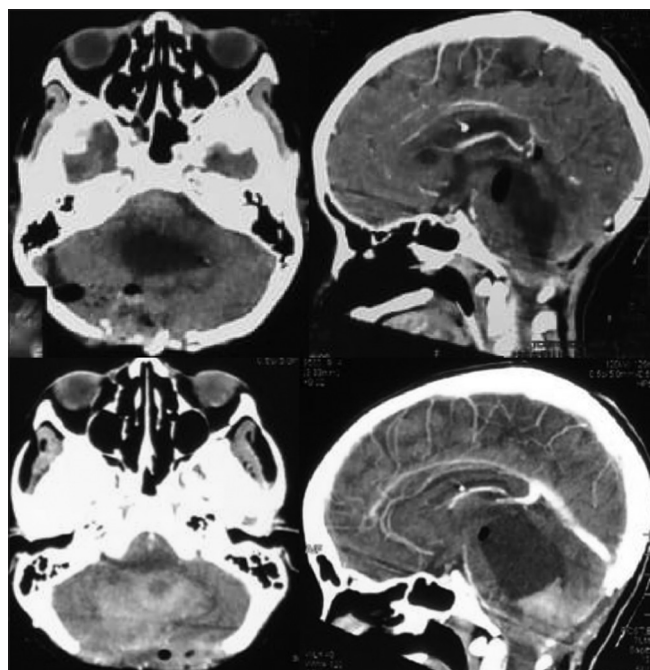


Figure 3: Early postoperative contrast-enhanced computed tomography reveals gross total removal of the tumor (above). Unfortunately, postoperative day 7 contrast-enhanced computed tomography shows a cystic remnant with intracystic hemorrhage (below)

There were 11 publications of 13 patients regarding intratumoral hemorrhage in pediatric pilocytic astrocytomas as described in Table 2. Most patients were male, and all tumors were located in the cerebellum. Headache was the prominent symptom, while one patient had a history of NF1. Cerebellar hemorrhages in pediatric population are rare and are mainly due to head injuries, rupture of vascular malformations, infections, or hematological diseases.^[21] Abnormal vascular structures such as glomeruloid blood vessels, ectasia, and vessel hyalinization were reported to influence hemorrhagic change.^[1] The hemorrhage might also be due to either blood vessels inherited from low-grade pilocytic astrocytoma component or factors associated with malignant transformation.^[1] Yet, the pathophysiology underlying intratumoral hemorrhage in pilocytic astrocytomas is unclear. Hemorrhagic pilocytic astrocytomas were more frequently reported in older population. The cause of hemorrhage in our case was thought to be the abnormal vascular structure component of the cystic remnant. Unfortunately, the histopathological finding did not show any of the abnormal vascular structures.

Our case is different from the previous ones. This case presented a female patient with no history of NF1. The locations of the lesions were the cerebellum and retrothalamic area. This case also presented with an episode of spontaneous intracystic hemorrhage during the postoperative period after gross total resection of the tumor was achieved. We believe this to be a rare case of pilocytic astrocytoma presenting in children.

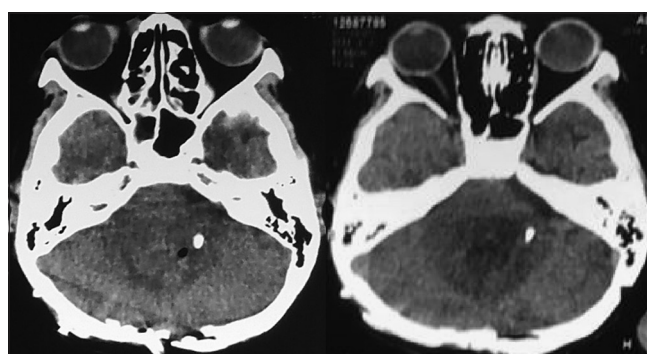


Figure 4: Early postoperative computed tomography of the second surgery shows complete removal of the cyst and the hemorrhage (left). Serial computed tomography was made 1 week later, no cyst nor hemorrhage was seen (right)

Table 1: Literature review of multiple pilocytic astrocytomas in pediatric patients

Publications	Age/gender	Signs and symptoms	Past history	Imaging	Location
Senaratna <i>et al.</i> , 2001 ^[4]	3/male	V, H, A, D	OM, PH	CT, MRI	PV, C
Dunn <i>et al.</i> , 2007 ^[6]	17/male	N, V, A	NF1	CT, MRI	C
Choi <i>et al.</i> , 2014 ^[3]	10/male	H	NF1	CT, MRI	C

N – Nausea; V – Vomiting; A – Ataxia; H – Headache; D – Drowsiness; OM – Otitis media; PH – Prenatal hydronephrosis; NF1 – Neurofibromatosis type 1; PV – Periventricular area; C – Cerebellum; CT – Computed tomography; MRI – Magnetic resonance imaging

Table 2: Literature review of cerebellar pilocytic astrocytomas with spontaneous intratumoral hemorrhage in pediatric patients

Publications	Age/gender	Signs and symptoms	Past history	Imaging	Location
Mauersberger <i>et al.</i> , 1977 ^[11]	10/female	H, V	-	CT	C
Mauersberger <i>et al.</i> , 1977 ^[11]	10/male	V, L	-	CT	C
Vincent <i>et al.</i> , 1980 ^[12]	14/female	-	-	CT	C
Fogelson <i>et al.</i> , 1980 ^[13]	9/male	-	-	CT	C
Specht <i>et al.</i> , 1986 ^[14]	8/male	H, L	-	CT	C
Mesiwala <i>et al.</i> , 2001 ^[15]	13/male	H, A	-	CT	C
Frassanito <i>et al.</i> , 2009 ^[16]	7/female	H, V, L, Mt	-	CT, MRI	C
Lee <i>et al.</i> , 2009 ^[17]	2/male	D, N, V	-	CT	C
Shibahara <i>et al.</i> , 2009 ^[18]	8/male	H, N, A	NF1	CT	C
Kumar <i>et al.</i> , 2010 ^[19]	16/female	H, A, B	-	MRI	C
Wilson <i>et al.</i> , 2016 ^[20]	12/male	H, V, N, A, L	-	CT	C
Wilson <i>et al.</i> , 2016 ^[20]	5/female	H, L	-	CT, MRI	C
Donofrio <i>et al.</i> , 2020 ^[21]	9/male	H, N, V	-	CT, MRI	C

N – Nausea; V – Vomiting; B – Blurring of vision; A – Ataxia; L – Loss of consciousness; Mt – Mutism; H – Headache; D – Drowsiness; NF1 – Neurofibromatosis type 1; C – Cerebellum; CT – Computed tomography; MRI – Magnetic resonance imaging

Conclusion

We report a surgically and pathologically proven case of pilocytic astrocytomas WHO grade 1, which comprised multiple nodules in the cerebellum and retrothalamic cistern area. Intracystic hemorrhage, as presented in this case, is one of the potential postoperative complications neurosurgeons should be aware of. Postoperative hemorrhage may be prevented by achieving gross total removal of the tumor, particularly in high-risk patients. Serial postoperative CT needs to be done whenever clinical outcomes did not improve even though gross total removal of the tumor has been achieved. Short- and long-term follow-up is important in maximizing outcomes in these complex patients.

Declaration of patient consent

The authors certify that they have obtained all appropriate patient consent forms. In the form the patient(s) has/have given his/her/their consent for his/her/their images and other clinical information to be reported in the journal. The patients understand that their names and initials will not be published and due efforts will be made to conceal their identity, but anonymity cannot be guaranteed.

Financial support and sponsorship

Nil.

Conflicts of interest

There are no conflicts of interest.

References

- Sangatsuda Y, Hata N, Suzuki SO, Akagi Y, Hatae R, Kuga D, *et al.* An elderly case of malignant small cell glioma with hemorrhage coexistent with a calcified pilocytic astrocytoma component in the cerebellar hemisphere. *Neuropathology* 2018;38:493-7.
- Sun S, Zhou H, Ding ZZ, Shi H. Cerebellar pilocytic

astrocytomas with spontaneous intratumoral hemorrhage in the elderly: A case report and review of the literature. *Medicine (Baltimore)* 2018;97:e11329.

- Choi SY, Kim MS, Kim YJ. Multiple solid pilocytic astrocytomas in cerebellum with neurofibromatosis type I: A case report. *J Korean Soc Radiol* 2014;70:83-6.
- Senaratna S, Hanieh A, Manson J, Toogood I. Multiple cystic brain lesions in a patient with pilocytic astrocytoma. *J Clin Neurosci* 2001;8:363-6.
- Gaudino S, Martucci M, Russo R, Visconti E, Gangemi E, D’Argento F, *et al.* MR imaging of brain pilocytic astrocytoma: Beyond the stereotype of benign astrocytoma. *Childs Nerv Syst* 2017;33:35-54.
- Dunn IF, Agarwalla PK, Papanastassiou AM, Butler WE, Smith ER. Multiple pilocytic astrocytomas of the cerebellum in a 17-year-old patient with neurofibromatosis type I. *Childs Nerv Syst* 2007;23:1191-4.
- Pletschko T, Felnhofer A, Lamplmair D, Dorfer C, Czech T, Chocholeous M, *et al.* Cerebellar pilocytic astrocytoma in childhood: Investigating the long-term impact of surgery on cognitive performance and functional outcome. *Dev Neurorehabil* 2018;21:415-22.
- Koeller KK, Rushing EJ. From the archives of the AFIP: Pilocytic astrocytoma: Radiologic-pathologic correlation. *Radiographics* 2004;24:1693-708.
- PDQ® Pediatric Treatment Editorial Board. PDQ Childhood Astrocytomas Treatment. Bethesda, MD: National Cancer Institute. Available from: <https://www.cancer.gov/types/brain/hp/child-astrocytoma-treatment-pdq>. [Last accessed on 2019 Mar 02, Last updated on 2018 Sep 09].
- Pencalet P, Maixner W, Sainte-Rose C, Lellouch-Tubiana A, Cinalli G, Zerah M, *et al.* Benign cerebellar astrocytomas in children. *J Neurosurg* 1999;90:265-73.
- Mauersberger W, Cuevas-Solórzano JA. Spontaneous intracerebellar hematoma during childhood caused by spongioblastoma of the IV ventricle. *Neuropadiatrie* 1977;8:443-50.
- Vincent FM, Bartone JR, Jones MZ. Cerebellar astrocytoma presenting as a cerebellar hemorrhage in a child. *Neurology* 1980;30:91-3.
- Fogelson MH, Oppenheim RE, McLaurin RL. Childhood

- cerebellar astrocytoma presenting with hemorrhage. *Neurology* 1980;30:669-70.
14. Specht CS, Pinto-Lord C, Smith TW, DeGirolami U, Suran E, Marshall PC, *et al.* Spontaneous hemorrhage in a mixed glioma of the cerebellum: Case report. *Neurosurgery* 1986;19:278-81.
 15. Mesiwala AH, Avellino AM, Roberts TS, Ellenbogen RG. Spontaneous cerebellar hemorrhage due to a juvenile pilocytic astrocytoma: Case report and review of the literature. *Pediatr Neurosurg* 2001;34:235-8.
 16. Frassanito P, Massimi L, Caldarelli M, Di Rocco C. Cerebellar mutism after spontaneous intratumoral bleeding involving the upper cerebellar vermis: A contribution to the physiopathogenic interpretation. *Childs Nerv Syst* 2009;25:7-11.
 17. Lee CS, Huh JS, Sim KB, Kim YW. Cerebellar pilocytic astrocytoma presenting with intratumor bleeding, subarachnoid hemorrhage, and subdural hematoma. *Childs Nerv Syst* 2009;25:125-8.
 18. Shibahara I, Kanamori M, Kumabe T, Endo H, Sonoda Y, Ogawa Y, *et al.* Hemorrhagic onset of pilocytic astrocytoma and pilomyxoid astrocytoma. *Brain Tumor Pathol* 2009;26:1-5.
 19. Kumar A, Deopujari CE, Biyani N, Mhatre MV. Pediatric cerebellar pilocytic astrocytoma presenting with hemorrhage. *Neurol India* 2010;58:972-4.
 20. Wilson MP, Johnson ES, Hawkins C, Atkins K, Alshaya W, Pugh JA. Hemorrhagic presentations of cerebellar pilocytic astrocytomas in children resulting in death: Report of 2 cases. *J Neurosurg Pediatr* 2016;17:446-52.
 21. Donofrio CA, Gagliardi F, Callea M, da Passano CF, Terreni MR, Cavalli A, *et al.* Pediatric cerebellar pilocytic astrocytoma presenting with spontaneous intratumoral hemorrhage. *Neurosurg Rev* 2020;43:9-16.