

Conservative Management of Chronic Subdural Hematoma with Tranexamic Acid

Sir,

Chronic subdural hematoma is an encapsulated collection of blood, usually occurs in the elderly, located between the dura and arachnoid and essentially characterized by the presence of a membrane. The computed tomography (CT) scan brain plain study is the imaging modality of choice for the diagnosis of this entity.^[1] Our patient is a 60-year-old male, developed headache of increasing intensity, nausea, and vomiting of 7 days of duration. At the time of examination in the emergency room, the patient was alert, oriented to person, place, and date and had right-sided hemiparesis. A CT scan of the brain showed a left frontoparietal chronic subdural hematoma [Figure 1a]. The patient blood investigations including coagulation profile was normal. In view of the smaller size of the lesion and the unwillingness to undergo surgical evacuation, the patient was managed conservatively with tranexamic acid (1 g every 8 h for 72 h) for 3 days. The patient was kept under observation in the hospital, received supportive care and physical therapy for 1 week. The patient did well during his stay in the hospital and was discharged on 7th day. At follow-up, the patient was asymptomatic, and there was total relief in his headache. Follow-up CT scan brain was performed 1 month after that showed total resolution of the chronic subdural hematoma [Figure 1b].

The management of chronic subdural hematoma ranges from observation alone to the use of drugs and different types of surgery (burr holes, craniotomy with or without excision of the membrane).^[2-4] Conservative treatment is based on the osmotic theory of formation and growth of

chronic subdural hematoma, by parenteral administration of hyperosmolar substances, which tend to reduce absorption, the volume of the hematoma.^[2-4] Tranexamic acid has been used as a medication to reduce bleeding events in various types of surgeries, and their effectiveness has been demonstrated. Its potential use in the management of chronic subdural hematoma has been reported rarely in the literature.^[5] It should be suspected especially in patients who present with dementia syndrome whether or older. Although less frequent, it should be investigated before a patient with the transient neurologic deficit. There is still no consensus regarding the ideal surgical modality. The procedure seems most recommended is closed suction drain drill holes. It has been debated whether intraoperative collection washing improves results. There is recent interest in the role of tranexamic acid as a conservative treatment for chronic subdural hematoma.^[1]

Financial support and sponsorship

Nil.

Conflicts of interest

There are no conflicts of interest.

**Luis Rafael Moscote-Salazar,
Guru Dutta Satyarthee¹,
Jorge Aquino Matus², Johana Maraby³,
Willem Guillermo Calderon Miranda⁴**

Department of Neurosurgery-Critical Care, Red Latino, Latin American Trauma and Intensive Neuro-Care Organization, Bogota, ³Department of Medicine, Universidad de Cartagena, Cartagena de Indias, Colombia, ¹Department of Neurosurgery, All India Institute of Medical Sciences, New Delhi, India, Departments of ²Internal Medicine and ⁴Radiology, National Autonomous University of Mexico, Ciudad de Mexico, Mexico

Address for correspondence:

*Dr. Luis Rafael Moscote-Salazar,
Department of Neurosurgeon-Critical Care, RED LATINO Organización Latinoamericana de Traumay Cuidado Neurointensivo, Bogota, Colombia
E-mail: mineurocirujano@aol.com*

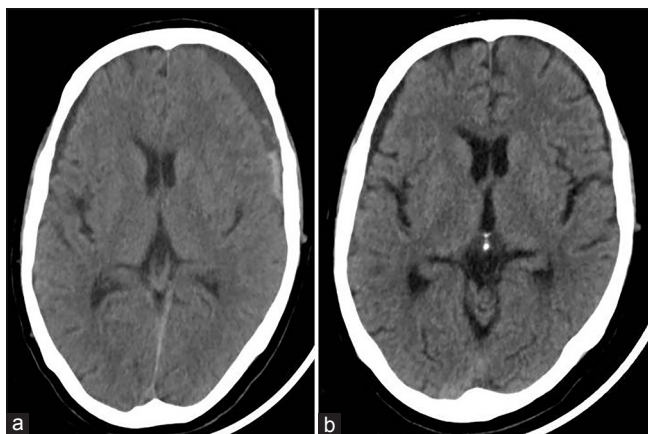


Figure 1: (a and b) Computed tomography brain showing a chronic subdural hematoma and computed tomography control 30 days after treatment with tranexamic acid

References

- Dunn CJ, Goa KL. Tranexamic acid: A Review of its use in surgery and other indications. *Drugs* 1999;57:1005-32.
- Chen JC, Levy ML. Causes, epidemiology, and risk factors of chronic subdural hematoma. *Neurosurg Clin N Am* 2000;11:399-406.
- Dumont TM, Rughani AI, Goeckes T, Tranmer BI. Chronic subdural hematoma: A sentinel health event. *World Neurosurg* 2013;80:889-92.
- Kageyama H, Toyooka T, Tsuzuki N, Oka K. Nonsurgical

treatment of chronic subdural hematoma with tranexamic acid. J Neurosurg 2013;119:332-7.

5. Bansal H, Mahajan A, Singh A, Chaudhary A. Spontaneous disappearance of a large chronic subdural hematoma: A pleasant surprise. Indian J Surg 2015;77:532-4.

This is an open access journal, and articles are distributed under the terms of the Creative Commons Attribution-NonCommercial-ShareAlike 4.0 License, which allows others to remix, tweak, and build upon the work non-commercially, as long as appropriate credit is given and the new creations are licensed under the identical terms.

Access this article online	
Quick Response Code: 	Website: www.asianjns.org
	DOI: 10.4103/ajns.AJNS_298_16

How to cite this article: Moscote-Salazar LR, Satyarthee GD, Matus JA, Maraby J, Calderon Miranda WG. Conservative management of chronic subdural hematoma with tranexamic acid. Asian J Neurosurg 2018;13:951-2.

© 2018 Asian Journal of Neurosurgery | Published by Wolters Kluwer - Medknow