

# The Ethical Dilemma in the Surgical Management of Low Grade Gliomas According to the Variable Availability of Resources and Surgeon Experience

## Abstract

Low grade gliomas (LGGs) affect young individuals in the prime of life. Management may alternatively include biopsy and observation or surgical resection. Recent evidence strongly favors maximal and supramaximal resection of LGGs in optimizing survival metrics. Awake craniotomy with cortical mapping and electrical stimulation along with other preoperative and intraoperative surgical adjuncts, including intraoperative magnetic resonance and diffusion tensor imaging, facilitates maximization of resection and eschews precipitating neurological deficits. Intraoperative imaging permits additional resection of identified residual to be completed within the same surgical session, improving extent of resection and consequently progression free and overall survival. These resources are available in only a few centers throughout the United States, raising an ethical dilemma as to where patients harboring LGGs should most appropriately be treated.

**Keywords:** Gliomas, intraoperative, magnetic resonance imaging, neuronavigation, supratotal resection, surgeon experience, survival, technology

## Introduction

Approximately 1600 cases of low grade gliomas (LGGs) are diagnosed annually in the pediatric population and 5000 cases in adults.<sup>[1,2]</sup> The natural history of LGG follows a course that is ultimately fatal with mean age at diagnosis of approximately 41 years.<sup>[3]</sup> This age is often the most productive part of life, often with a spouse and children involved. Therefore, treatment decisions are extremely important, since outcomes critically impact on the patient's quality of life<sup>[4-6]</sup> and poor decisions could putatively have significant ramifications to the individual and family. We will thus perform a thorough review of the literature in order to evaluate the argument that patients harboring LGGs should receive multidisciplinary treatment at centers capable of providing all the surgical adjunctive resources facilitating preoperative and intraoperative determination of tumor structure properties,<sup>[7-19]</sup> relationship to eloquent cortical structures<sup>[20-23]</sup> and white matter tracts,<sup>[24-27]</sup> and completeness of extirpation, in order to safely maximize the extent of resection.<sup>[6,28-44]</sup> If this is true, it

should pose an ethical dilemma regarding where, and by which surgeon, the operation is most appropriately performed.<sup>[45]</sup>

## Supratotal and Maximal Safe Resection of Low Grade Gliomas

The optimal treatment of LGGs remains controversial and the most appropriate management of these tumors is not entirely clear, though a plethora of studies have made significant strides and efforts in order to precisely elucidate ideal therapeutic strategies.<sup>[1,2,5,25,29,31-34,36,38,40,41,43,46-58]</sup> For symptomatic LGGs in noneloquent parenchyma, there is general agreement that an aggressive resection proves ideal,<sup>[4,6,28,35,37,38,41,43,44]</sup> but for lesions that are asymptomatic, slow-growing, and/or located in eloquent cortex, the optimal management strategy remains disputed, with conservative<sup>[58]</sup> or surgical therapy<sup>[1,4,5,45,47,49]</sup> alternatively appropriate. Multiple therapeutic paradigms exist in order to effectively manage these lesions,<sup>[47]</sup> including observation (clinical and imaging

**Marshall Norman Lahiff<sup>1,2</sup>,  
Michael George Zaki Ghali<sup>3,4</sup>**

<sup>1</sup>School of Law, University of Miami, <sup>2</sup>Walton Lantaff Schoreder and Carson LLP, Miami, Florida, <sup>3</sup>Department of Neurological Surgery, Houston Methodist Hospital, Houston, Texas, <sup>4</sup>Department of Neurobiology and Anatomy, Drexel University College of Medicine, Philadelphia, Pennsylvania, USA

### Address for correspondence:

Prof. Michael George Zaki Ghali,  
Department of Neurosurgery  
Surgery, Houston Methodist  
Hospital, 6560 Fannin Street,  
Houston, TX 77030, USA.  
E-mail: mgzghali@gmail.com

### Access this article online

Website: [www.asianjns.org](http://www.asianjns.org)

DOI: 10.4103/ajns.AJNS\_296\_19

### Quick Response Code:



This is an open access journal, and articles are distributed under the terms of the Creative Commons Attribution-NonCommercial-ShareAlike 4.0 License, which allows others to remix, tweak, and build upon the work non-commercially, as long as appropriate credit is given and the new creations are licensed under the identical terms.

For reprints contact: [reprints@medknow.com](mailto:reprints@medknow.com)

**How to cite this article:** Lahiff MN, Ghali MG. The ethical dilemma in the surgical management of low grade gliomas according to the variable availability of resources and surgeon experience. *Asian J Neurosurg* 2020;15:266-71.

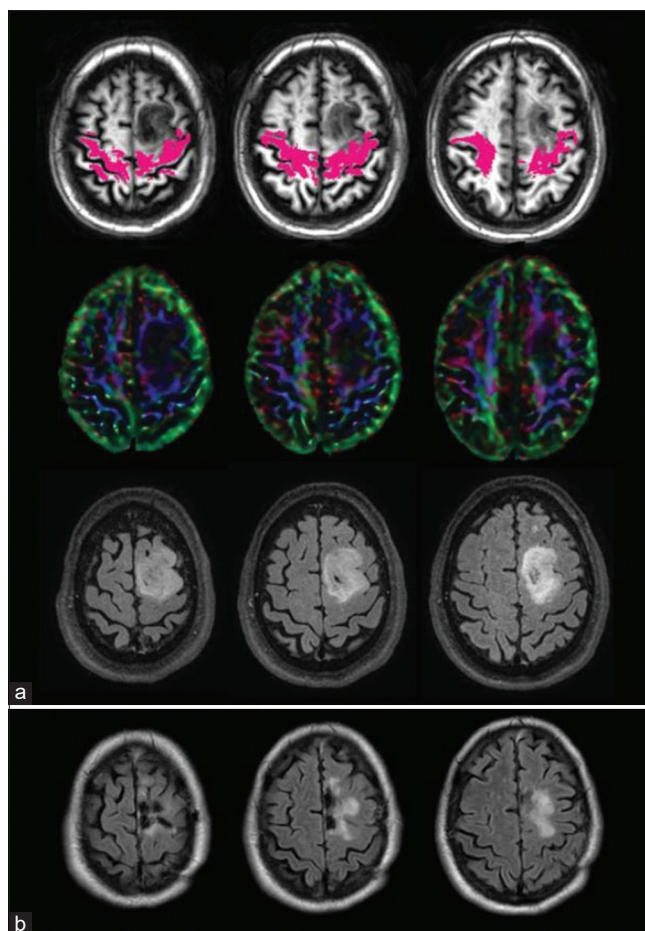
Submitted: 26-Sep-2019 Accepted: 20-Dec-2019  
Published: 29-May-2020

surveillance) alone,<sup>[59]</sup> biopsy and observation, biopsy and radiotherapy, extirpation resection<sup>[60]</sup> without or with neoadjuvant chemotherapy (e.g., temozolomide)<sup>[29,38]</sup> followed by observation, surgical resection followed by radiotherapy,<sup>[52]</sup> and laser interstitial thermal therapy.<sup>[56,61]</sup>

While earlier studies had supported observation as an equally viable alternative to surgical resection,<sup>[59]</sup> a subsequent study carried out in Norway demonstrated significantly greater 5 year overall survival (74%) in patients with diffuse LGG following resection compared to observation (60%).<sup>[60]</sup> Moreover, recent evidence suggests upfront maximal safe resection (MSR) not only alters the natural history of the disease, but also additionally improves overall survival and malignant progression-free survival, as well as seizure control.<sup>[4,30,35,41,44,60,61-64]</sup> Furthermore, authors have described supratotal resection, whereby maximal resection is extended to include a rim of radiographically and grossly normal tissue, a strategy having become an attractive concept well demonstrated to improve outcomes.<sup>[4,6,44]</sup>

### Surgical Resources Maximizing the Resection of Low Grade Gliomas

Based on the aforementioned studies, and if the recent data are correct, a maximal/gross total or supratotal resection should be the goal in patients with LGGs in order to optimize clinical outcomes.<sup>[4,6,28,35,37,38,41,43,44]</sup> The natural history of LGGs may be significantly improved with a more aggressive or even a supratotal resection.<sup>[4,6,44]</sup> An oncofunctional balance must be made, wherein eloquent parenchyma is preserved in order to prevent deficits,<sup>[39,65]</sup> while achieving a maximal resection in order to improve overall survival.<sup>[6]</sup> In order to reliably obtain these goals safely, especially in regions adjacent to eloquent cortex, use of numerous preoperative and intra-operative modalities proves requisite (Tovar Spinoza *et al.*, 2016).<sup>[4-6,39,44,61]</sup> Preoperative resources include functional magnetic resonance imaging (MRI) to evaluate functional cortex,<sup>[20-23]</sup> WADA testing to evaluate speech dominance, and diffusion tensor imaging and fiber tractography in order to accurately locate deep fiber tracts [Figure 1].<sup>[24-27]</sup> The intraoperative adjunct armamentarium includes neuronavigation,<sup>[21,66]</sup> awake craniotomy with intraoperative cortical and subcortical mapping,<sup>[8,10,11,14,15,23,67]</sup> intraoperative tumor staining dyes (e.g., 5-delta-aminolevulinic acid) to delineate tumor from normal brain,<sup>[68-71]</sup> and intraoperative MRI to detect tumor residual following initial resection,<sup>[7-19]</sup> all of which prove useful alone or in combination to facilitate MSR of diffuse low grade and high grade gliomas.<sup>[4,6,32-34,39,44]</sup> Additionally and indispensably, the surgeon's experience operatively and with the foregoing modalities is highly variable and arguably critical in determining the degree of MSR achievable and optimizing patient outcomes, a general principle in



**Figure 1:** Diffusion tensor tractography of a patient with left frontal oligodendroglioma. (a) The tumor infiltrates the left corticospinal tract (magenta) throughout its precentral gyral and centrum semiovale extents. Upper panel: Axial T1 weighted magnetic resonance imaging (MRI) sequences demonstrate left frontal oligodendroglioma. The location of the corticospinal spinal tracts (magenta) is determined by diffusion tensor tractography and superimposed on the axial T1 weighted MRI. Middle panels: Color maps demonstrate decreases in fractional anisotropy resulting from left frontal oligodendroglioma. Lower panels: Axial fluid attenuated inversion recovery MRI sequences indicate the location of the left frontal oligodendroglioma. Volumetric analysis determines the oligodendroglioma occupies a space of 29 cm<sup>3</sup>. (b) Axial fluid attenuated inversion recovery magnetic resonance imaging sequences performed postoperatively evidence residual within the area of deep fascicular infiltration. Corticospinal tract involvement precludes safely achieving a supratotal resection and predicts worse outcomes following operative intervention. Modified with permission from Figure 1 of Castellano *et al.*<sup>[27]</sup>

neurological<sup>[69-71]</sup> and general<sup>[75-79]</sup> surgery. Critically, this may bear significant medicolegal implications as well, since surgeon inexperience accounts for approximately 40%–60% of factors contributing to medical error, resulting in malpractice cases.<sup>[80,81]</sup>

### Surgeon Experience and Patient Outcomes

The importance of surgeon experience on survival and functional outcomes cannot be overemphasized. Improved outcomes for complex surgical problems are consistently correlated with surgeon experience and hospital volume in both neurological<sup>[45,72,73]</sup> as well as general<sup>[75-79]</sup> surgery, especially for more complex and challenging

pathologies.<sup>[74,82]</sup> For instance, greater surgeon experience correlates with reduced mortality in laparoscopic major hepatectomies,<sup>[83]</sup> reduced postoperative complications and mortality following laparoscopic colorectal operative intervention,<sup>[84]</sup> enhanced recovery of urinary continence following robotic-assisted radical prostatectomy,<sup>[85]</sup> higher endocrinological cure rates for transsphenoidal resection of pituitary adenoma,<sup>[74]</sup> reduced postoperative corneal edema following cataract surgery,<sup>[86]</sup> reduced postoperative mortality following pancreaticoduodenectomy,<sup>[82]</sup> reduced postoperative complications following laparoscopic cholecystectomy,<sup>[87]</sup> and fewer complications following shoulder arthroplasty and hemiarthroplasty.<sup>[88]</sup>

## Conclusions

Neurosurgical outcomes obtained in the treatment of low grade gliomas are significantly facilitated by the use of awake craniotomy with cortical stimulation mapping, neuronavigation guided craniotomy, surgical approach, and microsurgical tumor removal, diffusion tensor imaging to identify the relationship of eloquent white matter tracts with respect to the tumor, intraoperative magnetic resonance imaging to guide tumor resection and determine extent of resection prior to closure of craniotomy, and d-aminolevulinic acid staining to distinguish between tumor tissue and normal cerebral parenchyma (Duffau, 2017, 2018, 2019; de Leeuw and Vogelbaum, 2019; Dimou *et al.*, 2019; D'Souza *et al.*, 2019).<sup>[89-95]</sup> Since diffuse LGGs bear fatal consequences which can be facily delayed with optimal and ideal treatment, an ethical dilemma becomes clearly evident. This dilemma is present in the United States of America and throughout the world.<sup>[28]</sup> Despite the extensive evidence arguing in favor of, and supporting, more aggressive and earlier resection in order to improve outcomes, LGGs are treated at a variety of facilities across the world and the United States of America without these operative resources or surgeon experience to optimize the ultimate outcome for the patient due to limited availability. In third world nations with facilities lacking all, or the majority, of these resources, it may be ethical to operate on LGGs when the differential outcome may otherwise be fatal to this young population. However, in the United States of America, which spends close to 18% of its gross domestic product on healthcare, with amply equipped facilities and experienced surgeons readily available nationally, a dilemma arises as to whether it is ethical to operate on these lesions without the aid and benefit of these resources. Further studies rigorously evaluating the survival advantage conferred by the use of each of these surgical adjuncts and resources will critically inform this heated debate.

## Financial support and sponsorship

Nil.

## Conflicts of interest

There are no conflicts of interest.

## References

1. McKhann GM, Duffau H. Low-grade glioma: Epidemiology, pathophysiology, clinical features, and treatment. *Neurosurg Clin N Am* 2019;30:xiii-xiv.
2. Diwanji TP, Engelman A, Snider JW, Mohindra P. Epidemiology, diagnosis, and optimal management of glioma in adolescents and young adults. *Adolesc Health Med Ther* 2017;8:99-113.
3. Claus EB, Walsh KM, Wiencke JK, Molinaro AM, Wiemels JL, Schildkraut JM, *et al.* Survival and low-grade glioma: The emergence of genetic information. *Neurosurg Focus* 2015;38:E6.
4. Duffau H. Long-term outcomes after supratotal resection of diffuse low-grade gliomas: A consecutive series with 11-year follow-up. *Acta Neurochir (Wien)* 2016;158:51-8.
5. Duffau H. Awake mapping is not an additional surgical technique but an alternative philosophy in the management of low-grade glioma patients. *Neurosurg Rev* 2018;41:689-91.
6. Lima GL, Dezamis E, Corns R, Rigaux-Viode O, Moritz-Gasser S, Roux A, *et al.* Surgical resection of incidental diffuse gliomas involving eloquent brain areas. Rationale, functional, epileptological and oncological outcomes. *Neurochirurgie* 2017;63:250-8.
7. Incekara F, Olubiya O, Ozdemir A, Lee T, Rigolo L, Golby A. The value of pre- and intraoperative adjuncts on the extent of resection of hemispheric low-grade gliomas: A retrospective analysis. *J Neurol Surg A Cent Eur Neurosurg* 2016;77:79-87.
8. Leuthardt EC, Lim CC, Shah MN, Evans JA, Rich KM, Dacey RG, *et al.* Use of movable high-field-strength intraoperative magnetic resonance imaging with awake craniotomies for resection of gliomas: Preliminary experience. *Neurosurgery* 2011;69:194-205.
9. Lu J, Wu J, Yao C, Zhuang D, Qiu T, Hu X, *et al.* Awake language mapping and 3-Tesla intraoperative MRI-guided volumetric resection for gliomas in language areas. *J Clin Neurosci* 2013;20:1280-7.
10. Nabavi A, Goebel S, Doerner L, Warneke N, Ulmer S, Mehdorn M. Awake craniotomy and intraoperative magnetic resonance imaging: Patient selection, preparation, and technique. *Top Magn Reson Imaging* 2009;19:191-6.
11. Tuominen J, Yrjänä S, Ukkonen A, Koivukangas J. Awake craniotomy may further improve neurological outcome of intraoperative MRI-guided brain tumor surgery. *Acta Neurochir (Wien)* 2013;155:1805-12.
12. Weingarten DM, Asthagiri AR, Butman JA, Sato S, Wiggs EA, Damaska B, *et al.* Cortical mapping and frameless stereotactic navigation in the high-field intraoperative magnetic resonance imaging suite. *J Neurosurg* 2009;111:1185-90.
13. Goebel S, Nabavi A, Schubert S, Mehdorn HM. Patient perception of combined awake brain tumor surgery and intraoperative 1.5-T magnetic resonance imaging: The Kiel experience. *Neurosurgery* 2010;67:594-600.
14. Parney IF, Goerss SJ, McGee K, Huston J 3<sup>rd</sup>, Perkins WJ, Meyer FB. Awake craniotomy, electrophysiologic mapping, and tumor resection with high-field intraoperative MRI. *World Neurosurg* 2010;73:547-51.
15. Maldaun MV, Khawja SN, Levine NB, Rao G, Lang FF, Weinberg JS, *et al.* Awake craniotomy for gliomas in a high-field intraoperative magnetic resonance imaging suite: Analysis of 42 cases. *J Neurosurg* 2014;121:810-7.
16. Choudhri AF, Klimo P Jr, Auschwitz TS, Whitehead MT, Boop FA. 3T intraoperative MRI for management of pediatric CNS neoplasms. *AJNR Am J Neuroradiol* 2014;35:2382-7.
17. Roder C, Breitkopf M, Ms, Bisdas S, Freitas Rda S, Dimostheni A, *et al.* Beneficial impact of high-field intraoperative



- magnetic resonance imaging on the efficacy of pediatric low-grade glioma surgery. *Neurosurg Focus* 2016;40:E13.
18. Ghinda D, Zhang N, Lu J, Yao CJ, Yuan S, Wu JS. Contribution of combined intraoperative electrophysiological investigation with 3-T intraoperative MRI for awake cerebral glioma surgery: Comprehensive review of the clinical implications and radiological outcomes. *Neurosurg Focus* 2016;40:E14.
  19. Claus EB, Horlacher A, Hsu L, Schwartz RB, Dello-Iacono D, Talos F, *et al.* Survival rates in patients with low-grade glioma after intraoperative magnetic resonance image guidance. *Cancer* 2005;103:1227-33.
  20. Izutsu N, Kinoshita M, Yanagisawa T, Nakanishi K, Sakai M, Kishima H. Preservation of motor function after resection of lower-grade glioma at the precentral gyrus and prediction by presurgical functional magnetic resonance imaging and magnetoencephalography. *World Neurosurg* 2017;107:1045:e5-8.
  21. Berntsen EM, Gulati S, Solheim O, Kvistad KA, Torp SH, Selbekk T, *et al.* Functional magnetic resonance imaging and diffusion tensor tractography incorporated into an intraoperative 3-dimensional ultrasound-based neuronavigation system: Impact on therapeutic strategies, extent of resection, and clinical outcome. *Neurosurgery* 2010;67:251-64.
  22. Kumar A, Chandra PS, Sharma BS, Garg A, Rath GK, Bithal PK, *et al.* The role of neuronavigation-guided functional MRI and diffusion tensor tractography along with cortical stimulation in patients with eloquent cortex lesions. *Br J Neurosurg* 2014;28:226-33.
  23. Lu JF, Zhang H, Wu JS, Yao CJ, Zhuang DX, Qiu TM, *et al.* "Awake" intraoperative functional MRI (ai-fMRI) for mapping the eloquent cortex: Is it possible in awake craniotomy? *Neuroimage Clin* 2012;2:132-42.
  24. Bello L, Castellano A, Fava E, Casaceli G, Riva M, Scotti G, *et al.* Intraoperative use of diffusion tensor imaging fiber tractography and subcortical mapping for resection of gliomas: Technical considerations. *Neurosurg Focus* 2010;28:E6.
  25. Darlix A, Mandonnet E, Freyschlag CF, Pinggera D, Forster MT, Voss M, *et al.* Chemotherapy and diffuse low-grade gliomas: A survey within the European Low-Grade Glioma Network. *Neurooncol Pract* 2019;6:264-73.
  26. Yan JL, van der Hoorn A, Larkin TJ, Boonzaier NR, Matys T, Price SJ. Extent of resection of peritumoral diffusion tensor imaging-detected abnormality as a predictor of survival in adult glioblastoma patients. *J Neurosurg* 2017;126:234-41.
  27. Castellano A, Bello L, Michelozzi C, Gallucci M, Fava E, Iadanza A, *et al.* Role of diffusion tensor magnetic resonance tractography in predicting the extent of resection in glioma surgery. *Neuro Oncol* 2012;14:192-202.
  28. Mirza AF, Shamim MS. Extent of resection and timing of surgery in adult low grade glioma. *J Pak Med Assoc* 2017;67:959-61.
  29. Al-Tamimi YZ, Palin MS, Patankar T, MacMullen-Price J, O'Hara DJ, Loughrey C, *et al.* Low-grade glioma with foci of early transformation does not necessarily require adjuvant therapy after radical surgical resection. *World Neurosurg* 2018;110:e346-54.
  30. Chang EF, Potts MB, Keles GE, Lamborn KR, Chang SM, Barbaro NM, *et al.* Seizure characteristics and control following resection in 332 patients with low-grade gliomas. *J Neurosurg* 2008;108:227-35.
  31. Corrivetti F, Herbet G, Moritz-Gasser S, Duffau H. Prosopagnosia induced by a left anterior temporal lobectomy following a right temporo-occipital resection in a multicentric diffuse low-grade glioma. *World Neurosurg* 2017;97:756.e1-5.
  32. Duffau H. Is non-awake surgery for supratentorial adult low-grade glioma treatment still feasible? *Neurosurg Rev* 2018a;41:133-9.
  33. Duffau H. Paradoxes of evidence-based medicine in lower-grade glioma: To treat the tumor or the patient? *Neurology* 2018b;91:657-62.
  34. Duffau H. Diffuse low-grade glioma, oncological outcome and quality of life: A surgical perspective. *Curr Opin Oncol* 2018c;30:383-9.
  35. Englot DJ, Han SJ, Berger MS, Barbaro NM, Chang EF. Extent of surgical resection predicts seizure freedom in low-grade temporal lobe brain tumors. *Neurosurgery* 2012;70:921-8.
  36. Hendriks EJ, Idema S, Hervey-Jumper SL, Bernat AL, Zwinderman AH, Barkhof F, *et al.* Preoperative resectability estimates of nonenhancing glioma by neurosurgeons and a resection probability map. *Neurosurgery* 2019;85:E304-13.
  37. Jakola AS, Myrmet KS, Kloster R, Torp SH, Lindal S, Unsgård G, *et al.* Comparison of a strategy favoring early surgical resection vs. a strategy favoring watchful waiting in low-grade gliomas. *JAMA* 2012;308:1881-8.
  38. Jo J, Williams B, Smolkin M, Wintermark M, Shaffrey ME, Lopes MB, *et al.* Effect of neoadjuvant temozolomide upon volume reduction and resection of diffuse low-grade glioma. *J Neurooncol* 2014;120:155-61.
  39. McGirt MJ, Chaichana KL, Attenello FJ, Weingart JD, Than K, Burger PC, *et al.* Extent of surgical resection is independently associated with survival in patients with hemispheric infiltrating lowgrade gliomas. *Neurosurgery* 2008;63:700-7.
  40. Picart T, Herbet G, Moritz-Gasser S, Duffau H. Iterative Surgical Resections of Diffuse Glioma With Awake Mapping: How to Deal With Cortical Plasticity and Connectomal Constraints? *Neurosurgery* 2019;85:105-16.
  41. Picart T, Duffau H. Awake resection of a left operculo-insular low-grade glioma guided by cortico-subcortical mapping. *Neurosurg Focus* 2018;45:V1.
  42. Smith JS, Chang EF, Lamborn KR, Chang SM, Prados MD, Cha S, *et al.* Role of extent of resection in the long-term outcome of low-grade hemispheric gliomas. *J Clin Oncol* 2008;26:1338-45.
  43. Still ME, Roux A, Huberfeld G, Bauchet L, Baron MH, Fontaine D, *et al.* Extent of resection and residual tumor thresholds for postoperative total seizure freedom in epileptic adult patients harboring a supratentorial diffuse low-grade glioma. *Neurosurgery* 2019;85:E332-40.
  44. Yordanova YN, Moritz-Gasser S, Duffau H. Awake surgery for WHO Grade II gliomas within "noneloquent" areas in the left dominant hemisphere: Toward a "supratotal" resection. *Clinical article. J Neurosurg* 2011;115:232-9.
  45. Best B, Nguyen HS, Doan NB, Gelsomino M, Shabani S, Ahmadi Jazi G, *et al.* Gliomas: Survival differences between metropolitan and non-metropolitan counties. *J Neurosurg Sci* 2019;63:114-120.
  46. Almairac F, Duffau H, Herbet G. Contralateral macrostructural plasticity of the insular cortex in patients with glioma: A VBM study. *Neurology* 2018;91:e1902-8.
  47. Vanacôr C, Duffau H. Analysis of legal, cultural, and socioeconomic parameters in low-grade glioma management: Variability across countries and implications for awake surgery. *World Neurosurg* 2018;120:47-53.
  48. Coget A, Deverdun J, Bonafé A, van Dokkum L, Duffau H, Molino F, *et al.* Transient immediate postoperative homotopic functional disconnectivity in low-grade glioma patients. *Neuroimage Clin* 2018;18:656-62.

49. Mandonnet E, Duffau H. An attempt to conceptualize the individual onco-functional balance: Why a standardized treatment is an illusion for diffuse low-grade glioma patients. *Crit Rev Oncol Hematol* 2018;122:83-91.
50. Peeters S, Pagès M, Gauchotte G, Miquel C, Cartalat-Carel S, Guillamo JS, *et al.* Interactions between glioma and pregnancy: Insight from a 52-case multicenter series. *J Neurosurg* 2018;128:3-13.
51. Oberheim Bush NA, Chang S. Treatment Strategies for Low-Grade Glioma in Adults. *J Oncol Pract* 2016;12:1235-41.
52. Tovar-Spinoza Z, Choi H. MRI-guided laser interstitial thermal therapy for the treatment of low-grade gliomas in children: A case-series review, description of the current technologies and perspectives. *Childs Nerv Syst* 2016;32:1947-56.
53. Kaya V, Aksu MG, Korcum AF, Ozdemir B, Ceçen Y, Sindir B, *et al.* Clinical prognostic factors of adjuvant radiation therapy for low-grade gliomas: Results of 10 years survival. *Int J Clin Exp Med* 2014;7:1336-43.
54. Hurwitz MD. Today's thermal therapy: Not your father's hyperthermia: Challenges and opportunities in application of hyperthermia for the 21<sup>st</sup> century cancer patient. *Am J Clin Oncol* 2010;33:96-100.
55. Schwarzmaier HJ, Eickmeyer F, von Tempelhoff W, Fiedler VU, Niehoff H, Ulrich SD, *et al.* MR-guided laser-induced interstitial thermotherapy of recurrent glioblastoma multiforme: Preliminary results in 16 patients. *Eur J Radiol* 2006;59:208-15.
56. Sloan AE, Ahluwalia MS, Valerio-Pascua J, Manjila S, Torchia MG, Jones SE, *et al.* Results of the NeuroBlate System first-in-humans Phase I clinical trial for recurrent glioblastoma: Clinical article. *J Neurosurg* 2013;118:1202-19.
57. Mohammadi AM, Hawasli AH, Rodriguez A, Schroeder JL, Laxton AW, Elson P, *et al.* The role of laser interstitial thermal therapy in enhancing progression-free survival of difficult-to-access high-grade gliomas: A multicenter study. *Cancer Med* 2014;3:971-9.
58. Carpentier A, Chauvet D, Reina V, Beccaria K, Leclercq D, McNichols RJ, *et al.* MR-guided laser-induced thermal therapy (LITT) for recurrent glioblastomas. *Lasers Surg Med* 2012;44:361-8.
59. Reijneveld JC, Sitskoorn MM, Klein M, Nuyen J, Taphoorn MJ. Cognitive status and quality of life in patients with suspected versus proven low-grade gliomas. *Neurology* 2001;56:618-23.
60. Jakola AS, Skjulsvik AJ, Myrnes KS, Sjøvik K, Unsgård G, Torp SH, *et al.* Surgical resection versus watchful waiting in low-grade gliomas. *Ann Oncol* 2017;28:1942-8.
61. Tovar-Spinoza Z, Choi H. MRI-guided laser interstitial thermal therapy for the treatment of low-grade gliomas in children: A case-series review, description of the current technologies and perspectives. *Childs Nerv Syst* 2016;32:1947-56.
62. Roelz R, Strohmaier D, Jabbarli R, Kraeutle R, Egger K, Coenen VA, *et al.* Residual tumor volume as best outcome predictor in low grade glioma – A nine-years near-randomized survey of surgery vs. biopsy. *Sci Rep* 2016;6:32286.
63. You G, Huang L, Yang P, Zhang W, Yan W, Wang Y, *et al.* Clinical and molecular genetic factors affecting postoperative seizure control of 183 Chinese adult patients with low-grade gliomas. *Eur J Neurol* 2012;19:298-306.
64. Gunnarsson T, Olafsson E, Sighvatsson V, Hannesson B. Surgical treatment of patients with low-grade astrocytomas and medically intractable seizures. *Acta Neurol Scand* 2002;105:289-92.
65. Gulati S, Jakola AS, Nerland US, Weber C, Solheim O. The risk of getting worse: surgically acquired deficits, perioperative complications, and functional outcomes after primary resection of glioblastoma. *World Neurosurg* 2011;76:572-9.
66. Mikuni N, Okada T, Enatsu R, Miki Y, Hanakawa T, Urayama S, *et al.* Clinical impact of integrated functional neuronavigation and subcortical electrical stimulation to preserve motor function during resection of brain tumors. *J Neurosurg* 2007;106:593-8.
67. Alimohamadi M, Shirani M, Shariat Moharari R, Pour-Rashidi A, Ketabchi M, Khajavi M, *et al.* Application of awake craniotomy and intraoperative brain mapping for surgical resection of insular gliomas of the dominant hemisphere. *World Neurosurg* 2016;92:151-8.
68. Stummer W, Pichlmeier U, Meinel T, Wiestler OD, Zanella F, Reulen HJ, *et al.* Fluorescence-guided surgery with 5-aminolevulinic acid for resection of malignant glioma: A randomised controlled multicentre phase III trial. *Lancet Oncol* 2006;7:392-401.
69. Schucht P, Beck J, Abu-Isa J, Anderegg L, Murek M, Seidel K, *et al.* Gross total resection rates in contemporary glioblastoma surgery: Results of an institutional protocol combining 5-aminolevulinic acid intraoperative fluorescence imaging and brain mapping. *Neurosurgery* 2012;71:927-35.
70. Sanai N, Snyder LA, Honea NJ, Coons SW, Eschbacher JM, Smith KA, *et al.* Intraoperative confocal microscopy in the visualization of 5-aminolevulinic acid fluorescence in low-grade gliomas. *J Neurosurg* 2011b;115:740-8.
71. Chan DT, Yi-Pin Sonia H, Poon WS. 5-Aminolevulinic acid fluorescence guided resection of malignant glioma: Hong Kong experience. *Asian J Surg* 2018;41:467-72.
72. Titworth WL, Scott RM, Smith ER. National analysis of 2454 pediatric moyamoya admissions and the effect of hospital volume on outcomes. *Stroke* 2016;47:1303-11.
73. Kalani MY, Rangel-Castilla L, Ramey W, Nakaji P, Albuquerque FC, McDougall CG, *et al.* Indications and results of direct cerebral revascularization in the modern era. *World Neurosurg* 2015;83:345-50.
74. Bokhari AR, Davies MA, Diamond T. Endoscopic transsphenoidal pituitary surgery: A single surgeon experience and the learning curve. *Br J Neurosurg* 2013;27:44-9.
75. Amato L, Colais P, Davoli M, Ferroni E, Fusco D, Minozzi S, *et al.* Volume and health outcomes: Evidence from systematic reviews and from evaluation of Italian hospital data. *Epidemiol Prev* 2013;37:1-00.
76. Archampong D, Borowski D, Wille-Jørgensen P, Iversen LH. Workload and surgeon's specialty for outcome after colorectal cancer surgery. *Cochrane Database Syst Rev* 2012;3:CD005391.
77. Modrall JG, Rosero EB, Chung J, Arko FR 3<sup>rd</sup>, Valentine RJ, Clagett GP, *et al.* Defining the type of surgeon volume that influences the outcomes for open abdominal aortic aneurysm repair. *J Vasc Surg* 2011;54:1599-604.
78. Modrall JG, Minter RM, Minhajuddin A, Eslava-Schmalbach J, Joshi GP, Patel S, *et al.* The surgeon volume-outcome relationship: not yet ready for policy. *Ann Surg* 2018;267:863-7.
79. Young EL, Holt PJ, Poloniecki JD, Loftus IM, Thompson MM. Meta-analysis and systematic review of the relationship between surgeon annual caseload and mortality for elective open abdominal aortic aneurysm repairs. *J Vasc Surg* 2007;46:1287-94.
80. Rogers SO Jr., Gawande AA, Kwaan M, Puopolo AL, Yoon C, Brennan TA, *et al.* Analysis of surgical errors in closed malpractice claims at 4 liability insurers. *Surgery* 2006;140:25-33.
81. Somville FJ, van Sprundel M, Somville J. Analysis of surgical errors in malpractice claims in Belgium. *Acta Chir Belg*

- 2010;110:11-8.
82. Schmidt CM, Turrini O, Parikh P, House MG, Zyromski NJ, Nakeeb A, *et al.* Effect of hospital volume, surgeon experience, and surgeon volume on patient outcomes after pancreaticoduodenectomy: A single-institution experience. *Arch Surg* 2010;145:634-40.
  83. Goh BK, Teo JY, Lee SY, Kam JH, Cheow PC, Jeyaraj P, *et al.* Critical appraisal of the impact of individual surgeon experience on the outcomes of laparoscopic liver resection in the modern era: Collective experience of multiple surgeons at a single institution with 324 consecutive cases. *Surg Endosc* 2018;32:1802-11.
  84. Gani F, Cerullo M, Zhang X, Canner JK, Conca-Cheng A, Hartzman AE, *et al.* Effect of surgeon “experience” with laparoscopy on postoperative outcomes after colorectal surgery. *Surgery* 2017;162:880-90.
  85. Fossati N, Di Trapani E, Gandaglia G, Dell’Oglio P, Umari P, Buffi NM, *et al.* Assessing the impact of surgeon experience on urinary continence recovery after robot-assisted radical prostatectomy: Results of four high-volume surgeons. *J Endourol* 2017;31:872-7.
  86. Lhuillier L, Jeancolas AL, Renaudin L, Goetz C, Ameloot F, Premy S, *et al.* Impact of ophthalmic surgeon experience on early postoperative central corneal thickness after cataract surgery. *Cornea* 2017;36:541-5.
  87. Hobbs MS, Mai Q, Knuiman MW, Fletcher DR, Ridout SC. Surgeon experience and trends in intraoperative complications in laparoscopic cholecystectomy. *Br J Surg* 2006;93:844-53.
  88. Hammond JW, Queale WS, Kim TK, McFarland EG. Surgeon experience and clinical and economic outcomes for shoulder arthroplasty. *J Bone Joint Surg Am* 2003;85:2318-24.
  89. Duffau H. Higher-Order Surgical Questions for Diffuse Low-Grade Gliomas: Supramaximal Resection, Neuroplasticity, and Screening. *Neurosurg Clin N Am* 2019;30:119-28.
  90. Duffau H. Diffuse low-grade glioma, oncological outcome and quality of life: a surgical perspective. *Curr Opin Oncol* 2018;30:383-9.
  91. Duffau H. Mapping the connectome in awake surgery for gliomas: an update. *J Neurosurg Sci* 2017;61:612-60.
  92. de Leeuw CN, Vogelbaum MA. Supratotal resection in glioma: a systematic review. *Neuro Oncol* 2019;21:179-88.
  93. Dimou J, Beland B, Kelly J. Supramaximal resection: A systematic review of its safety, efficacy and feasibility in glioblastoma. *J Clin Neurosci* 2019. p. S0967-5868.
  94. D’Souza S, Ormond DR, Costabile J, Thompson JA. Fiber-tract localized diffusion coefficients highlight patterns of white matter disruption induced by proximity to glioma. *PLoS One* 2019;14:e0225323.
  95. Duffau H. Is non-awake surgery for supratentorial adult low-grade glioma treatment still feasible? *Neurosurg Rev* 2018;4:133-9.