

Resolution of Idiopathic Epidural Lipomatosis after Bariatric Surgery: Case Report and Literature Review

Abstract

Spinal epidural lipomatosis (SEL) is traditionally a rare disorder defined as an abnormal accumulation of unencapsulated epidural fat. SEL can be classified into idiopathic and secondary. We report a 46-year-old obese male with idiopathic epidural lipomatosis with a clinical picture of bilateral L5 and S1 radiculopathy, with an L5 and S1 distribution. Magnetic resonance imaging (MRI) showed epidural lipomatosis at L4, L5, and S1. After 2-year of sleeve gastrectomy, his bilateral sciatic radiculopathy disappeared, and updated MRI showed complete resolution of epidural lipomatosis. We present a case of an unusual epidural lipomatosis, resolved completely by bariatric surgery. This case report set out the effect of metabolic surgery on the local and systemic metabolic process.

Keywords: *Bariatric, epidural lipomatosis, obesity, weight loss*

Introduction

Spinal epidural lipomatosis (SEL) is defined as a deposition of abnormal augmentation of the adipose tissue in the spinal canal. SEL is classified into idiopathic and secondary etiologies.^[1] SEL is often secondary to the local^[2] or systemic^[1,3] consumption of steroid and endocrinopathy with raised serum endogenous corticosteroid as seen in Cushing's syndrome.^[4] Nonetheless, the absence of steroid use or endocrine disease does not exclude SEL, and the literature has demonstrated obesity as a predisposing factor with SEL pathophysiology.^[5] Mechanical compression of the spinal canal by an excessive amount of adipose tissue can cause spinal stenosis and radicular pain, neurogenic claudication, or cauda equina symptoms.

Here, we present a case where a patient with morbid obesity presented with bilateral L5 and S1 radiculopathy due to idiopathic SEL. He had complete resolution of his symptoms and radiological findings after 2 years of sleeve gastrectomy (SG). Implications of this are discussed.

Case Report

A 46-year-old man with a history of diabetes mellitus type 2. He had no history

of steroid intake, epidural steroid injection, or endocrinopathy. The patient presented to our outpatient department with lumbar pain radiating bilaterally, with an L5 and S1 distribution. The pain increased progressively his walking distance to 500 m. The patient required multiple absences from work over a 1-year time interval, causing significant socioeconomic difficulties. He was following a conservative course of treatment in another hospital with anti-inflammatory medications, analgesics, and physiotherapy, but there was no improvement. Then, the patient was referred to our clinic for a surgical assessment by his family physician. On clinical examination, he was noted to be morbidly obese (Class III) with a body mass index (BMI) of 48.9 (143 kg; 171 cm), neurological examination demonstrated paresthesias in L5 and S1 dermatomes bilaterally, without focal motor deficits. He denied anal sphincter dysfunction. He had a normal gait. His lumbar pain was aggravated by palpating the soft-tissues and the paraspinal musculature of the lumbar region. In addition, Deep reflexes were 2+ at patellar and Achilles tendons bilaterally. The visual analog scale (VAS) of radicular pain was 7/10.

**Mohammad A Alsofyani,
Sultan Alsalmi¹,
Haifaa Malaekah²,
Majed Alharthi³,
Anouar Bourghli⁴,
Ibrahim Obeid⁵,
Louis Boissière⁵**

Department of Surgery, College of Medicine and University Hospital, University of Hail, Hail, ¹Department of Neurosurgery, Imam Abdulrahman Bin Faisal University, Dammam, ²Department of Surgical, King Abdullah Bin Abdulaziz University Hospital, Princess Nourah Bint Abdulrahman University, ⁴Department of Orthopedic and Spinal Surgery, Kingdom Hospital, Riyadh, ³Department of Surgical, Security Forces Hospital, Makkah, Kingdom of Saudi Arabia, ⁵Department of Spine Surgery, Specialist Terrefort Clinic, Bruges, France

Address for correspondence:
Dr. Mohammad A Alsofyani,
Department of Surgery, College
of Medicine and University
Hospital, University of Hail,
Hail, P. O. Box: 2440, Hail,
Kingdom of Saudi Arabia.
E-mail: mohd.alsogyani@gmail.
com

This is an open access journal, and articles are distributed under the terms of the Creative Commons Attribution-NonCommercial-ShareAlike 4.0 License, which allows others to remix, tweak, and build upon the work non-commercially, as long as appropriate credit is given and the new creations are licensed under the identical terms.

For reprints contact: WKHLRPMedknow_reprints@wolterskluwer.com

How to cite this article: Alsofyani MA, Alsalmi S, Malaekah H, Alharthi M, Bourghli A, Obeid I, *et al.* Resolution of idiopathic epidural lipomatosis after bariatric surgery: Case report and literature review. *Asian J Neurosurg* 2021;16:217-20.

Submitted: 14-Jun-2020 **Revised:** 07-Sep-2020
Accepted: 17-Dec-2020 **Published:** 23-Feb-2021

Access this article online

Website: www.asianjns.org

DOI: 10.4103/ajns.AJNS_294_20

Quick Response Code:



Magnetic resonance imaging (MRI) was performed on October 17, 2016, and showed epidural lipomatosis at L4, L5, and S1, reaching posteriorly from the L4 vertebral body downward to L5-S1 intervertebral disc [Figure 1].

The patient was in favor of spinal intervention but conservative was initiated first as per literature recommendations.^[5]

Two years after SG, the patient had lost 42 kg of weight with a BMI of 34.5. The patient's lower extremity radiculopathy had resolved with VAS OF 0 out of 10. MRI follow-up done on the July 1, 2019 showed that the epidural lipomatosis completely disappeared [Figure 2]. Although the back pain did not resolve due to fatty degeneration of paraspinal musculature [Figure 2a], the patient started a rehabilitation program to improve his condition.

Discussion

Metabolic syndrome is a huge challenge being encountered all over the world. Contributing factors to metabolic syndrome include sedentary lifestyle practice, increase consumption of a high-fat diet, and increase calorie intake in individuals who are suspected to have a genetic background.^[6] As per the current literature, obesity is a risk factor for the development of SEL.^[5] Fujisawa *et al.*^[7] reported one case of young girl with epidural lipomatosis secondary to pituitary tumors. Less commonly, HIV patients using protease inhibitor treatments have been described as secondary etiology.^[8,9] In 1982, Badami and Hinck^[10] reported the first idiopathic SEL in women with morbid obesity, and in 1991, the term "idiopathic SEL" was further explained by Haddad *et al.*^[11]

Metabolic surgery is a term consisting of many surgical procedures. The most commonly performed and most popular are SG, Roux-en-Y gastric bypass, and less

commonly biliopancreatic diversion with duodenal switch. In SG, up to 80% of the stomach is removed (mainly the fundus and the body alongside the arc of greater curvature).^[12,13] Bariatric surgical procedures exert local and systemic metabolic impact. The study published by Heffron *et al.*^[14] showed a significant improvement in total cholesterol, low-density lipoprotein cholesterol, triacylglycerols, and high-density lipoprotein cholesterol levels after bariatric surgery compared to non-surgical methods.

Regarding patient demographics, comorbidities, and radiological findings of patients with SEL, Yildirim *et al.*^[15] have reported 130 patients of 199 (66.8%) were male and average age at the time of diagnosis 54.9 years. High BMI shows statistically significant as comorbidity compared with the control group (36.7 vs. 29.4 kg/m², $P < 0.001$). They found central canal stenosis in 95.5% of patients diagnosed with SEL. Spinal stenosis associated with degenerative changes was observed in 85.4% of patients. This is consistent with what our patient presented with, his age in the 5th decade, his obesity, and his MRI finding of multilevel degenerative changes. While the quantity of epidural fat (EF) can be easily evaluated by MRI radiography, the diagnostic criteria of idiopathic SEL need further carefully designed studies taking into account all the risk factors of this disorder.

Borré *et al.*^[16] designed a four-grading scale for lumbosacral epidural lipomatosis (LEL) by reviewing a series of 2528 consecutive MRI results. They classified LEL into four grades according to the degree of lipomatosis seen on MRI in the axial plane [Table 1]. Based on the following measures seen in the axial plane of MRI [Figure 1]: Anteroposterior width of dural sac (A-Pd DuS), anteroposterior width of the EF located anteriorly to the dural sac (segment A), anteroposterior width of the EF located posteriorly to the dural sac (segment B) and finally, anteroposterior width of the spinal canal (A-Pd Spi C), which is known as the sum of the A-Pd DuS + segments A and B.

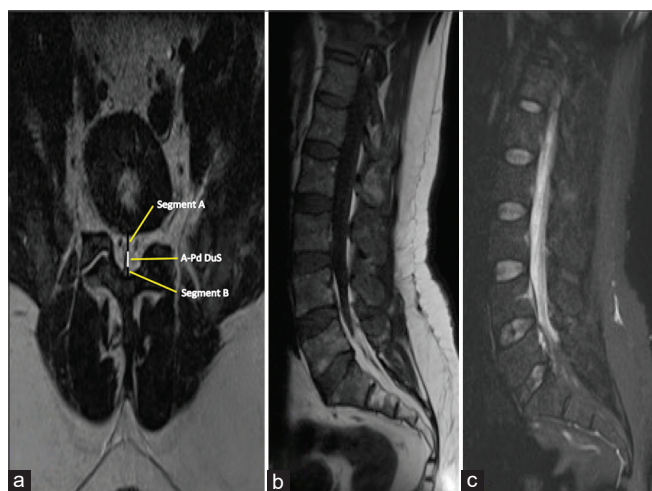


Figure 1: (a) Axial T2 images on magnetic resonance imaging demonstrating epidural lipomatosis at the level of L5-S1. (b) Sagittal T1-weighted magnetic resonance imaging. (c) Stir sequence magnetic resonance imaging

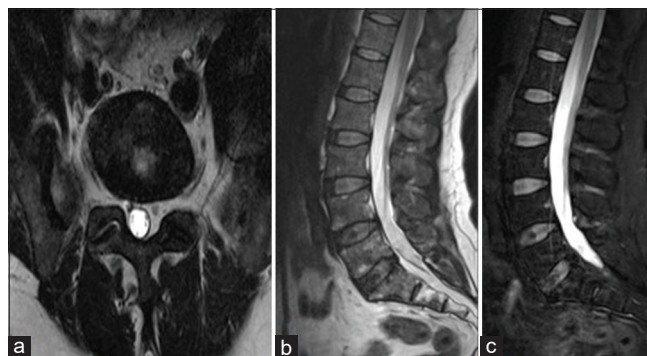


Figure 2: (a) Axial T2 images on magnetic resonance imaging demonstrating less epidural lipomatosis at the level of L5-S1 after 2 years of bariatric surgery. (b) Sagittal T2-weighted magnetic resonance imaging. (c) Stir sequence magnetic resonance imaging

Table 1: The classification of systemic lupus erythematosus based on magnetic resonance imaging measurements according to Borré

MRI grade	DuS/EF ratio	EF/Spi C ratio (%)	Interpretation
0	≥1.5	≤40	Normal amount of EF
I	1.49-1	41-50	Mild overgrowth of EF
II	0.99-0.34	51-74	Moderate overgrowth of EF
III	≤0.33	≥75	Severe overgrowth of EF

DuS – Dural sac; EF – Epidural fat; Spi C – Spinal canal; MRI – Magnetic resonance imaging

Table 2: Before and after magnetic resonance imaging grading measurements of our case report according to the Borré classification

	Segment A (mm)	Segment B (mm)	A-Pd DuS (mm)	EF (mm)	A-Pd Spi C (mm)	DuS/EF ratio	EF/Spi C index (%)
Before	7	4	6	11	17	0.54	64
After	2	1	21	3	24	7	12

DuS – Dural sac; EF – Epidural fat; Spi C – Spinal canal; A-Pd DuS – Antero-posterior width of DuS; A-Pd Spi C – Antero-posterior width of the Spi C

According to the grading scheme of Borré, our aforementioned patient had Grade III LEL [Table 2]. As our patient was symptomatic from the epidural lipomatosis, we managed him conservatively. Weight reduction has been identified to have a positive impact in the treatment of obese patients with SEL.^[11,17-24]

The treatment of SEL ranges from conservative management^[11,17-26] to surgical excision.^[5,21,25-27] There are many cases reported the resolution of SLE on losing weight either by a structured weight loss program and/or by the help of bariatric surgery.^[23,28] The spontaneous accumulation of fat in the epidural space is a dynamic process and sometimes associated with an increase in the peripheral fat mass.^[28] Notwithstanding, the published cases of association between the resolution of symptoms in SEL and weight reduction procedure, the precise mechanisms are not widely understood. Cornejo-Pareja *et al.*^[29] indicated that the mechanism of the effect of bariatric surgery on metabolism is not completely understood. To date, there are no guidelines for the therapeutic management of SEL.^[28] Further studies of a large population are needed to adequately understand the natural history of this uncommon condition.

In regard to the management of SEL, Al-Khawaja *et al.*^[5] made the first review that looked into the characteristics and treatment for 111 cases of SEL (idiopathic vs. secondary) starting from January 1966 to July 2006 using computerized databases such as Medline, Embase, and PubMed. Overall, this review presents the results of surgical management were 60% with complete relief of symptoms when the lesion found in lumbar segments in both idiopathic and secondary SEL. In view of all the aforementioned information, one may suppose that the role of non-surgical treatment in SEL when it found in lumbar segments. To the best of our knowledge, Valcarengi *et al.*^[28] reported the first case of SEL in the literature with complete resolving of symptoms after SG. In this

case, we reported the second case report of SEL treated non-surgically with complete clinical and radiological disappearance after SG. However, one feature makes our case unique within the literature: Persistence of back pain due to fatty degeneration of paraspinal musculature.

As a whole, our case present with the literature^[28] highlights an important role for nonsurgical treatment of SEL and the impact of bariatric surgery on spontaneous resolution of SEL. The aforementioned patient classified as Grade III epidural lipomatosis and has shown that the importance and benefit of the Borré classification for knowing the degree of severity of this lesion.

Declaration of patient consent

The authors certify that they have obtained all appropriate patient consent forms. In the form, the patient(s) has given his consent for his images and other clinical information to be reported in the journal. The patients understand that their names and initials will not be published and due efforts will be made to conceal their identity, but anonymity cannot be guaranteed.

Acknowledgment

The author would like to acknowledge Mrs Soraya Barchi for her contribution to edit the language and for sharing her experience with us.

Financial support and sponsorship

Nil.

Conflicts of interest

There are no conflicts of interest.

References

- George WE Jr., Wilmot M, Greenhouse A, Hammeke M. Medical management of steroid-induced epidural lipomatosis. *N Engl J Med* 1983;308:316-9.
- McCullen GM, Spurling GR, Webster JS. Epidural lipomatosis

- complicating lumbar steroid injections. *J Spinal Disord* 1999;12:526-9.
3. Fessler RG, Johnson DL, Brown FD, Erickson RK, Reid SA, Kranzler L. Epidural lipomatosis in steroid-treated patients. *Spine (Phila Pa 1976)* 1992;17:183-8.
 4. Noël P, Peppersack T, Vanbinst A, Allé JL. Spinal epidural lipomatosis in Cushing's syndrome secondary to an adrenal tumor. *Neurology* 1992;42:1250-1.
 5. Al-Khawaja D, Seex K, Eslick GD. Spinal epidural lipomatosis – A brief review. *J Clin Neurosci* 2008;15:1323-6.
 6. Blachnio-Zabielska A, Grycel S, Chacińska M, Zabielski P. The role of adipose tissue and excess of fatty acids in the induction of insulin resistance in skeletal muscle. *Postepy Hig Med Dosw (Online)* 2016;70:1142-9.
 7. Fujisawa H, Hasegawa M, Tachibana O, Yamashita J. Spinal epidural lipomatosis associated with pituitary macroprolactinoma. *Acta Neurochir (Wien)* 2002;144:213-4.
 8. Cersósimo MG, Lasala B, Folgar S, Micheli F. Epidural lipomatosis secondary to indinavir in an HIV-positive patient. *Clin Neuropharmacol* 2002;25:51-4.
 9. Vince GH, Brucker C, Langmann P, Herbold C, Solymosi L, Roosen K. Epidural spinal lipomatosis with acute onset of paraplegia in an HIV-positive patient treated with corticosteroids and protease inhibitor: Case report. *Spine (Phila Pa 1976)* 2005;30:E524-7.
 10. Badami JP, Hinck VC. Symptomatic deposition of epidural fat in a morbidly obese woman. *AJNR Am J Neuroradiol* 1982;3:664-5.
 11. Haddad SF, Hitchon PW, Godersky JC. Idiopathic and glucocorticoid-induced spinal epidural lipomatosis. *J Neurosurg* 1991;74:38-42.
 12. Mofidi R, Duff MD, Wigmore SJ, Madhavan KK, Garden OJ, Parks RW. Association between early systemic inflammatory response, severity of multiorgan dysfunction and death in acute pancreatitis. *Br J Surg* 2006;93:738-44.
 13. Ren CJ, Patterson E, Gagner M. Early results of laparoscopic biliopancreatic diversion with duodenal switch: A case series of 40 consecutive patients. *Obes Surg* 2000;10:514-23.
 14. Heffron SP, Parikh A, Volodarskiy A, Ren-Fielding C, Schwartzbard A, Nicholson J, *et al.* Changes in lipid profile of obese patients following contemporary bariatric surgery: A meta-analysis. *Am J Med* 2016;129:952-9.
 15. Yildirim B, Puvanesarajah V, An HS, Novicoff WM, Jain A, Shen FH, *et al.* Lumbosacral epidural lipomatosis: A retrospective matched case-control database study. *World Neurosurg* 2016;96:209-14.
 16. Borré DG, Borré GE, Aude F, Palmieri GN. Lumbosacral epidural lipomatosis: MRI grading. *Eur Radiol* 2003;13:1709-21.
 17. van Rooij WJ, Borstlap AC, Canta LR, Tijssen CC. Lumbar epidural lipomatosis causing neurogenic claudication in two obese patients. *Clin Neurol Neurosurg* 1994;96:181-4.
 18. Beges C, Rousselin B, Chevrot A, Godefroy D, Vallee C, Berenbaum F, *et al.* Epidural lipomatosis. Interest of magnetic resonance imaging in a weight-reduction treated case. *Spine (Phila Pa 1976)* 1994;19:251-4.
 19. Pouchot J, Si-Hassen C, Damade R, Bayeux MC, Mathieu A, Vinceneux P. Cauda equina compression by epidural lipomatosis in obesity. Effectiveness of weight reduction. *J Rheumatol* 1995;22:1771-5.
 20. Borstlap AC, van Rooij WJ, Sluzewski M, Leyten AC, Beute G. Reversibility of lumbar epidural lipomatosis in obese patients after weight-reduction diet. *Neuroradiology* 1995;37:670-3.
 21. Qasho R, Ramundo OE, Maraglino C, Lunardi P, Ricci G. Epidural lipomatosis with lumbar radiculopathy in one obese patient. Case report and review of the literature. *Neurosurg Rev* 1997;20:206-9.
 22. Maillot F, Mulleman D, Mammou S, Goupille P, Valat JP. Is epidural lipomatosis associated with abnormality of body fat distribution? A case report. *Eur Spine J* 2006;15:105-8.
 23. Patel AJ, Sellin J, Ehni BL, Tatsui CE. Spontaneous resolution of spinal epidural lipomatosis. *J Clin Neurosci* 2013;20:1595-7.
 24. Alsofyani MA, Haignere V, Alsalmi S, Gille O, Vital JM, Pointillart V, *et al.* Idiopathic epidural lipomatosis associated with degenerative discopathy: Grand round presentation of unusual lumbar canal stenosis resolved by weight loss. *Asian J Neurosurg* 2020;15:180-3.
 25. Beckworth WJ, McCarty EJ, Garcia-Corrada JE, Holbrook JF. Epidural lipomatosis and associated spinal stenosis—the impact of weight loss: A case report. *Am J Lifestyle Med* 2017;11:511-4.
 26. Payer M, Van Schaeysbroeck P, Reverdin A, May D. Idiopathic symptomatic epidural lipomatosis of the lumbar spine. *Acta Neurochir (Wien)* 2003;145:315-20.
 27. Ferlic PW, Mannion AF, Jeszenszky D, Porchet F, Fekete TF, Kleinstück F, *et al.* Patient-reported outcome of surgical treatment for lumbar spinal epidural lipomatosis. *Spine J* 2016;16:1333-41.
 28. Valcarengi J, Bath O, Boghal H, Ruelle M, Lambert J. Benefits of bariatric surgery on spinal epidural lipomatosis: Case report and literature review. *Eur J Orthop Surg Traumatol* 2018;28:1437-40.
 29. Cornejo-Pareja I, Clemente-Postigo M, Tinahones FJ. Metabolic and endocrine consequences of bariatric surgery. *Front Endocrinol (Lausanne)* 2019;10:626.