

# Treatment Outcomes of Cerebral Aneurysms Presenting with Optic Neuropathy: A Retrospective Case Series

## Abstract

**Background:** Optic neuropathy due to an aneurysm is relatively rare, with only a few small case series on this topic, and no randomized trials having been published until now. As such, the functional prognosis and treatment for aneurysm-induced optic neuropathy remain controversial. **Objective:** We quantified optic nerve injuries using an objective index (the visual impairment score) and evaluated prognostic factors of postoperative visual function. **Materials and Methods:** Of 960 patients treated for an unruptured intracranial aneurysm, 18 (1.9%) patients had optic neuropathy. Visual acuity and visual field were assessed before surgery and 6 months' postoperatively. Cases were classified on the basis of treatment modality (coil embolization or flow alteration [FA]) and prognostic factors of the two treatment groups. **Results:** Of the 18 patients with an intracranial aneurysm and optic neuropathy, 12 (67%) were treated using coil embolization and 6 (33%) were FA. Visual function improved after surgery in 8 patients (44%), 5 (42%) in the coil embolization group, and 3 (50%) in the FA group. The visual function remained stable after surgery in 6 (33%) patients and worsened in 4 (22%). Patients with an aneurysms <15 mm in size had a favorable outcome ( $P = 0.05$ ). **Conclusions:** Surgical treatment improved vision in 44% of cases, with no difference in the prognosis of coil embolization and FA and no effect of the duration of symptoms on outcomes. Further, the prognosis of visual function recovery was better for aneurysms <15 mm in diameter.

**Keywords:** Coil embolization, intracranial aneurysm, optic nerve neuropathy, parent artery occlusion, visual impairment score

## Introduction

Neuropathy secondary to nerve compression by an aneurysm occurs in 8%–15.4% of all aneurysms.<sup>[1,2]</sup> Among these cases, oculomotor nerve palsy is the most common, developing in 20% of patients with aneurysms in the cavernous sinus segment and 33% of patients with aneurysms in the posterior communicating artery.<sup>[3,4]</sup> Some authors have reported that 90% of patients with an oculomotor nerve palsy caused by an aneurysm recover after treatment, with the following being prognostic factors of a good recovery: a short interval between symptom onset and treatment, incomplete oculomotor nerve palsy, younger age, no history of risk factors for cardiovascular disease, and clipping used as the treatment.<sup>[3,5]</sup>

Optic neuropathy caused by an aneurysm is rare, with an incidence rate of 1.4% among all patients with an aneurysm.<sup>[6]</sup> The improvement of optic

neuropathy after treatment is lower than for oculomotor nerve palsy, with factors for a good prognosis including a short interval between symptom onset and treatment and not receiving treatment with endovascular coil embolization. However, prognostic factors remain uncertain, as the evidence is based solely on case reports, without objective evaluation.<sup>[7,8]</sup> Although both oculomotor nerve palsy and optic neuropathy are induced by compression from an aneurysm, different clinical courses are expected.

Visual function includes both acuity and visual field (VF), both of which have not been objectively evaluated in prior case studies of optic neuropathy. Therefore, in this study, we evaluated visual function, using the visual impairment score (VIS), before and after treatment of an optic neuropathy caused by an intrasellar tumor. To the best of our knowledge, no prior study has used the VIS to objectively evaluate visual function in patients with an intracranial aneurysm accompanied

Koji Hirata<sup>1</sup>,  
Yoshiro Ito<sup>1</sup>,  
Wataro Tsuruta<sup>1,2</sup>,  
Tomoji Takigawa<sup>1,3</sup>,  
Aiki Marushima<sup>1</sup>,  
Masayuki Sato<sup>1,2</sup>,  
Mikito Hayakawa<sup>4</sup>,  
Yasunobu Nakai<sup>5</sup>,  
Noriyuki Kato<sup>6</sup>,  
Kazuya Uemura<sup>5</sup>,  
Kensuke Suzuki<sup>3</sup>,  
Yuji Matsumaru<sup>2,4</sup>,  
Akio Hyodo<sup>3</sup>,  
Eiichi Ishikawa<sup>1</sup>,  
Akira Matsumura<sup>1</sup>

<sup>1</sup>Department of Neurosurgery, Faculty of Medicine, University of Tsukuba, <sup>2</sup>Department of Neurosurgery, Division for Stroke, Faculty of Medicine, University of Tsukuba, <sup>3</sup>Department of Neurosurgery, Tsukuba Medical Center Hospital, Tsukuba, <sup>4</sup>Department of Neurosurgery, National Hospital Organization Mito Medical Center, Mito, Ibaraki, <sup>5</sup>Department of Neuro-Endovascular Therapy, Toranomon Hospital, Minato, Tokyo, <sup>6</sup>Department of Neurosurgery, Saitama Medical Center, Dokkyo Medical University, Koshigaya, Saitama, Japan

### Address for correspondence:

Dr. Yoshiro Ito,  
Department of Neurosurgery,  
Faculty of Medicine, University  
of Tsukuba, 1-1-1 Tennodai,  
Tsukuba, Ibaraki 305-8575,  
Japan.

E-mail: yoshiro@md.tsukuba.ac.jp

### Access this article online

Website: [www.asianjns.org](http://www.asianjns.org)

DOI: 10.4103/ajns.AJNS\_294\_18

### Quick Response Code:



**How to cite this article:** Hirata K, Ito Y, Tsuruta W, Takigawa T, Marushima A, Sato M, *et al.* Treatment outcomes of cerebral aneurysms presenting with optic neuropathy: A retrospective case series. *Asian J Neurosurg* 2019;14:499-505.

This is an open access journal, and articles are distributed under the terms of the Creative Commons Attribution-NonCommercial-ShareAlike 4.0 License, which allows others to remix, tweak, and build upon the work non-commercially, as long as appropriate credit is given and the new creations are licensed under the identical terms.

For reprints contact: [reprints@medknow.com](mailto:reprints@medknow.com)

by visual symptoms. We evaluated prognostic factors for postoperative visual function.

**Materials and Methods**

Between January 2009 and April 2014, our group performed 960 treatments for an unruptured intracranial aneurysm. Among these cases, we reviewed the data from 18 (1.9%) patients who presented with an associated optic neuropathy. All patients underwent an ophthalmic examination to evaluate visual acuity (VA) and VF, both before and after surgical treatment, as a part of our routine clinical practice. The VIS was developed by the German Ophthalmological Society.<sup>[9,10]</sup> Fahlbusch and Schott used this method to analyze the visual status and outcomes of patients treated surgically for a tuberculum sellae or planum sphenoidale meningioma.<sup>[11]</sup> Neurosurgeons performed a clinical follow-up at 6-month postsurgery.

To calculate the VIS (with a maximum of score 100), we summed the VA and VF scores [Figure 1]. For example, a VA score of 25 and VF score of 20 yielded a VIS of 45. A lower VIS is indicative of better visual function. In the absence of data on the visual disorder, only VA was used. A favorable outcome was defined as an improvement in visual function, and an unfavorable outcome was defined as a stable or worsening visual function. The site and maximum diameter of the aneurysm were defined by two independent neurosurgeons. We adopted the Bouthillier classification for segmentation of the internal carotid artery (ICA).<sup>[12]</sup>

The treatment method was decided on the basis of a discussion between the surgical and endovascular teams. Direct surgery for giant aneurysms, exerting a mass effect and brain/artery shift, is more complex and dangerous than endovascular surgery. For an aneurysm exerting a mass effect, neck clipping or flow alteration (FA) is necessary to eliminate the mass effect. However, neck clipping is quite difficult because the optic nerve is very fragile and prone to irreversible damage during surgical

manipulation. Therefore, the following decision scheme for treatment was established for patients presenting with an aneurysms with optic neuropathy on the basis of evaluation of the ischemic tolerance using the cross-flow and balloon occlusion tests. According to this decision scheme, patients with sufficient ischemic tolerance were treated using FA, whereas patients with insufficient ischemic tolerance were treated using FA with bypass or coil embolization, and patients without ischemic tolerance were treated using coil embolization. Patient status, location of the aneurysm, and experience of the treating surgeon were taken into consideration. When a patient chose endovascular treatment as a less invasive treatment, we adhered to the patient’s request. Aneurysm obliteration was performed using surgical ligation or coil embolization, with or without low/high flow bypass. Coil embolization was performed with or without balloon remodeling or stent-assisted coiling.

We extracted the following demographic and clinical data from medical records for analysis: age, sex, aneurysm site and size, thrombosis, symptom duration, preoperative/postoperative VIS, treatment modality, and complications. Patients either underwent treatment with FA, in which occlusion of the parent artery was performed directly or intravascularly, or underwent coil embolization (coil). No patients underwent clipping of the aneurysm or required a flow diverter stent. We assessed visual function at 6 months after the treatment and retrospectively assessed factors associated with favorable outcome.

We divided patients according to the treatment modality employed, namely FA or coil, to identify prognostic factors. Specifically, we compared age, sex, aneurysm site and size, symptom duration, preoperative/postoperative VIS, thrombosis, and complications between the FA and coil group.

The study was approved by the Institutional Review Committee: NEMMOPHILA study (NeuroEndovascular and surgical Management from Multicenter Observation to build a PHILosophical Approach study).

**Statistical analysis**

Statistical analyses were performed using SPSS (version 23, IBM SPSS Statistics, Armonk, NY, USA). Univariate analyses were performed using the Mann–Whitney U-test for continuous data and Fisher’s exact test for categorical variables. The Kruskal–Wallis test and Wilcoxon signed-rank sum test were used to compare the VIS at each aneurysm site. A receiver operating characteristic (ROC) analysis was used to assess prognostic performance and to determine the preoperative VIS threshold that differentiated between good and poor outcomes. Differences with *P* < 0.05 were deemed statistically significant.

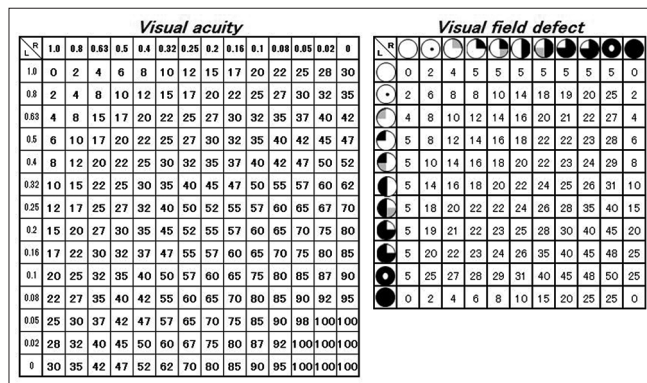


Figure 1: The visual acuity and visual field defect scores, based on the German Ophthalmological Society criteria, are shown, with the sum of the visual acuity and the visual field scores, providing a visual impairment score ranging between 0 and 100

## Results

### Patient characteristics

Of the 18 patients with an intracranial aneurysm, 15 (83%) were women. The mean age ( $\pm$ standard deviation) of all patients was  $59.2 \pm 11.1$  years. The site of the aneurysm was C5 in 5 patients (28%), C6 in 7 (39%), C7 in 4 (22%), and the anterior communicating artery (Acom) in 2 (11%). There were no differences in the size of aneurysms at the different sites. There were ten patients a duration of symptoms of  $<3$  months. The median preoperative VIS was 22. Preoperative VF was evaluated in 16 patients, of whom 5 (28%) had bilateral VF deficit. All C5 aneurysms were accompanied by a unilateral VF deficit. Preoperative VA of 8 patients (44%) was  $<0.1$ , of whom 7 (88%) had a C7 or C6 aneurysm [Table 1]. There was a tendency for the VIS to increase with more distal aneurysms. The relevant characteristics of our sample group are presented in Table 2.

### Treatment outcome

Coil treatment was performed in 12 patients (67%), while 6 patients (33%) underwent FA. Of the 12 patients who underwent coil treatment, complete obliteration was obtained in 7 (58%) patients, with a neck remnant identified in 5 (42%) patients. Two patients who had aneurysms with signs of recanalization on follow-up imaging at 12 months and 16 months after surgery required additional coil embolization. Of the 6 patients who were treated with FA, 5 had endovascular parent artery trapping, with 1 patient requiring surgical ligation. There were no differences in the size or site of aneurysm between the coil and FA treatment groups.

**Table 1: Summary of the clinical data and visual assessment (n=18)**

Factors	
Female, n (%)	15 (83)
Age (years), mean $\pm$ SD	59.2 $\pm$ 11.1
Size (mm), mean $\pm$ SD	20.6 $\pm$ 11.5
Location	
C5, n (%)	5 (28)
C6, n (%)	7 (39)
C7, n (%)	4 (22)
Acom, n (%)	2 (11)
Thrombosis, n (%)	6 (33)
Symptom duration $<3$ months, n (%)	10 (56)
Preoperative VIS, median (IQR)	22 (6.5-29.5)
VA score, median (IQR)	14 (3-27)
VF score, median (IQR)	5 (4.25-6.3)
Treatment (coil/FA), n	12/6
Postoperative VIS, median (IQR)	23 (7-29.5)
VA score, median (IQR)	14 (1.5-27.8)
VF score, median (IQR)	5 (0-15)

SD – Standard deviation; IQR – Interquartile range; Acom – Anterior communicating artery; VIS – Visual impairment score; VA – Visual acuity; VF – Visual field; FA – Flow alteration

The median postoperative VIS was 22.5 among all patients. After treatment, a favorable outcome was identified in 8 patients (45%), 5 in the coil group and 3 in the FA group. Vision function was unchanged in 6 patients (33%), 4 in the coil group and 2 in the FA group, and unfavorable outcomes were identified in 4 patients (22%), 3 in the coil group and 1 in the FA group. The size shrinkage of aneurysms was identified in 3 patients, none in the coil group and 3 in the FA group. There were no differences between the rate of favorable and unfavorable outcomes with regard to aneurysm site, symptom duration, treatment modality, or preoperative VIS (including total, VA, and VF score). However, patients with an aneurysm  $<15$  mm in diameter tended to have better outcomes [ $P = 0.05$ ; Table 3], with this cutoff value having a sensitivity and specificity on ROC curve analysis of 0.80 and 0.75, respectively, with an area under the curve of 0.70 (95% confidence interval, 0.44–0.96).

The median preoperative VIS was 28 for the 12 patients treated with coil and 7 for the 6 patients treated with FA, while the median postoperative VIS was 27.5 after coil embolization and 8 after FA. There was no statistical difference in the VIS between the two groups, either before or after surgery.

There was no difference in the prognosis of the optic neuropathy between the two different modalities. Symptomatic ischemic complications owing to the treatment occurred in 4 patients, 3 in the coil group (25%), and 1 in the FA group (17%), with these complications being transient [Table 4].

## Discussion

A large intracranial aneurysm can result in impairment in cranial nerve function, with oculomotor nerve palsy being the most common. Oculomotor nerve palsy resulting from compression by an intracranial aneurysm can be improved by obstruction of the parent vessels or by a loss/partial reduction of the aneurysmal pulse after coil embolization.<sup>[13,14]</sup> By comparison, there is little information available on the treatment of optic nerve neuropathy, with visual function after surgical treatment remaining to be fully clarified. Among our study group, aneurysms located at the distal portion of the ICA tended to be associated with severe visual dysfunction. Although postoperative visual function was not influenced by treatment method or the timing of treatment, the outcomes did tend to be better for aneurysms  $<15$  mm in diameter.

### Treatment modality

We identified favorable outcomes for both coil (42%) and FA (50%). This rate of favorable outcome is comparable to the 41% previously reported after coil embolization; however, these studies also reported a worsening of visual

**Table 2: Summary of patient’s characteristics, treatment, visual assessment**

n	Age	Sex	Location	Size (mm)	Symptom duration (month)	Treatment	VA score		VF score		VIS	
							Pre	Post	Pre	Post	Pre	Post
1	62	Female	Lt. C5	14	<1	FA	3	0	5	0	8	0
2	77	Female	Lt. C5	21	1-3	FA	14	10	5	0	19	10
3	42	Female	Lt. C5	48 +T	12 <	FA + B	22	22	5	5	27	27
4	69	Female	Lt. C5	9	1-3	Coil	1	3	2	2	3	5
5	47	Female	Lt. C5	23	12 <	FA + B	4	30	2	0	6	30
6	68	Female	Rt. C6	14	6-12	FA + B	0	0	5	4	5	4
7	60	Female	Rt. C6	11	12 <	Coil	27	22	5	5	32	27
8	56	Female	Lt. C6	17 +T	1-3	FA	1	1	5	5	6	6
9	42	Male	Rt. C6	10	3-6	Coil	28	28	0	0	28	28
10	40	Female	Lt. C6	32	6-12	Coil	0	0	18	18	18	18
11	59	Female	Rt. C6	16	1-3	Coil	27	27	5	31	32	58
12	62	Female	Rt. C6	18	1-3	Coil	20	60	5	25	25	85
13	69	Female	Rt. C7	14 +T	1-3	Coil	44	17	10	10	54	27
14	66	Female	Rt. C7	25	12 <	Coil	55	30	45	25	100	55
15	77	Female	Lt. C7	50+T	1-3	Coil	3	3	-	-	3	3
16	57	Male	Lt. C7	22	12 <	Coil	30	30	0	0	30	30
17	65	Female	Acom	14 +T	1-3	Coil	15	10	-	-	15	10
18	48	Male	Acom	14 +T	<1	Coil	6	1	22	14	28	15

VA – Visual acuity; VF – Visual field; VIS – Visual impairment score; Rt – Right; Lt – Left; Acom – Anterior communicating artery; T – Thrombosis; FA – Flow alteration; B – Bypass; Coil – Coil embolization

**Table 3: Comparison of characteristics between favorable and unfavorable outcomes**

	Favorable (n=8)	Unfavorable (n=10)	P
Age (years), mean±SD	64.4±7.8	55.1±11.7	0.68
Size <15 mm, n (%)	6 (75)	2 (20)	0.05
Location			
C5, n (%)	2 (25)	3 (30)	
C6, n (%)	2 (25)	5 (50)	
C7, n (%)	2 (25)	2 (20)	
Acom, n (%)	2 (25)	0	
Preoperative VIS, median (IQR)	23.5 (13.3-37.5)	21.5 (6.0-27.8)	0.32
VA score, median (IQR)	14.5 (5.2-31.3)	4 (1-22)	0.57
VF score, median (IQR)	5 (5-16)	5 (2-5)	0.06
Symptom duration <3 months, n (%)	5 (63)	5 (50)	0.66

Acom – Anterior communicating artery; VIS – Visual impairment score; VA – Visual acuity; VF – Visual field; SD – Standard deviation; IQR – Interquartile range

function in 5%–29% of cases after coil embolization, owing to a mass effect of the aneurysm.<sup>[8,13,15-20]</sup> Micieli *et al.* reported that clipping of large aneurysms associated with optic nerve neuropathy provided better outcomes than coil embolization, but it carries a higher risk for major complications compared with coil embolization.<sup>[21]</sup> Other studies reported better visual function outcomes with FA than with either coil embolization or clipping.<sup>[7,13,18]</sup> In our study, we did not identify a difference in outcome between coil and FA. Our prognosis of good visual function after surgery for the coil group was similar to that in previous reports, but visual function was lower than expected for the FA group. Function of the optic nerve can be improved by avoiding a mass effect during coil embolization and by direct contact with the aneurysm. However, thrombosis of the aneurysm and inflammation extending around

the aneurysm could still negatively affect optic nerve function.<sup>[7,13,18,22]</sup>

Few studies have reported on the outcome of using flow-diverting devices for the treatment of an aneurysm associated with optic neuropathy.<sup>[22-24]</sup> Flow-diverting devices can eliminate the compression caused by the aneurysm while preserving the patency of the parent artery. As such, flow-diverting devices could provide an optimal treatment modality of optic neuropathy resulting from compression by an aneurysm. Miyachi *et al.*<sup>[22]</sup> reported on the safety and efficacy of using a flow-diverting device for the treatment of large carotid cavernous aneurysms. For these aneurysms, flow-diverting devices were safer and more effective than FA or stent-assisted coil embolism. However, the

**Table 4: Comparison of characteristics between coiling group and flow alteration group**

	Coil (n=12)	FA (n=6)	P
Age (years), mean±SD	59.5±11.2	58.7±13.1	0.89
Size (mm) mean±SD	19.5±11.7	22.8±12.9	0.60
Location			
C5, n (%)	1 (8)	4 (67)	
C6, n (%)	5 (42)	2 (33)	
C7, n (%)	4 (33)	0	
Acom, n (%)	2 (17)	0	
Preoperative VIS, median (IQR)	28 (17.2-32)	7 (6-16.3)	0.08
VA score, median (IQR)	20 (4.5-27.5)	3.5 (1.5-11.5)	0.08
VF score, median (IQR)	5 (2.7-16)	5 (5)	0.63
Postoperative VIS, median (IQR)	27.5 (13.7-36.2)	8 (4.5-22.7)	0.12
VA score, median (IQR)	19.5 (3-28.5)	5.5 (0.2-19)	0.25
VF score, median (IQR)	12 (2.7-23.2)	2 (0-4.7)	0.07
Favorable outcome, n (%)	5 (42)	3 (50)	0.73
Ischemic complication, n (%)	3 (25)	1 (17)	0.69

Acom – Anterior communicating artery; SD – Standard deviation; IQR – Interquartile range; VIS – Visual impairment score; VA – Visual acuity; VF – Visual field; FA – Flow alteration; Coil – Coil embolization

use of flow-diverting devices does not always improve postoperative visual function.<sup>[22-24]</sup>

Thrombosed aneurysms may continue to grow because of a hypertrophic vasa vasorum and subadventitial hemorrhages. It has been reported that endovascular ligation could not eliminate the vasa vasorum.<sup>[25,26]</sup> In the present study, aneurysm enlargement was not observed in any case after treatment. In cases of thrombosed aneurysms, therefore, direct ligation may be better than endovascular ligation.

### Size and site of aneurysm

On the basis of our results, better visual function after surgery can be expected with smaller aneurysms (<15 mm in diameter). Of note, previous studies have indicated that there is no relationship between the size of an aneurysm and the prognosis for visual function in cases of optic neuropathy.<sup>[7,27,28]</sup> However, these studies included patients treated for giant aneurysms only, and a detailed examination of the threshold size of an aneurysm for good prognosis has not previously been conducted.

Aneurysms near the optic nerve present with more severe symptoms, although an effect of aneurysm location on visual function, measured using the VIS, was not identified. Only C7 or C6 aneurysms presented with bilateral visual symptoms, while all C5 aneurysms presented with unilateral visual symptoms. It was common for the preoperative VA score for C7 or C6 aneurysms to be <20, while C5 aneurysms did not present with particularly severe symptoms. We suggest that if an aneurysm is anatomically distant from the optic nerve on the contralateral side, it would be discovered before progression to bilateral visual symptoms.

In this study, FA reduced the size of an aneurysm to a greater extent after treatment than did coil embolization. Although coil embolization did not reduce the size of the

aneurysm, improvements in visual function were identified in some patients in the coil group. This improvement is likely associated with the elimination of pulsation inside the aneurysm sac after coil embolization.<sup>[13]</sup>

### Symptom duration

It is commonly considered that treatment early after the onset of symptoms can improve oculomotor nerve palsy induced by aneurysm compression.<sup>[5,29-31]</sup> However, for optic neuropathy, this relationship remains controversial.<sup>[7,13,28]</sup> In our study, we did not identify a correlation between symptom duration and the prognosis for visual function. Symptoms of oculomotor nerve palsy include double vision, ptosis, and pupil dilation. These symptoms occur relatively acutely, and therefore, diagnosis and treatment is implemented early, which is possible because medical examination is fast and simple. Kassis and Turner reported that the time from symptom onset to treatment for an aneurysm with oculomotor nerve palsy is usually a few days and certainly <1 month.<sup>[4,32]</sup> In our study, some patients had a duration of symptoms >1 year at the time of treatment. Symptoms of decreased VA and VF deficits, owing to an increase in the size of the aneurysm, progressed slowly, making them more difficult to observe. Due to this long delay between symptom onset and treatment, irreversible change to the optic nerve was inevitable.

### Limitations

The limitations of our study need to be considered in the interpretation of our results. First, we included a small number of cases, with an unequal number of patients in the coil and FA group. Second, we included cases with optic neuropathy but did not include any cases with ruptured aneurysms. Third, treatment modality depended on the decision of the attending physician, rather than being randomly allocated. Fourth, in some countries, flow diverter

stents are used for the treatment of aneurysms although this technique was not used in the period of this study, which may limit the generalizability of our findings.

## Conclusions

In this study, we investigated the treatment outcomes for intracranial aneurysms causing optic neuropathy using an objective index, the VIS, to assess visual function. Surgical treatment improves vision in 44% of cases, with no difference in the prognosis of coil embolization and FA and with no effect of the duration of symptoms on outcomes. However, aneurysms located near the optic nerve were associated with more severe symptoms, including bilateral VF deficits and severe visual loss. Further, the prognosis of recovery of visual function was better for aneurysms <15 mm in diameter.

## Acknowledgments

We would like to thank Editage (www.editage.jp) for English language editing.

## Financial support and sponsorship

Nil.

## Conflicts of interest

There are no conflicts of interest.

## References

- International Study of Unruptured Intracranial Aneurysms Investigators. Unruptured intracranial aneurysms – Risk of rupture and risks of surgical intervention. *N Engl J Med* 1998;339:1725-33.
- Koskela E, Setälä K, Kivisaari R, Hernesniemi J, Laakso A. Neuro-ophthalmic presentation and surgical results of unruptured intracranial aneurysms – Prospective Helsinki experience of 142 patients. *World Neurosurg* 2015;83:614-9.
- Linskey ME, Sekhar LN, Hirsch W Jr., Yonas H, Horton JA. Aneurysms of the intracavernous carotid artery: Clinical presentation, radiographic features, and pathogenesis. *Neurosurgery* 1990;26:71-9.
- Kassis SZ, Jouanneau E, Tahon FB, Salkine F, Perrin G, Turjman F, *et al.* Recovery of third nerve palsy after endovascular treatment of posterior communicating artery aneurysms. *World Neurosurg* 2010;73:11-6.
- Chen PR, Amin-Hanjani S, Albuquerque FC, McDougall C, Zabramski JM, Spetzler RF, *et al.* Outcome of oculomotor nerve palsy from posterior communicating artery aneurysms: Comparison of clipping and coiling. *Neurosurgery* 2006;58:1040-6.
- White JC, Ballantine HT Jr. Intracranial aneurysms simulating hypophyseal tumours. *J Neurosurg* 1961;18:34-50.
- Date I, Asari S, Ohmoto T. Cerebral aneurysms causing visual symptoms: Their features and surgical outcome. *Clin Neurol Neurosurg* 1998;100:259-67.
- Park W, Park JC, Han K, Ahn JS, Kwun BD. Anterior optic pathway compression due to internal carotid artery aneurysms: Neurosurgical management and outcomes. *J Stroke* 2015;17:344-53.
- Deutsche Ophthalmologische Gesellschaft: Empfehlungen zur beurteilung der minderung der erwerbsfähigkeit durch schäden des sehvermögens. *Der Augenarzt* 1981;6:486-90.
- Deutsche Ophthalmologische Gesellschaft: Empfehlungen zur beurteilung der minderung der erwerbsfähigkeit durch schäden des sehvermögens. *Klin Mbl Augenheilk* 1982;180:242-5.
- Fahlbusch R, Schott W. Pterional surgery of meningiomas of the tuberculum sellae and planum sphenoidale: Surgical results with special consideration of ophthalmological and endocrinological outcomes. *J Neurosurg* 2002;96:235-43.
- Bouthillier A, van Loveren HR, Keller JT. Segments of the internal carotid artery: A new classification. *Neurosurgery* 1996;38:425-32.
- Hassan T, Hamimi A. Successful endovascular management of brain aneurysms presenting with mass effect and cranial nerve palsy. *Neurosurg Rev* 2013;36:87-97.
- Rashad S, Hassan T, Aziz W, Marei A. Carotid artery occlusion for the treatment of symptomatic giant carotid aneurysms: A proposal of classification and surgical protocol. *Neurosurg Rev* 2014;37:501-11.
- Vargas ME, Kupersmith MJ, Setton A, Nelson K, Berenstein A. Endovascular treatment of giant aneurysms which cause visual loss. *Ophthalmology* 1994;101:1091-8.
- Malisch TW, Guglielmi G, Viñuela F, Duckwiler G, Gobin YP, Martin NA, *et al.* Unruptured aneurysms presenting with mass effect symptoms: Response to endosaccular treatment with Guglielmi detachable coils. Part I. Symptoms of cranial nerve dysfunction. *J Neurosurg* 1998;89:956-61.
- Kim DJ, Kim DI, Lee SK, Kim SY. Unruptured aneurysms with cranial nerve symptoms: Efficacy of endosaccular Guglielmi detachable coil treatment. *Korean J Radiol* 2003;4:141-5.
- Heran NS, Song JK, Kupersmith MJ, Niimi Y, Namba K, Langer DJ, *et al.* Large ophthalmic segment aneurysms with anterior optic pathway compression: Assessment of anatomical and visual outcomes after endosaccular coil therapy. *J Neurosurg* 2007;106:968-75.
- Suzuki S, Kurata A, Kan S, Yamada M, Niki J, Yuzawa I, *et al.* Efficacy of endovascular surgery for unruptured internal carotid artery aneurysms presenting with cranial nerve symptoms. *Interv Neuroradiol* 2007;13 Suppl 1:163-9.
- Schuss P, Güresir E, Berkefeld J, Seifert V, Vatter H. Influence of surgical or endovascular treatment on visual symptoms caused by intracranial aneurysms: Single-center series and systematic review. *J Neurosurg* 2011;115:694-9.
- Micieli JA, Newman NJ, Barrow DL, Biouesse V. Intracranial aneurysms of neuro-ophthalmologic relevance. *J Neuroophthalmol* 2017;37:421-39.
- Miyachi S, Ohnishi H, Hiramatsu R, Izumi T, Matsubara N, Kuroiwa T, *et al.* Innovations in endovascular treatment strategies for large carotid cavernous aneurysms—the safety and efficacy of a flow diverter. *J Stroke Cerebrovasc Dis* 2017;26:1071-80.
- Szikora I, Marosfoi M, Salomváry B, Berentei Z, Gubucz I. Resolution of mass effect and compression symptoms following endoluminal flow diversion for the treatment of intracranial aneurysms. *AJNR Am J Neuroradiol* 2013;34:935-9.
- Moon K, Albuquerque FC, Ducruet AF, Crowley RW, McDougall CG. Resolution of cranial neuropathies following treatment of intracranial aneurysms with the pipeline embolization device. *J Neurosurg* 2014;121:1085-92.
- Dehdashti AR, Thines L, Willinsky RA, Tymianski M. Symptomatic enlargement of an occluded giant carotido-ophthalmic aneurysm after endovascular treatment: The vasa vasorum theory. *Acta Neurochir (Wien)* 2009;151:1153-8.
- Pahl FH, Vellutini Ede A, Cardoso AC, de Oliveira MF. Vasa

- vasorum and the growing of thrombosed giant aneurysm of the vertebral artery: A case report. *World Neurosurg* 2016;85:368.e1-4.
27. de Oliveira JG, Borba LA, Rassi-Neto A, de Moura SM, Sanchez-Júnior SL, Rassi MS, *et al.* Intracranial aneurysms presenting with mass effect over the anterior optic pathways: Neurosurgical management and outcomes. *Neurosurg Focus* 2009;26:E3.
  28. Dehdashti AR, Le Roux A, Bacigaluppi S, Wallace MC. Long-term visual outcome and aneurysm obliteration rate for very large and giant ophthalmic segment aneurysms: Assessment of surgical treatment. *Acta Neurochir (Wien)* 2012;154:43-52.
  29. Hamer J. Prognosis of oculomotor palsy in patients with aneurysms of the posterior communicating artery. *Acta Neurochir (Wien)* 1982;66:173-85.
  30. Good EF. Ptosis as the sole manifestation of compression of the oculomotor nerve by an aneurysm of the posterior communicating artery. *J Clin Neuroophthalmol* 1990;10:59-61.
  31. Leivo S, Hernesniemi J, Luukkonen M, Vapalahti M. Early surgery improves the cure of aneurysm-induced oculomotor palsy. *Surg Neurol* 1996;45:430-4.
  32. Turner RD, Byrne JV, Kelly ME, Mitsos AP, Gonugunta V, Lalloo S, *et al.* Delayed visual deficits and monocular blindness after endovascular treatment of large and giant paraophthalmic aneurysms. *Neurosurgery* 2008;63:469-74.