

# Intraparenchymal Pericatheter Cyst after Cerebrospinal Fluid Shunt: A Rare Complication with Challenging Diagnosis – Case Presentation and Review of the Literature

## Abstract

An intraparenchymal pericatheter cyst is a rare complication of ventriculoperitoneal shunt, which is not well described yet. Due to its rarity, lack of characteristic symptoms and radiological features that often mimic brain tumors or abscesses, especially in head computed tomography without contrast can be easily misdiagnosed. We report the case of a 9-year-old girl who was admitted to a peripheral hospital due to severe headaches and vomiting. The child had a history of craniotomy and ventriculoperitoneal shunt for posterior fossa tumor, performed in our department, 4 years earlier. The patient underwent a brain magnetic resonance imaging (MRI) scan and transmitted to our hospital with the diagnosis of brain tumor. However, a closer look at the MRI established the diagnosis of intraparenchymal pericatheter cerebrospinal fluid cyst; hence, the patient underwent shunt revision and cyst drainage. We researched the literature and described 20 reported cases, discussing the pathophysiological mechanisms, the radiological features, and the optimal treatment of this interesting, yet a challenging complication.

**Keywords:** Cerebrospinal fluid, intraparenchymal pericatheter cyst, shunt revision, ventriculoperitoneal shunt

## Introduction

Intraparenchymal pericatheter cyst following a ventriculoperitoneal shunt is not a well-described entity. Although rare, it is a complication that can be easily misdiagnosed, mimicking a tumor or a brain abscess. Hence, it is critical for a physician to understand the unique radiological features of these lesions. As the pathophysiological mechanism of these cysts is thought to be the obstruction of the ventricular tip of the catheter, a complication that still occurs in up to 50% of pediatric and 29% of adult patients,<sup>[1]</sup> we believe that the number of pericatheter cysts may increase in the coming years.

## Case Report

A 9-year-old girl was admitted to a peripheral hospital due to severe vomiting and headaches. According to her father, she suffered recurrent headaches which started 3 weeks prior. Clinical examination and blood tests showed no pathological findings, except mild dehydration caused by

vomiting. The child stayed at the hospital, and a magnetic resonance imaging (MRI) scan was performed the next morning, which revealed a sizable frontal lesion. As a result, the child was immediately transferred to our hospital with the diagnosis of a possible brain tumor or brain abscess.

The girl was already known to our department, as she had undergone a craniotomy for the removal of a pilocytic astrocytoma of the posterior fossa 4 years earlier. The tumor had been completely resected, and a ventriculoperitoneal shunt had been placed, as the girl had presented with hydrocephalus and bilateral papilledema. The patient had then been scheduled for the annual follow-up with MRI scan, with no pathological findings, even in the last scan, which had been performed 6 months before the last admission.

We performed a meticulous clinical examination with no significant findings. A new brain MRI scan, performed in our

**Ploutarchos Karydakis, Ioannis Nikas<sup>1</sup>, Dimitrios Panagopoulos<sup>2</sup>, Maria Filippidou<sup>3</sup>, George Sfakianos<sup>2</sup>, Marios Themistocleous<sup>2</sup>**

*Department of Neurosurgery, 251 Hellenic Air Force General Hospital, <sup>1</sup>Department of Medical Imaging and Interventional Radiology, Agia Sofia Children's Hospital, <sup>2</sup>Department of Neurosurgery, Children Hospital "Aghia Sophia", <sup>3</sup>First Department of Pediatrics, University of Athens, "Agia Sofia" Children's Hospital, Athens, Greece*

**Address for correspondence:**  
Dr. Ploutarchos Karydakis,  
9 Athanasiou Diakou Str.,  
15562, Cholargos, Athens,  
Greece.  
E-mail: karydakispl@gmail.com

### Access this article online

**Website:** www.asianjns.org

**DOI:** 10.4103/ajns.AJNS\_288\_18

### Quick Response Code:



**How to cite this article:** Karydakis P, Nikas I, Panagopoulos D, Filippidou M, Sfakianos G, Themistocleous M. Intraparenchymal pericatheter cyst after cerebrospinal fluid shunt: A rare complication with challenging diagnosis – Case presentation and review of the literature. Asian J Neurosurg 2019;14:581-4.

This is an open access journal, and articles are distributed under the terms of the Creative Commons Attribution-NonCommercial-ShareAlike 4.0 License, which allows others to remix, tweak, and build upon the work non-commercially, as long as appropriate credit is given and the new creations are licensed under the identical terms.

**For reprints contact:** reprints@medknow.com

hospital, is shown in Figure 1. The lesion was thought to be a tumor, and the patient was initially scheduled for a craniotomy. However, a closer look by our radiologists changed our plans, as they considered the lesion to be a cystic formation containing cerebrospinal fluid (CSF).

The cyst was homogenous, well demarcated, following the CSF pattern in all MRI sequences (hyperintense in T2-weighted, hypointense in T1 and hypointense in fluid-attenuated inversion recovery), with a diameter of 3.06 cm and surrounding edema. Lack of gadolinium enhancement made the diagnosis of a tumor improbable. The fact that there was no diffusion restriction, combined with normal blood tests and absence of fever, allowed us to rule out a brain abscess. As a result, the diagnosis of intraparenchymal pericatheter cyst was established, and the patient was taken to the operating theater, for a more conservative surgical approach than craniotomy. Intraoperatively, obstruction of the ventricular tip was confirmed; hence, shunt revision and cyst drainage were performed. Patient's symptoms improved and postoperative MRI scan confirmed the absence of the cyst [Figure 2].

## Discussion

Concerning the number of shunts performed every day, intraparenchymal pericatheter cyst is an infrequent complication with only 20 reported cases worldwide (11/2018), 13 of which in pediatric patients and seven in adults. Noteworthy, in four out of the seven adult cases shunt was placed when they were infants or children.<sup>[2-5]</sup> Etiology for initial shunt placement varies, but our patient is the only child that had a shunt placed after tumor resection. Apart from ventriculoperitoneal shunt, which accounts for most of the cases, such cysts have been reported with Ommaya reservoirs and ventriculosubgaleal shunts.<sup>[3,6,7]</sup>

In most of the cases, the complication occurred months or a few years after the initial shunt insertion. However, there are two cases in which the cyst developed after 15

and 19 years, respectively.<sup>[2,8]</sup> We assume that in these cases cyst formation had probably begun soon after the placement, but became symptomatic many years later. In our case, annual MRI had not shown signs of cyst even 4 months before symptoms arose.

The lesion is visible on computed tomography (CT) scan, but a brain MRI is useful to differentiate cyst from CSF edema, tumor, or even abscess, especially in cysts covered by a thin wall, as the one presented.<sup>[8]</sup> Vasogenic edema around the cysts was present in all reported cases. As mentioned above, lack of enhancement after contrast injection and no diffusion restriction can be very useful in differential diagnosis. Furthermore, a CT cisternography can determine whether there is communication between the cyst and the ventricles and support the diagnosis of a CSF cyst.<sup>[6]</sup> In addition, as shown in Table 1, only seven of the reported cases presented with typical symptoms of raised intracranial pressure.<sup>[2,3,6,7,10]</sup> As a result, careful look at the radiological images is mandatory to avoid misdiagnosis.

Obstruction of the shunt catheter is considered as the most common underlying cause of cyst formation and was present in our case, too. However, there are three reported cases in the literature, where no obstruction was present,<sup>[4,12]</sup> and some did not require shunt revision. In such cases, partial obstruction of the proximal tip may be responsible.<sup>[12]</sup> When the peripheral tip of the catheter is blocked, intracranial pressure rises.<sup>[7]</sup> As a result, CSF flows back from ventricles to the parenchyma through the opening made by the catheter itself,<sup>[6]</sup> as Balasubramaniam described with the term “direct infusion edema model.”<sup>[11]</sup> Intraparenchymal cysts can also develop when some of the ventricular catheter's holes lay outside the ventricles, creating a connection between the ventricles and the adjacent parenchyma.<sup>[4]</sup> Pericatheter cysts are more common among pediatric patients, probably because they develop more taut ventricles than adults after shunt placement, while their brain parenchyma is softer.<sup>[2,6]</sup> In

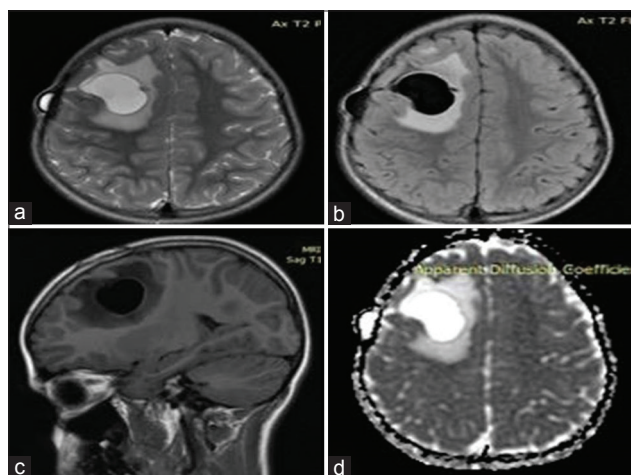


Figure 1: (a) T2, (b) T2 FLAIR, (c) T1 FLAIR, (d) ADC MRI

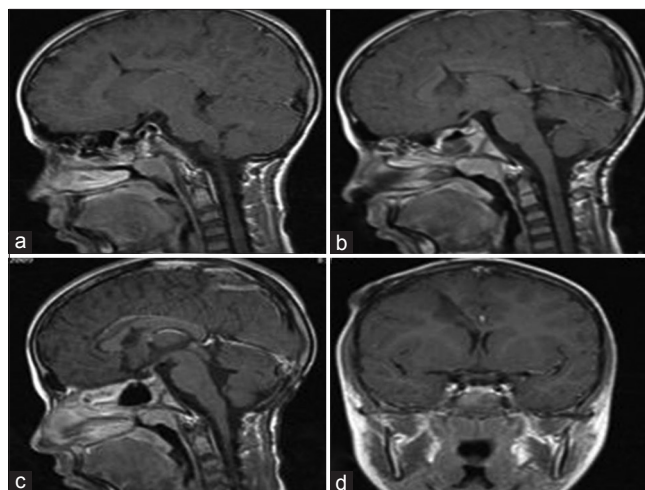


Figure 2: Postoperative MRI T1W (a-c) sagittal and (d) coronal

**Table 1: Summary of reported cases**

Author	Age	Interval from initial shunt	Primary diagnosis	Symptoms	Shunt revision
Iqbal <i>et al.</i> , 2000 <sup>[6]</sup>	10 years	10 years	Meningomyelocele	Headaches, vomiting, weakness and spasm of the right arm	Yes
Sugimoto <i>et al.</i> , 1991 <sup>[9]</sup>	10 years		Posttraumatic hydrocephalus	Headaches, nausea	Yes
	5 months	2 months	Meningomyelocele	Vomiting	Yes
Sakamoto <i>et al.</i> , 1994 <sup>[3]</sup>	5 months	2 months	Meningitis	Vomiting	Yes
	2 years	2 years	Congenital hydrocephalus		Yes
	7 years	3 months	Meningomyelocele	Subcutaneous CSF collection	Yes
	7 years	9 months	Achondroplasia	Vomiting	Yes
	6 years	1 year	Encephalocele	Vomiting	Yes
Watkins <i>et al.</i> , 2015 <sup>[5]</sup>	19 years	1 month	Neurofibromatosis I	Headache, unconscious	Yes
Rim <i>et al.</i> , 2011 <sup>[10]</sup>	26 years	1 week	Aneurysmal subarachnoid hemorrhage	Visual disturbance	Yes
Balasubramaniam <i>et al.</i> , 2013 <sup>[11]</sup>	2 months	2 months	Neonatal hydrocephalus	Fontanel bulging	Yes
Shekawat <i>et al.</i> , 2012 <sup>[7]</sup>	1, 5 years	1, 5 years	Meningomyelocele	Generalized tonic-clonic seizures	Yes
Amans and Dillon, 2013 <sup>[2]</sup>	65 years		Cerebellopontine angle mass	Right hemiparesis	Yes
Bianchi <i>et al.</i> , 2017 <sup>[8]</sup>	20 years	15 years	Meningitis	Hemianopsia, headache, vomiting	Yes
Sinha <i>et al.</i> , 2008 <sup>[12]</sup>	19 years	19 years	Meningomyelocele	Left hemiparesis	Yes
Vajramani and Fugleholm, 2005 <sup>[4]</sup>	4 years	4 years	Meningomyelocele	Asymptomatic	No
	5 months	4 weeks	Intraventricular cyst	Asymptomatic	No
Wallace and Grandhi, 2017 <sup>[13]</sup>	51 years	5 years	Meningioma	Speech and writing disturbance	Yes
	60 years		Aneurysmal subarachnoid hemorrhage	Headaches, confusion, gait imbalance	

CSF – Cerebrospinal fluid

addition, Varjmani described a case of a patient who underwent radiation treatment after shunt procedures, and there are indications that radiation may have played a role in cyst formation, due to changes that occurred in white matter.<sup>[4]</sup>

Whether these mechanisms will lead to the formation of CSF cyst or CSF edema depends on how fast the blockage occurs along with the gliosis degree around the catheter tract, the brain and ventricle compliance and the pressure grading between ventricles and the adjacent white matter.<sup>[6,10]</sup> A cyst occurs more easily on the grounds of high-pressure gradient and gliosis. Vasogenic edema around the cysts is often reported and was present in our case too.<sup>[2]</sup> The mechanism of its development is not clear yet, but it is considered to be developed similarly to CSF cyst, as CSF flows back from the ventricles. Fluid may also move directly from the cyst to the interstitial space.

The fact that obstruction is probably the triggering factor of cyst formation leads to the conclusion that shunt revision is mandatory, even if the symptoms are not typical of shunt obstruction.<sup>[8,13]</sup> However, there have been reported two cases where no signs of shunt obstruction were noticed, thus only cyst aspiration was performed, and patients were scheduled for regular follow-up by CT. Conservative treatment has the advantage of avoiding an operation, but if an underlying, even partial, obstruction

is present, these patients may need shunt revision in the future. Intraparenchymal pericatheter cyst is still a rare complication that can occur not only in children but also in adults, even many years after ventriculoperitoneal shunt insertion.<sup>[14]</sup> Malfunction of the peripheral tip of the catheter is considered to be the cause of cyst formation, thus shunt revision and cyst drainage is the treatment of choice. The exact incidence of this complication is still unknown, as many asymptomatic cases remain undiagnosed. No cyst recurrence has been reported in any case so far when shunt revision was performed. However, more research should be done to fully understand the pathophysiological etiology and determine the optimal treatment.

#### Declaration of patient consent

The authors certify that they have obtained all appropriate patient consent forms. In the form the patient(s) has/have given his/her/their consent for his/her/their images and other clinical information to be reported in the journal. The patients understand that their names and initials will not be published and due efforts will be made to conceal their identity, but anonymity cannot be guaranteed.

#### Financial support and sponsorship

Nil.

## Conflicts of interest

There are no conflicts of interest.

## References

1. Stone JJ, Walker CT, Jacobson M, Phillips V, Silberstein HJ. Revision rate of pediatric ventriculoperitoneal shunts after 15 years. *J Neurosurg Pediatr* 2013;11:15-9.
2. Amans MR, Dillon WP. Cerebral parenchymal cyst: A rare complication of ventriculoperitoneal shunt malfunction in an adult. *Radiol Case Rep* 2013;8:784.
3. Sakamoto H, Fujitani K, Kitano S, Murata K, Hakuba A. Cerebrospinal fluid edema associated with shunt obstruction. *J Neurosurg* 1994;81:179-83.
4. Vajramani GV, Fugleholm K. Reversible CSF cyst related to a functioning ventriculo-peritoneal shunt. *Acta Neurochir (Wien)* 2005;147:1199-202.
5. Watkins JD, Lee J, Van Engen MJ, Tibbs ML, Ellegala DB, Nicholas JS, *et al.* Isolated left homonymous hemianopia secondary to a pericatheter cyst-a rare presentation of a ventriculoperitoneal shunt failure. *J Neuroophthalmol* 2015;35:60-4.
6. Iqbal J, Hassounah M, Sheikh B. Intraparenchymal pericatheter cyst. A rare complication of ventriculoperitoneal shunt for hydrocephalus. *Br J Neurosurg* 2000;14:255-8.
7. Shekawat JS, Sundar IV, Poonia N, Sinha VD. Intraparenchymal pericatheter cyst following ventriculoperitoneal shunt. *Neurol India* 2012;60:341-2.
8. Bianchi F, Frassanito P, Tamburrini G, Caldarelli M, Massimi L. Shunt malfunction mimicking a cystic tumour. *Br J Neurosurg* 2017;31:484-6.
9. Sugimoto K, Enomoto T, Nose T. Reversible porencephaly. Alteration of the cerebrospinal fluid flow after shunt malfunction. *Childs Nerv Syst* 1991;7:394-8.
10. Rim HR, Hwang SK, Kwon SH, Kim HM. Intraparenchymal pericatheter cyst as a complication of a ventriculo-peritoneal shunt in a premature infant. *J Korean Neurosurg Soc* 2011;50:143-6.
11. Balasubramaniam S, Tyagi DK, Sawant HV. Intraparenchymal pericatheter cyst following disconnection of ventriculoperitoneal shunt system. *J Postgrad Med* 2013;59:232-4.
12. Sinha AK, Lall R, Benson R, O'Brien DF, Buxton N. Intraparenchymal pericatheter cyst following ventriculoperitoneal shunt insertion: Does it always merit shunt revision? *Zentralbl Neurochir* 2008;69:152-4.
13. Wallace DJ, Grandhi R. Intraparenchymal pericatheter cyst in ventriculoperitoneal shunt failure. *BMJ Case Rep* 2017;2017. pii: bcr-2017-220468.
14. Khan F, Rehman A, Shamim MS, Bari ME. Factors affecting ventriculoperitoneal shunt survival in adult patients. *Surg Neurol Int* 2015;6:25.