

En Plaque Meningioma Presenting as a Cutaneous Nodule

Abstract

Meningiomas are the most common central nervous system tumor and can be found anywhere in the neuraxis. In rare cases, they may extend beyond the cranial vault, while cases without evidence of intracranial mass existence have also been reported. Here, we report the case of a 64-year-old male patient with a history of craniectomy for parasagittal meningioma, who presented at the emergency department with onset of focal seizures. The patient underwent nonenhanced brain computed tomography scan which was indicative of recurrence of the mass. The patient was scheduled for craniotomy and excision of the mass. He also expressed his desire to have a scalp nodule removed concomitantly. Thickening of the meninges underlying the nodule was observed but without indication of a space-occupying lesion. Both histological examinations were suggestive of Grade II, atypical meningiomas. A case of a subcutaneous meningioma in a patient with a history of surgically excised parasagittal meningioma is presented. Radiologic evidence of dural proliferation underlying the mass was suggestive of an en plaque meningioma secondary to iatrogenic dissemination of tumor cells.

Keywords: *Cutaneous meningioma, en plaque meningioma, extracranial meningioma*

Introduction

Meningiomas are the most common central nervous system (CNS) tumor, with over one-third of primary intracranial masses and over one half of their benign subgroup, having a histological diagnosis of meningeal origin.^[1] They can arise virtually wherever the meningeal sheath is present from the optic nerve^[2] to the cauda equina,^[3] their incidence is age dependent, and a female predominance has been reported.^[1]

While considered histologically benign, some have the propensity of adjacent structure infiltration, i.e., brain or skull, in the case of the latter, presenting as a palpable scalp mass. However, rare cases of scalp meningiomas, without evidence of intracranial mass existence, have been reported.

Here, we present the case of an isolated scalp meningioma in a patient with a history of craniectomy for meningioma resection.

Case Report

A 64-year-old male patient presented at the emergency department with focal

seizures affecting his right upper and lower limbs. He had a history of subtotally resected, left parasagittal meningioma, which infiltrated the superior sagittal sinus, 10 months previously, and was since under levetiracetam 1000 mg twice daily. The patient underwent clinical and preclinical examination which was unremarkable with the exception of right hemiparesis.

Magnetic resonance imaging (MRI) of the brain with intravenously administered contrast revealed the presence of an inhomogeneously enhanced, intracranial, parasagittal mass, measuring about 3.3 cm × 3.0 cm × 1.8 cm with associated peritumoral edema, extending in both cerebral hemispheres [Figure 1a-c]. The mass extended subcutaneously, through the cranial defect. The patient also underwent magnetic resonance angiography of the cerebral blood vessels, which demonstrated complete occlusion of the superior sagittal sinus by the tumor. Providing the neurologic symptomatology and the radiologic recurrence of the mass, surgical removal was advised.

Before the operation, the patient expressed his desire to have a subcutaneous nodule located left parietally and at the outermost edge of the previous craniotomy removed

**Sotirios
Apostolakis,
Aikaterini
Karagianni,
Ioannis Mylonakis,
Konstantinos
Vlachos,
Lavrentios Roussos**

*Department of Neurosurgery,
KAT General Hospital of Attica,
Kifissia, Greece*

Address for correspondence:

*Dr. Sotirios Apostolakis,
Department of Neurosurgery,
KAT General Hospital of Attica,
2 Nikis Street, Kifissia 14561,
Greece.
E-mail: sotapostolakis@gmail.
com*

Access this article online

Website: www.asianjns.org

DOI: 10.4103/ajns.AJNS_273_18

Quick Response Code:



How to cite this article: Apostolakis S, Karagianni A, Mylonakis I, Vlachos K, Roussos L. En plaque meningioma presenting as a cutaneous nodule. *Asian J Neurosurg* 2019;14:522-4.

This is an open access journal, and articles are distributed under the terms of the Creative Commons Attribution-NonCommercial-ShareAlike 4.0 License, which allows others to remix, tweak, and build upon the work non-commercially, as long as appropriate credit is given and the new creations are licensed under the identical terms.

For reprints contact: reprints@medknow.com

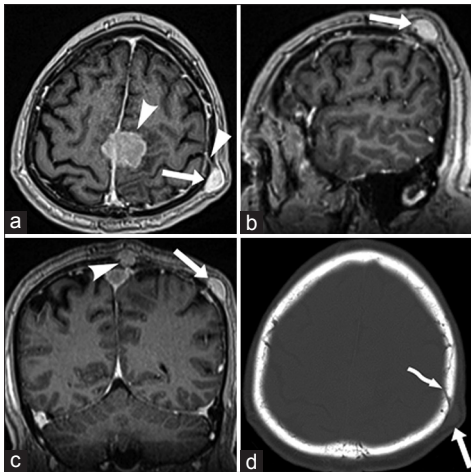


Figure 1: Preoperative magnetic resonance imaging with intravenously administered contrast (a-c) showed an inhomogeneously enhanced, intracranial mass (curved arrowhead) along with a subcutaneous nodule (arrow). The nodule appeared to be connected with the underlying meninges through contrast-enhanced tissue (arrowhead). Thickening of the underlying meninges was observed. Unenhanced computed tomography scan showed that the nodule was located just inferior to the craniotomy edge (curved arrow, d)

concomitantly. He reports the mass to have appeared following his previous operation. The nodule measured 1.6 cm × 1.3 cm × 1.8 cm and presented similar radiologic characteristics with the intracranial mass [Figure 1]. The mass appeared to be connected to the underlying meninges through contrast-enhanced tissue, traversing the bone defect from the craniotomy [Figure 1d]. Thickening of the underlying meninges was observed but without indication of a space-occupying lesion.

Elective operation was scheduled, and extension of the previous craniectomy site and total excision of the mass were performed. For cosmetic reasons, a cranioplasty with bone cement, mini-titanium plates, and crews was conducted. Macroscopically, the tumor was round and grayish in color focally adherent to the brain parenchyma. Histologic examination of the intracranial mass was suggestive of a meningioma with areas of fibrous necrosis, without indications of atypia and 5–8 mitoses/10 high-power fields. Occasionally, infiltration of the dura and the skull was observed. A gross-total resection of the subcutaneous mass and surgical incision approximation were performed in the standard fashion. The extracranial mass had similar histological characteristics. Based on the aforementioned histological findings, the diagnosis of a Grade II, atypical meningioma was made.

The patient was referred to an oncologist, and radiation therapies were initiated. He was re-evaluated 4 months postoperatively with a new brain MRI scan that, when compared with the preoperative one [Figure 2a, c and e], revealed focal recurrence of both the parasagittal and the subcutaneous masses [Figure 2b] along with the occurrence of additional intracranial masses located over the left

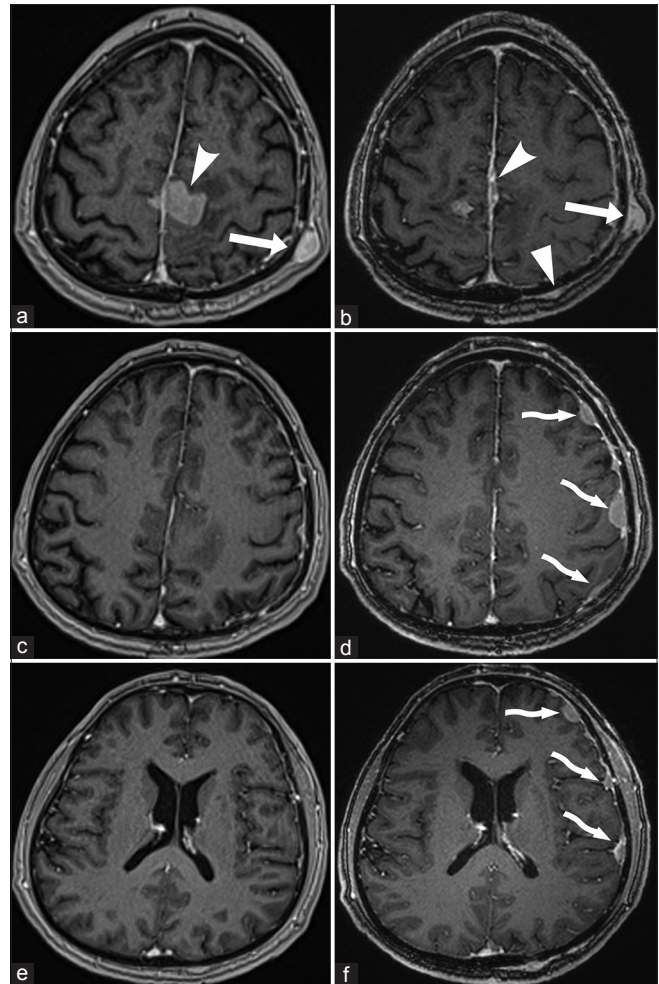


Figure 2: Compared to preoperative ones (left column, a, c, and e), T1-weighted magnetic resonance imaging with intravenously administered contrast at 4-month follow-up (right column, b, d, and f) revealed local recurrence of both the intracranial (curved arrowhead) and extracranial (arrow) masses along with the occurrence of additional intracranial masses located over the left cerebral hemisphere (curved arrow), while a new extracranial mass was also visible (arrowhead)

cerebral hemisphere [Figure 2d and f, curved arrows], while a new extracranial mass is also visible.

The patient provided a written informed consent for the release of his case history and of the visual material published in the present paper.

Discussion

In the present work, we report the case of a remote scalp meningioma in a patient with a history of craniectomy for primary site resection.

The differential diagnosis of solitary nodular lesion of the scalp includes a number of cutaneous and subcutaneous pathologies, such as trichilemmal and epidermoid cysts, benign lipomas, intradermal/epidermal nevi, sebaceous cysts, and seborrheic keratosis. Rare causes are neurofibromas, osteomas, and meningiomas.^[4]

As far as the latter is concerned, Lopez *et al.*^[5] distinguished three types of cutaneous meningiomas. Type I or primary cutaneous meningioma is present at birth and results from ectopic arachnoid cells in the cutaneous tissue following an incomplete closure of the neural tube, while no intracranial lesion is detectable. Type II or meningioma of the soft tissue and skin is frequently found in proximity to sensory organs, possibly arising from remnants of the arachnoid sheath extending beyond some cranial nerves. Again, no intracranial lesion is found; however, interestingly, skull defects have been reported in some cases.^[6,7] Finally, Type III or meningioma of the CNS and skin is characterized by an intracranial mass extending in the subcutaneous tissue most likely either from a bone defect or iatrogenically.

Providing the history of the patient presented here, the possibility of an iatrogenic dissemination of tumor cells is the most possible pathogenetic mechanism. In addition, the imaging characteristics of the underlying meninges could be suggestive of an en plaque meningioma, which rose possibly secondary to iatrogenic dissemination. Another, however less likely, possibility is an inward extension of the mass, i.e., a subcutaneous meningioma, which through the skull defect of the craniotomy extended intracranially.^[8]

En plaque meningiomas are considered different from their space-occupying counterparts both in terms of their clinical and biologic behavior, yet their histologic characteristics are similar; hence, histologic examination was the same for both lesions.^[9] They are most commonly found in the sphenoid wing and are frequently associated with hyperostosis of the overlying bone.^[9] To the best of our knowledge, transformation of an en plaque to an en masse meningioma or vice versa has not been reported to date.

Conclusions

A case of a subcutaneous meningioma in a patient with a history of surgically excised parasagittal meningioma is presented. Radiologic evidence of dural proliferation underlying the mass was suggestive of an en plaque meningioma secondary to iatrogenic dissemination of tumor cells.

Declaration of patient consent

The authors certify that they have obtained all appropriate patient consent forms. In the form the patient has given his consent for his images and other clinical information to be reported in the journal. The patient understand that his name and initials will not be published and due efforts will be made to conceal his identity, but anonymity cannot be guaranteed.

Financial support and sponsorship

Nil.

Conflicts of interest

There are no conflicts of interest.

References

- Ostrom QT, Gittleman H, Xu J, Kromer C, Wolinsky Y, Kruchko C, *et al.* CBTRUS statistical report: Primary brain and other central nervous system tumors diagnosed in the United States in 2009-2013. *Neuro Oncol* 2016;18:v1-75.
- Wright JE, Call NB, Liaricos S. Primary optic nerve meningioma. *Br J Ophthalmol* 1980;64:553-8.
- Wostrack M, Shibani E, Obermueller T, Gempt J, Meyer B, Ringel F, *et al.* Conus medullaris and cauda equina tumors: Clinical presentation, prognosis, and outcome after surgical treatment: Clinical article. *J Neurosurg Spine* 2014;20:335-43.
- Türk CÇ, Bacanlı A, Kara NN. Incidence and clinical significance of lesions presenting as a scalp mass in adult patients. *Acta Neurochir (Wien)* 2015;157:217-23.
- Lopez DA, Silvers DN, Helwig EB. Cutaneous meningiomas – A clinicopathologic study. *Cancer* 1974;34:728-44.
- Pacheco Compañía FJ, Midón Míguez J, Avellaneda Oviedo EM, Busto Lodeiro E. Post-traumatic cutaneous meningioma. *Arch Plast Surg* 2016;43:381-4.
- Ramos L, Coutinho I, Cardoso JC, Garcia H, Cordeiro MR. Frontal cutaneous meningioma – Case report. *An Bras Dermatol* 2015;90:130-3.
- Tsutsumi S, Izumi H, Yasumoto Y, Ito M. Convexity en plaque meningioma manifesting as subcutaneous mass: Case report. *Neurol Med Chir (Tokyo)* 2013;53:727-9.
- Honeybul S, Neil-Dwyer G, Lang DA, Evans BT, Ellison DW. Sphenoid wing meningioma en plaque: A clinical review. *Acta Neurochir (Wien)* 2001;143:749-57.