

Continuous Lumbar Drainage for the Prevention and Management of Perioperative Cerebrospinal Fluid Leakage

Abstract

Background: Cerebrospinal fluid (CSF) leak is an unfortunate, yet well-recognized complication of skull base fractures, skull base surgeries, and variety of spinal procedures. Continuous lumbar drainage (CLD) of leaking CSF has shown a high success rate with minimal morbidities in handling CSF leak in these patients. Therefore, we conducted this study to illustrate the efficacy of CLD as a prophylactic and therapeutic method for CSF leakage with the assessment of clinical outcome and early postoperative sequel. **Materials and Methods:** In the period from January to December 2017, patients with traumatic or postoperative CSF leak and those susceptible for postoperative CSF leak as skull base and spinal intradural surgeries at the Neurosurgery Department, Fayoum University, were included in our study. **Results:** A total of 20 eligible patients were included in the study. All patients showed successful cessation of CSF leakage at different durations of CLD. Fifteen patients showed excellent results; four showed good results; and one showed fair results. Besides a minimal pneumocephalus, headache was the most common presenting complication in our population, which occurred to all patients. Six patients had vomiting beside headache, whereas two patients experienced vomiting and nausea in addition to headache. There were neither mortalities nor life-threatening complications noted; however, a superficial wound infection occurred in a single case. **Conclusion:** CLD is a simple, safe, and efficient method in the management of CSF leakage at operative sites, CSF rhinorrhea, and CSF otorrhea of various etiologies.

Keywords: Cerebrospinal fluid, leak, lumbar drain

Introduction

Cerebrospinal fluid (CSF) leakage is an unfortunate, yet well-recognized complication of basilar skull fracture, skull base surgery, and variety of spinal surgeries.^[1-4] CSF leakage predisposes the patients to life-threatening conditions such as bacterial contamination that can end up leading to serious infections, especially meningitis. Therefore, they require careful management with close attention as well as timely evaluation and treatment.^[5] Until recently, the management of this condition was almost exclusively neurosurgical.^[6] More recently, continuous lumbar drainage (CLD) of leaking CSF has been widely used as a first step in managing such cases through the introduction of a lumbar subarachnoid catheter.^[2,4,7,8] Continuous lumbar CSF drainage is used in neurosurgical practice for many purposes, some of which are the prevention of cerebral vasospasm after subarachnoid hemorrhage, treating posttraumatic and postoperative CSF

leakage, and even reducing raised intracranial pressure. CSF perioperative diversion reduces the incidence of postoperative leaks. Lumbar drainage (LD) can be utilized as a prophylactic measure and/or as a first-line treatment for CSF leakage following surgery. It can also prevent and/or treat CSF leaks and may preclude reexploration surgery.^[9,10] CLD has shown a high success rate of 98% in patients presenting with CSF leakage or accumulation at the surgical site or due to CSF rhinorrhea, suggesting that CLD is a safe and effective method with minimal morbidity in handling these cases.^[11] Furthermore, there have been only few reports, to date, regarding the use of CLD CSF drainage and its complications. Therefore, we conducted this study to determine the success rate of this procedure in handling CSF leaking in patients postoperatively or posttraumatic and to document any complications during the procedure.

Materials and Methods

This prospective study was conducted on patients with posttraumatic or

How to cite this article: Hussein M, Abdellatif M. Continuous lumbar drainage for the prevention and management of perioperative cerebrospinal fluid leakage. *Asian J Neurosurg* 2019;14:473-8.

**Mohamed Hussein,
Mostafa Abdellatif**

*Department of Neurosurgery,
Faculty of Medicine, Fayoum
University, Fayoum, Egypt*

Address for correspondence:

*Dr. Mohamed Hussein,
Department of Neurosurgery,
Faculty of Medicine, Fayoum
University, Fayoum, Egypt.
E-mail: mlatif_971@yahoo.com*

Access this article online

Website: www.asianjns.org

DOI: 10.4103/ajns.AJNS_265_18

Quick Response Code:



This is an open access journal, and articles are distributed under the terms of the Creative Commons Attribution-NonCommercial-ShareAlike 4.0 License, which allows others to remix, tweak, and build upon the work non-commercially, as long as appropriate credit is given and the new creations are licensed under the identical terms.

For reprints contact: reprints@medknow.com

postoperative (cranial and spinal surgeries) CSF leak and those susceptible for a postoperative CSF leak after undergoing a skull base or spinal intradural surgeries at the Neurosurgery Department, Fayoum University, during the period from January to December 2017.

All patients who met the inclusion criteria during the study period were included in the study. A written consent was obtained from each eligible patient before initiation of the study. Patients with the Glasgow Coma Scale (GCS) score of <8 and patients who had an evident infection of the surrounding skin, subcutaneous tissue, bone, or epidural space were excluded from the study. Furthermore, patients with bleeding tendencies/disorders or on anticoagulant medications were ruled out from the study.

A history regarding age, gender, previous head trauma, or fluid leakage from the nose or ear was taken from all enrolled patients. The general condition of patients undergoing brain or spinal surgeries was clinically assessed for surgical fitness through a full neurological examination including conscious state with GCS, cranial nerve assessment, motor reflexes, and sensory affection. Computed tomography (CT) brain with soft tissue and bone window was performed for all patients. Magnetic resonance imaging (MRI) brain and lumbosacral spine were performed for a certain set of patients, as well as CSF analysis, culture, and sensitivity.

All patients in this study were subjected to CLD, for the management of CSF leak. Patients were placed in either the lateral decubitus or vertical anterior flexed position in the operation room, under close monitoring, and the skin was prepared under complete aseptic and sterile precautions.

A standard lumbar puncture was performed, usually in the lumbar 4–5 interspinous space, with a large-bore Tuohy needle (14–16 gauge). When CSF was encountered, the curve of the needle was directed superiorly, the stylet was removed, and the catheter was advanced into the subarachnoid space at least for 20 cm. Then, a (17–18 gauge) catheter was slowly introduced with the one hand, while the needle was simultaneously removed. The drain was attached to an external drainage sterile container. Sterile dressings were applied. A loop was made in the catheter to relieve tension, and the catheter was then taped over the patient's flank. The lumbar drain was set to the shoulder level, and patients were advised to have complete bed rest. We paid close attention and monitoring to the drain as to avoid overdrainage. The lumbar drain was set to drain 10–15 cc per hour and approximately 300–400 cc in the first 2 days. Antibiotics, analgesics, gastric protecting drugs, intravenous fluids, and neurotropic drugs were routinely given to all patients, whereas a certain group of patients were given extra drugs such as acetazolamide and other dehydrating agents based on their condition. Drainage was performed for the first 2 days following surgery. Afterward, the lumbar drain was clamped

for 24 h, and if there was no evidence of a CSF leak, the drain was to be removed on the 4th day. Seventy-two hours after stoppage of CSF leak, patients would be discharged with regular checkups in outpatient clinics.

Results

Data were collected from 20 eligible patients (12 males and 8 females) who underwent CLD of CSF. The age of patients included in this study ranged from 1 year to 60 years with the majority of patients lying in the third decade of life [Table 1].

From all patients who underwent CLD, eight presented with head trauma; eight were candidates for skull base surgery; and four were candidates for spinal surgery. A total of eight patients were presenting with posttraumatic CSF leakage, while four patients were presenting with evident postoperative CSF leakage, and eight patients were suspected to have postoperative CSF leakage.

Based on the site of CSF leakage, 14 patients showed CSF rhinorrhea, 2 patients showed CSF otorrhea, and 4 patients presented with leakage of CSF from the operation incision site.

According to the surgical management of the underlying condition, 16 patients underwent dural repair during open surgery, whereas only 4 patients underwent endoscopic surgery. For the purpose of repairing the CSF leak, the majority of our patients were subjected to the use of grafts either from fat, muscle, and fascia or pericranium. On the other hand, only four patients were subjected to primary dural repair only. CLD was performed postoperatively for the majority of patients (16 patients), whereas only four patients underwent preoperative LD procedure.

The use of CLD was nearly successful for all of our patients but at different durations with minimal morbidity. Excellent results were noted in 15 patients who showed the cessation of CSF leakage within 4 days of CLD; good results were noted in 4 patients who showed cessation of CSF leakage within 5 days of CLD; fair results were documented for just a single patient who required reexploration but eventually showed cessation of CSF leakage within 5 days of continuous drainage [Figure 1].

Minor complications were reported in this study such as headache, nausea, vomiting, and minimal pneumocephalus.

Table 1: Age of patients who underwent continuous lumbar drainage

Age (years)	Number of patients
1:10	2
10:20	3
20:30	7
30:40	4
40:50	2
50:60	2

There was no death noted in our study. However, one case had a superficial wound infection which was managed conservatively by antibiotics and repeated dressings. The most commonly reported complication following LD was headache, which occurred in all patients. Six patients experienced headache and nausea at the same time, whereas only two patients experienced headache in addition to nausea and vomiting [Figure 2]. There were no other complications noted during the postdrainage 1 month of the regular follow-ups.

Case 1

A case complaining of bitemporal headache and diminution of vision for 1 year with no improvement on medical treatments had an MRI done, which showed a homogeneously enhancing sellar mass with suprasellar extension which compressed the optic chiasma. The case had LD placed before undergoing endoscopic, transnasal, and transsphenoidal resection of a benign pituitary adenoma. Approximately 300 cc of CSF was drained over 2 days through LD which was removed on the 4th postoperative day with no evidence of CSF leak. However, postoperatively, CT revealed minimal intracranial air with no evidence of hemorrhage [Figure 3].

Case 2

A second case with a history of road traffic accident, scalp wound affecting forehead, and bleeding per nose had a CT brain with soft tissue and bone windows done, which showed frontal sinus fracture involving anterior and posterior walls, left frontal small extradural hematoma, and fissures of the left temporal bone and left orbital walls. LD was placed before undergoing transcranial frontal sinus repair. Approximately 400 cc of CSF was drained through LD over 2 days, which was later removed on the 4th postoperative day with no evidence of CSF leak. However, postoperatively, cranial CT revealed minimal intracranial air with no evidence of hemorrhage [Figure 4].

Case 3

A third case complaining of low back pain and bilateral lower limbs claudicating pain for over 7 years with increasing pain over the past year which was unresponsive to treatment presented to our office. MRI lumbosacral spine showed lumbar canal stenosis from L2 to L5. The case was operated upon by L2:L5 laminectomies and bilateral

foraminotomies and accidentally had a dural tear which was repaired with watertight dural closure with an overlying muscle graft. The case experienced CSF leak from that wound on the 2nd postoperative day which was unresponsive to lying prone or with adjuvant drugs (acetazolamide and frusemide) and repeated dressings. On the 5th postoperative day, LD was inserted and approximately 350 cc of CSF was drained through the LD over 2 days and was removed on the 4th day after insertion with no evidence of CSF leak. However, a postoperative cranial CT revealed minimal intracranial air with no evidence of hemorrhage [Figure 5].

Discussion

CLD system was first introduced by Voursh in the early 1960s.^[8] Since then, the success rate of this procedure in reducing and resolving CSF leakage has been reported by many authors to be of high percentage between 85% and 94%, showing that this system is both safe and efficacious in the majority of patients.^[2,4,7,12]

In our study, our 20 patients, 12 were male and 8 were female, underwent CLD to resolve the CSF leakage both postoperative and posttraumatic. The age of our patients ranged from 1 to 60 years, whereas most of them laid in the group from 30 to 40 years. Surprisingly, the success rate of CLD in our population was 100%; however, cessation of CSF leakage happened at different times in some sets of patients. Fifteen patients showed excellent results in CSF leakage resolution within just 4 days of CLD. On the other hand, four patients had good results where they showed cessation of CSF leakage after 5 days of CLD, while only one patient revealed fair results, and thus, a reexploration of this patient was necessary and he showed cessation of CSF leakage also within 5 days of CLD. Our results go in line with what has been reported by Huang *et al.* study which stated that successful cessation of CSF was achieved in 98% of patients. Minority of their population suffered from CSF accumulation and/or leakage at the operation incision site, while most of them suffered

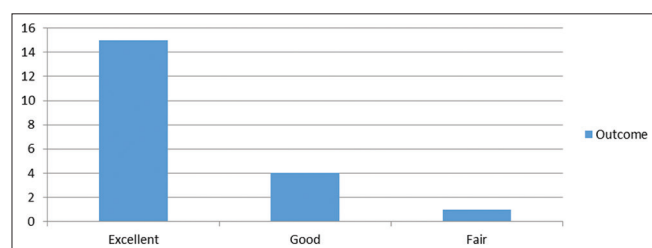


Figure 1: Outcomes of continuous lumbar drainage

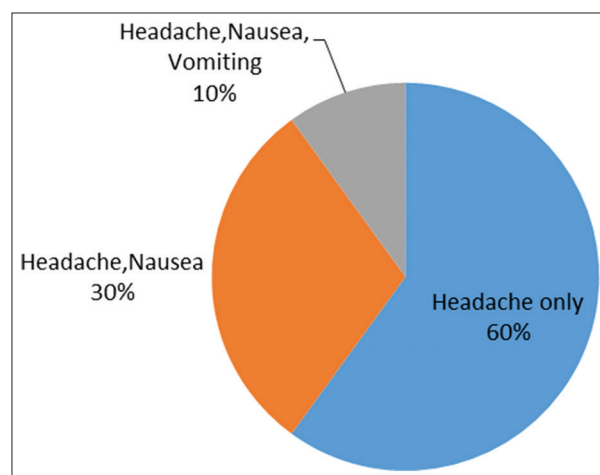


Figure 2: Presenting symptoms following lumbar drainage

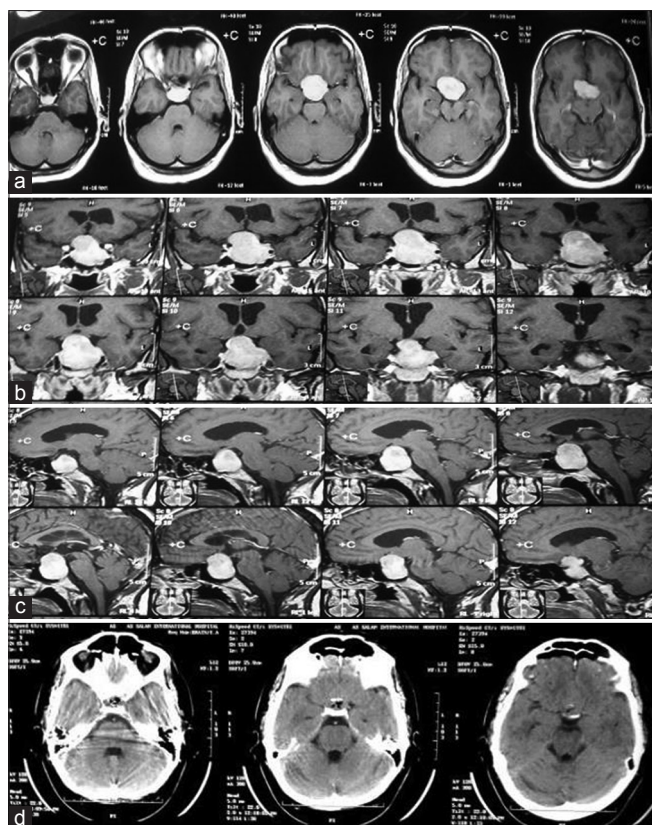


Figure 3: Preoperative magnetic resonance imaging and postoperative computed tomography brain findings in Case 1. (a) Magnetic resonance imaging brain T1 axial cut with contrast shows sellar suprasellar mass. (b) Magnetic resonance imaging brain T1 coronal cut with contrast shows sellar suprasellar mass. (c) Magnetic resonance imaging brain T1 sagittal cuts with contrast shows sellar suprasellar mass. (d) Computed tomography brain coronal cuts postoperative shows removal of mass and minimal pneumocephalus

leakage from CSF rhinorrhea. Moreover, neither death nor infection was noted in their study.^[11] Furthermore, Mansy *et al.* concluded that LD markedly reduces the incidence of postoperative leakage, and it solves the problem of a persisting postoperative CSF leak.^[13] Selective usage of CLD is a reasonable and safe method to gain time and it possibly facilitates the recovery of absorption capacity following endoscopic third ventriculostomy.^[14]

LD insertion was placed postoperatively in 16 of our patients, while 4 patients were placed the insertion preoperatively. Most studies did not specify when the lumbar drain was placed; however, Ransom *et al.* placed the lumbar drain prospectively during the time of surgery and Mehta and Oldfield reported the placement of the lumbar drain before surgery after patients' intubation; both reported no neurological deficits related to the lumbar drain insertion.^[15,16] On the other hand, some authors never used lumbar drains for the purpose of preventing or anticipating CSF leak, and only placed the lumbar drain postoperatively if a CSF leak is evident. However, others placed the lumbar drain preoperatively under the assumption that the drain would assist in delivering the suprasellar portions of

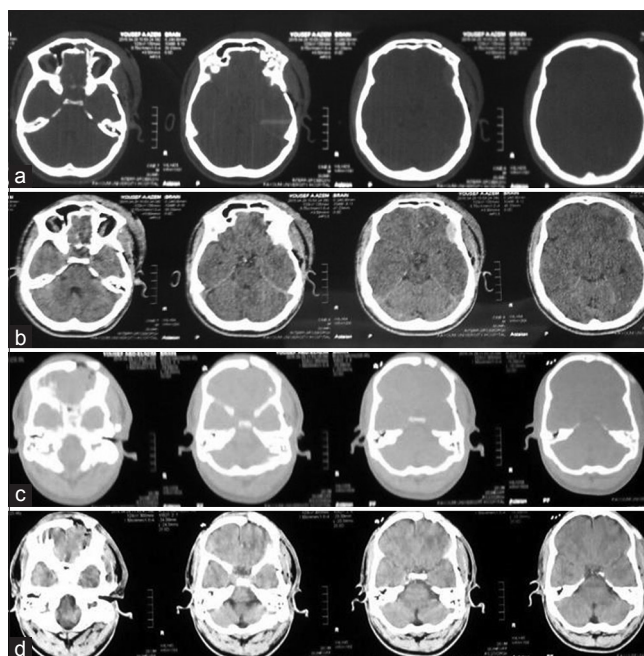


Figure 4: Pre- and postoperative computed tomography brain soft tissue and bone window findings in Case 2. (a) Preoperative computed tomography brain bone window axial cut shows frontal sinus fracture affecting posterior walls and fissures of the left temporal bone and left orbital walls. (b) Preoperative computed tomography brain soft tissue axial cut shows left frontal extradural hematoma. (c) Postoperative computed tomography brain bone window axial cut shows minimal pneumocephalus at the site of frontal sinus repair. (d) Postoperative computed tomography brain soft tissue axial cut shows minimal pneumocephalus at the site of frontal sinus repair

a macroadenoma. As of yet, there is no consensus on the timing of when a lumbar drain should be placed.^[17]

Based on the type of repair performed to resolve the leaking CSF in our population, four patients underwent primary dura repair, while the rest were subjected to the use of grafts either from fat, muscle, and fascia or pericranium. The literature supports the successful management of CSF leakage using perioperative CLD solely or in association with other methods such as primary dural repair, usage of grafts from fat, muscle, fascia or pericranium, fibrin glue, gelatinous foam, blood patches, postoperative posture, drugs, and finally, reexploration and repair.^[18-20]

In the present study, headache was the most commonly anticipated complication of CLD, which occurred in all of our patients, whereas six patients complained from headache and nausea and two patients complained from headache in addition to nausea and vomiting. However, only one case with surgical site infection was noted, while no death occurred in our population. Postoperative imaging revealed minimal intracranial air in a number of cases of our population with no evidence of intracranial hemorrhage. Some of the most serious complications reported in the literature are meningitis, pneumocephalus, and transtentorial herniation. Minimal pneumocephalus was noted in our patients. Pneumocephalus and transtentorial might happen in relation to alterations in drainage flow

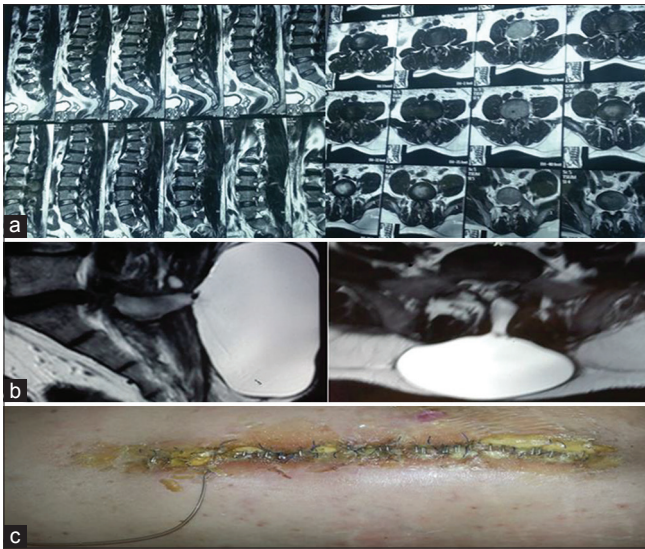


Figure 5: Magnetic resonance imaging lumbosacral findings and postoperative surgical wound of Case 3. (a) Magnetic resonance imaging lumbosacral spine T2 sagittal and axial cuts showing lumbar canal stenosis from L2 to L5. (b) Magnified magnetic resonance imaging lumbosacral spine T2 sagittal and axial cuts showing pseudomeningocele and its communication with the dura. (c) Postoperative surgical wound with lumbar drain inserted

rate. Graft *et al.* reported that three cases had neurological deterioration postoperatively which was caused by tension pneumocephalus. They were treated with CLD to alleviate the CSF fistula. Overdrainage in these patients was the main reason behind the developing pneumocephalus. They proposed that a combination of head elevation as well as spinal drainage were the underlying mechanisms, introducing a negative gradient between atmospheric pressure and intracranial pressure. As a result of that pressure gradient, a siphon effect was produced, which led to air coming into the intracranial space through the unseen fistula.^[7] Another report concluded CLD in an anesthetized patient before surgery was a safe procedure, as no neurological deficits attributable to the insertion of the lumbar drain were noted. Spinal headache was the most common presentation, where the usage of epidural blood patch helped relieved the symptoms.^[21]

Conclusion

Our findings indicate that CLD is a safe method with minimal morbidity as no life-threatening complications were encountered. Appropriate monitoring of the amount of CSF drainage in hours and days is essential to facilitate early recognition of complications. In conclusion, our findings suggest that CLD is a simple, safe, and efficacious system in managing CSF leakage at operative sites, CSF rhinorrhea, and CSF otorrhea of various etiologies.

Declaration of patient consent

The authors certify that they have obtained all appropriate patient consent forms. In the form, the patients have given their consent for their images and other clinical information

to be reported in the journal. The patients understand that their names and initials will not be published and due efforts will be made to conceal their identity, but anonymity cannot be guaranteed.

Financial support and sponsorship

Nil.

Conflicts of interest

There are no conflicts of interest.

References

- Coiteiro D, Távora L, Antunes JL. Spontaneous cerebrospinal fluid fistula through the clivus: Report of two cases. *Neurosurgery* 1995;37:826-8.
- Kitchel SH, Eismont FJ, Green BA. Closed subarachnoid drainage for management of cerebrospinal fluid leakage after an operation on the spine. *J Bone Joint Surg Am* 1989;71:984-7.
- McCallum J, Maroon JC, Jannetta PJ. Treatment of postoperative cerebrospinal fluid fistulas by subarachnoid drainage. *J Neurosurg* 1975;42:434-7.
- Shapiro SA, Scully T. Closed continuous drainage of cerebrospinal fluid via a lumbar subarachnoid catheter for treatment or prevention of cranial/spinal cerebrospinal fluid fistula. *Neurosurgery* 1992;30:241-5.
- Friedman JA, Ebersold MJ, Quast LM. Post-traumatic cerebrospinal fluid leakage. *World J Surg* 2001;25:1062-6.
- Bell RB, Dierks EJ, Homer L, Potter BE. Management of cerebrospinal fluid leak associated with craniomaxillofacial trauma. *J Oral Maxillofac Surg* 2004;62:676-84.
- Graf CJ, Gross CE, Beck DW. Complications of spinal drainage in the management of cerebrospinal fluid fistula. *J Neurosurg* 1981;54:392-5.
- Wahlig JB, Welch WC, Kang JD, Jungreis CA. Cervical intrathecal catheter placement for cerebrospinal fluid drainage: Technical case report. *Neurosurgery* 1999;44:419-21.
- Dalgic A, Okay HO, Gezici AR, Daglioglu E, Akdag R, Ergungor MF. An effective and less invasive treatment of post-traumatic cerebrospinal fluid fistula: Closed lumbar drainage system. *Minim Invasive Neurosurg* 2008;51:154-7.
- Jung H, Shah A, Ajlan A. Perioperative cerebrospinal fluid diversion utilizing lumbar drains in transsphenoidal surgery. *J Neurol Disord* 2014;2:150. Available from: <https://www.omicsonline.org/pdfdownload.php?download=open-access/perioperative-cerebrospinal-fluid-diversion-utilizing-lumbar-drains-in-transsphenoidal-surgery-2329-6895.1000150.pdf>.
- Huang CI, Huang MC, Chen IH, Lee LS. Diverse applications of continuous lumbar drainage of cerebrospinal fluid in neurosurgical patients. *Ann Acad Med Singapore* 1993;22:456-8.
- Roland PS, Marple BF, Meyerhoff WL, Mickey B. Complications of lumbar spinal fluid drainage. *Otolaryngol Head Neck Surg* 1992;107:564-9.
- Mansy A, Kersh A, Eissa E. Role of the external lumbar drain in management of CSF leak during or after transsphenoidal surgery. *Egypt J Neurol Psychiatry Neurosurg* 2010;47:483-8.
- Ozisik P, Roth J, Beni-Adani L, Constantini S. Continuous spinal drain following endoscopic third ventriculostomy: A proposal to change the definition of failure. *Childs Nerv Syst* 2011;27:1973-8.
- Mehta GU, Oldfield EH. Prevention of intraoperative

- cerebrospinal fluid leaks by lumbar cerebrospinal fluid drainage during surgery for pituitary macroadenomas. *J Neurosurg* 2012;116:1299-303.
16. Ransom ER, Palmer JN, Kennedy DW, Chiu AG. Assessing risk/benefit of lumbar drain use for endoscopic skull-base surgery. *Int Forum Allergy Rhinol* 2011;1:173-7.
 17. Laws ER Jr., de Los Reyes K, Rincon-Torroella J. Lumbar drains in transsphenoidal surgery. *J Neurosurg* 2013;118:480-1.
 18. Kaptain GJ, Vincent DA, Laws ER Jr. Cranial base reconstruction after transsphenoidal surgery with bioabsorbable implants. *Neurosurgery* 2001;48:232-3.
 19. Sade B, Mohr G, Frenkiel S. Management of intra-operative cerebrospinal fluid leak in transnasal transsphenoidal pituitary microsurgery: Use of post-operative lumbar drain and sellar reconstruction without fat packing. *Acta Neurochir (Wien)* 2006;148:13-8.
 20. Seiler RW, Mariani L. Sellar reconstruction with resorbable vicryl patches, gelatin foam, and fibrin glue in transsphenoidal surgery: A 10-year experience with 376 patients. *J Neurosurg* 2000;93:762-5.
 21. Grady RE, Horlocker TT, Brown RD, Maxson PM, Schroeder DR. Neurologic complications after placement of cerebrospinal fluid drainage catheters and needles in anesthetized patients: Implications for regional anesthesia. *Mayo perioperative outcomes group. Anesth Analg* 1999;88:388-92.