

Primary Multiple Intracranial Extradural Hydatid Cysts: A Rare Entity Revisited

Abstract

Human hydatid disease is caused by *Echinococcus granulosus*. Central nervous system (CNS) echinococcosis is rare with less than 4% of cases of hydatid disease have CNS involvement. Intracranial extradural hydatid cysts are rare and less than 11 cases have been reported in literature. Primary intracranial extradural multiple hydatid cysts are not reported as per our knowledge so we report probably the first case.

Keywords: Extradural, hydatid cysts, multiple, primary

Introduction

Hydatid disease in humans is caused by a tapeworm, *Echinococcus granulosus*, which forms larval cysts in the human tissue. Humans get infected through the feco-oral route. Central nervous system (CNS) echinococcosis is rare with <4% of cases of hydatid disease have CNS involvement. Intracranial hydatid disease is seen in three different forms, those are intracerebral, extracerebral, and a combined form. An extradural hydatid cyst is rare, and the exact cause is not clear. The incidence of hydatid disease varies geographically; it is much more common in South America, Australia, the Middle East, and parts of North Africa than in Europe and North America. In India, *E. granulosus* is relatively common in Southeast Rajasthan.^[1] Till date, only 11 cases of primary multiple hydatid cysts of the brain (intradural) have been reported in the literature, but extradural multiple hydatid cysts we could not find in literature, so this is probably the first one.^[2]

Case Report

A 20-year-old female patient presented to us with intermittent headache since last 1 month which was gradually increasing in intensity. There was no history of recent trauma, vomiting, convulsions, or any weakness. The patient had a history of prolonged canine contact. Neurological

examination was completely normal. Skull and chest films were normal. Magnetic resonance imaging (MRI) of the brain with contrast was done which showed T1 hypointense lesion with multiple septae; it was hyperintense on T2-weighted images. It showed a typical cartwheel appearance as seen in hepatic hydatid cyst. Pressure erosion of the adjacent bone was seen on computed tomography (CT) of the brain [Figure 1a-c]. Hence, hydatid cyst was considered as a probable diagnosis. Ultrasound of the abdomen was completely normal.

As there was a significant mass effect over the underlying brain parenchyma, the patient underwent surgical excision of lesion. Intraoperatively, multiple cysts were found completely in extradural space with pressure erosion of the skull bone at some places. Dura was completely normal with no intradural involvement. The inner table was eroded by the mass, but there was no evidence to suggest that the cyst arose from the diploic space. There was a yellow colored large mother sac with multiple daughter cysts. Complete excision of cyst was achieved; savlon wash was given [Figure 2a-d]. Postoperatively, the patient recovered well without any deficits and was discharged on the 7th postoperative day. Postoperative CT scan of the brain showed complete excision of lesion. Postoperatively, the patient was given

Hrushikesh Kharosekar,
Anuj Bhide,
Santosh Rathi¹,
Veena Sawardekar

Department of Neurosurgery,
Grant Medical College, Sir J J
Group of Hospitals, Mumbai,
¹Department of Neurology,
Criticare Super Speciality
Hospital, Thane, Maharashtra,
India

Address for correspondence:
Dr. Hrushikesh Kharosekar,
Criticare Super Speciality
Hospital, Thane, Maharashtra,
India.
E-mail: hkharsekar@gmail.com

Access this article online

Website: www.asianjns.org

DOI: 10.4103/ajns.AJNS_262_20

Quick Response Code:



This is an open access journal, and articles are distributed under the terms of the Creative Commons Attribution-NonCommercial-ShareAlike 4.0 License, which allows others to remix, tweak, and build upon the work non-commercially, as long as appropriate credit is given and the new creations are licensed under the identical terms.

For reprints contact: WKHLRPMedknow_reprints@wolterskluwer.com

How to cite this article: Kharosekar H, Bhide A, Rathi S, Sawardekar V. Primary multiple intracranial extradural hydatid cysts: A rare entity revisited. *Asian J Neurosurg* 2020;15:766-8.

Submitted: 28-May-2020 Revised: 24-Jun-2020
Accepted: 13-Jul-2020 Published: 28-Aug-2020

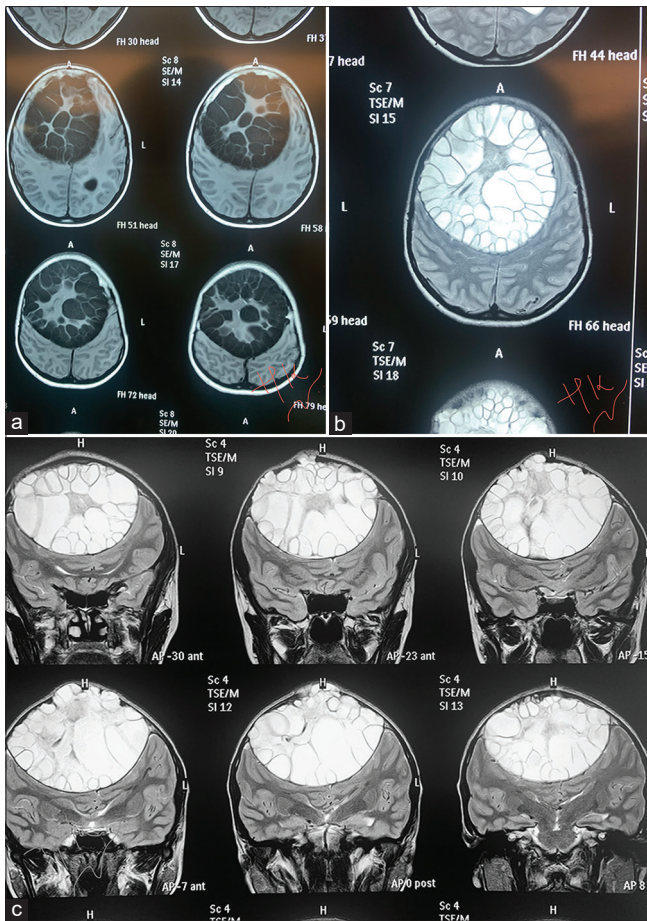


Figure 1: (a-c) Preoperative magnetic resonance imaging of the brain with contrast of the patient showing lesion. Typical cartwheel appearance

albendazole and steroids. On follow-up at 3 months, the patient was doing better with complete relief from headache and no recurrence [Figure 3].

Discussion

Human hydatid disease is caused by *E. granulosus* and *Echinococcus alveolaris*. *E. granulosus* produces cystic lesions, whereas *E. alveolaris* produces invasive, solid lesions. CNS hydatid disease is most commonly seen in children and in males. Hydatid cyst in the brain is relatively rare, seen in only 2% of cases. Brain hydatid cysts can be primary (single) or secondary (multiple). The primary cysts are fertile as they contain scolices and brood capsules, hence rupture of primary cyst can result in recurrence. The secondary multiple cysts result from spontaneous, traumatic, or surgical rupture of the primary intracranial hydatid cysts, and they lack brood capsule and scolices. The secondary intracranial hydatid cysts are therefore infertile. Primary multiple cysts are uncommon, and isolated case reports of primary multiple hydatid cysts have appeared in the literature. Nurchi *et al.* while reviewing the literature found only 11 reported cases of primary multiple hydatid cysts.^[3]

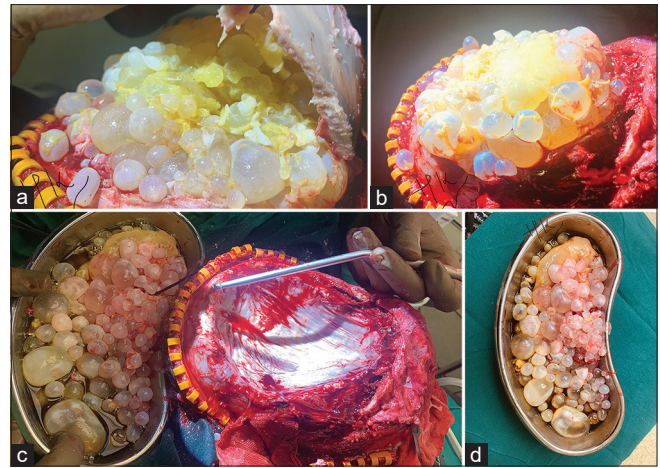


Figure 2 : (a-d) Intraoperative images showing multiple cysts. Intact dura can be seen

The most common presentation in children is with signs of raised intracranial pressure. Adults present with focal neurological deficits such as hemiparesis, hemianopia, speech disorders, or seizures depending on the location of the lesion.

Intracranial extradural hydatid cysts are very rare, and we were able to find only 12 previous cases reported in the literature till date. The exact pathogenesis of extradural echinococcosis is not clear; following postulations have been made:

1. Infestation by direct extension from the calvarium
2. Infestation by intracerebral cysts through an apparently healthy dura
3. Rarely, infestation by the extradural vessels which may carry hexacanth embryos to the extradural space.^[4]

In our case, there was no calvarial involvement; also no intracerebral lesions were seen. Samiy and Zodeh had encountered a case of extradural hydatid with normal skull films that showed erosion of the inner table during surgery. It was interpreted as a primary calvarial lesion, but the authors did not elaborate more on the relation of the cysts to the bone.^[3] Robinson claimed that extradural vessels that can carry the hexacanth embryo are few or nonexistent, so with such sparse blood supply to this region, extradural space is an extraordinary site of infestation. The only known way, however, by which the hexacanth embryo travels in the body is through the bloodstream.^[5]

The cyst is hypointense on T1-weighted and hyperintense on T2-weighted MRI. MRI also shows perilesional edema. MRI is superior in determining the exact cyst location, cystic contents, and also in surgical planning and ruling out other diagnostic possibilities.

Despite the advancements in microsurgical operative techniques, cerebral hydatid cysts still pose a challenge for the neurosurgeons as they are usually large in size at presentation; thin cyst wall and the neurological deficits are

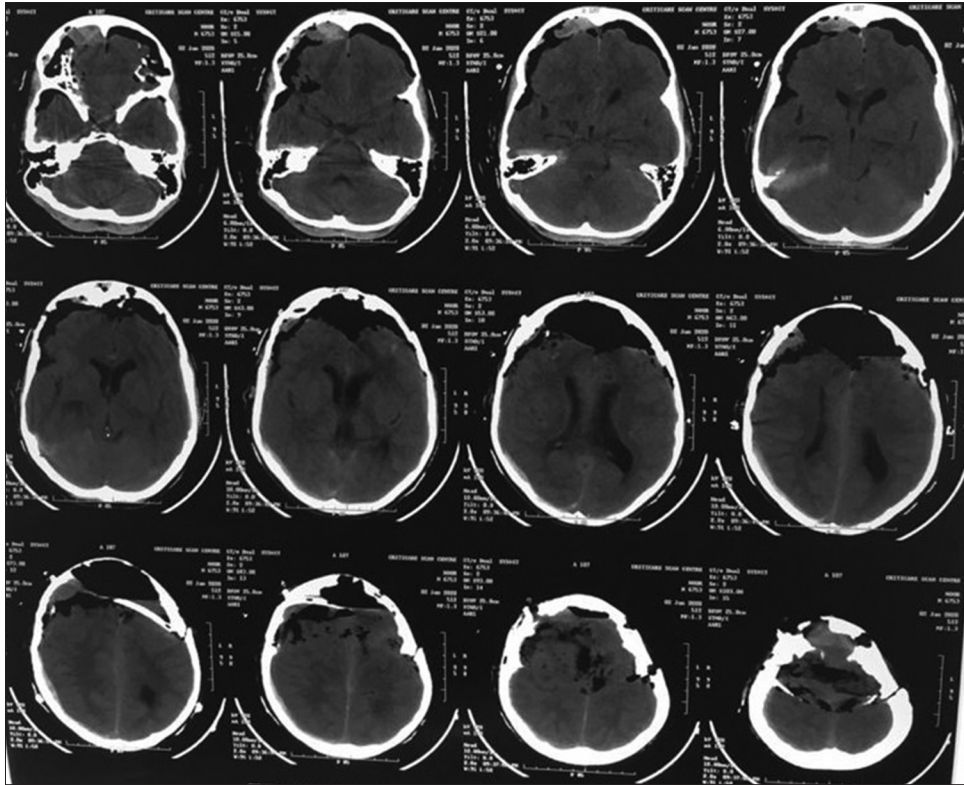


Figure 3: Postoperative computed tomography scan of the brain showing complete excision

minimal at presentation despite the location and the large size of the cyst.^[1]

Definitive treatment is complete excision of the cyst without spillage, followed by medical treatment with albendazole. It is very important to avoid rupture on cyst intraoperatively with thorough savlon wash ready at hand. Furthermore, perioperative anthelmintic treatment with albendazole is recommended for multiple cysts and is reported to be quite effective in slowing down the increase in cyst volume or even in stopping cyst growth completely.

Conclusion

A high index of suspicion is necessary to diagnose this rare lesion preoperatively and to consider it as one of the differential diagnosis. It is important as surgical removal of the intact cyst is required to prevent progressive neurologic deficit. Removal of all the cysts without intraoperative rupture with medical management postoperatively is necessary to prevent recurrence.

Declaration of patient consent

The authors certify that they have obtained all appropriate patient consent forms. In the form the patient(s) has/have given his/her/their consent for his/her/their images and

other clinical information to be reported in the journal. The patients understand that their names and initials will not be published and due efforts will be made to conceal their identity, but anonymity cannot be guaranteed.

Financial support and sponsorship

Nil.

Conflicts of interest

There are no conflicts of interest.

References

1. Gautam S, Sharma A. Intracranial hydatid cyst: A report of three cases in North-West India. *J Pediatr Neurosci* 2018;13:91-5.
2. Nurchi G, Floris F, Montaldo C, Mastio F, Peltz T, Coraddu M. Multiple cerebral hydatid disease: Case report with magnetic resonance imaging study. *Neurosurgery* 1992;30:436-8.
3. Gupta S, Desai K, Goel A. Intracranial hydatid cyst: A report of five cases and review of literature. *Neurol India* 1999;47:214-7.
4. Beşkonaklı E, Caylı S, Yalçınlar Y. Primary intracranial extradural hydatid cyst extending above and below the tentorium. *Br J Neurosurg* 1996;10:315-6.
5. Ba'assiri A, Haddad FS. Primary extradural intracranial hydatid disease: CT appearance. *AJNR Am J Neuroradiol* 1984;5:474-5.