

The Role of Combined Posterior and Anterolateral Retroperitoneal Approach in the Treatment of Posttraumatic Burst Lumbar Fractures

Abstract

Context: Combined posterior and anterolateral retroperitoneal approach is very important for the treatment of unstable burst lumbar fractures with retropulsed fragments. **Aims:** The aim of the study is to evaluate the role of combined posterior and anterolateral retroperitoneal approach in the treatment of unstable burst lumbar fractures. **Settings and Design:** This is a retrospective clinical case series study. **Patients and Methods:** This study was conducted on 41 patients with unstable lumbar burst fractures with retropulsed fragment. Frankel scale score and Denis pain score were used to evaluate the functional outcome. All patients were surgically treated using combined posterior and anterolateral retroperitoneal approach. They were followed for 1 year postoperatively. **Statistical Analysis:** Using SPSS version 21, data were presented as mean \pm standard deviation, and percentage and paired sample and Wilcoxon signed-rank tests were used for data analysis. **Results:** the functional state of all patients improved after surgery. According to the Frankel and Denis pain scores, there was a significant improvement in patients' scores postoperatively compared to preoperative ones ($P = 0.001$). Visceral manifestations were present in 16 cases (36.6%) with complete improvement postoperatively except two cases. There is a significant improvement as regards pre- and postoperative regional kyphotic angle (9.12 ± 10.03) and vertebral body height (3.14 ± 0.37). Unintended durotomy occurred in six cases treated by stitching using absorbable sutures and fat graft. Wound infection was present in two cases treated by antibiotics and daily dressing. A solid fusion was achieved in all cases. **Conclusions:** Combined posterior and anterolateral retroperitoneal approach is feasible and effective in surgical exposure and treatment of unstable burst lumbar fractures with retropulsed fragments.

Keywords: Burst lumbar fractures, posterior approach, retroperitoneal approach

Introduction

Unstable lumbar burst fractures with retropulsed fragment require surgical treatment by combined posterior and anterolateral retroperitoneal approach for different reasons: (1) spinal canal decompression to facilitate neurological recovery, (2) anterior column reconstruction and restoration of alignment, (3) prevention of progressive posttraumatic deformity, (4) early ambulation and rehabilitation due to rigid fixation, and (5) avoiding long segment fixation. Lumbar burst fractures result from vertical compression to the slightly flexed spine.^[1,2] In some instances, a rotational or shear component or some extension force may be necessary to cause the characteristic burst fracture pattern.^[3] The three-column theory as presented by Denis^[4,5] describes both the mechanism of injury and the concept of spinal stability; burst fractures

can be 2 or 3 column injuries. According to Denis, a spinal fracture is described as burst if there is compression of the anterior column, fracture of the middle column, and retropulsion of bone fragments into the spinal canal. In severe burst fractures, the pedicles spread and an associated fracture of the posterior rim usually involving the lamina may occur. The combination of a concomitant lamina fracture with a burst fracture can be linked with a dural tear and entrapped nerve roots.^[6] Hence, we aimed from the present study to evaluate the role of combined posterior and anterolateral retroperitoneal approach in the treatment of unstable burst lumbar fractures.

Patients and Methods

This study was conducted on 41 patients with lumbar burst fractures and retropulsed fragments. All were admitted and operated upon in the Department of Neurosurgery, Tanta University Hospital. All patients were

This is an open access journal, and articles are distributed under the terms of the Creative Commons Attribution-NonCommercial-ShareAlike 4.0 License, which allows others to remix, tweak, and build upon the work non-commercially, as long as appropriate credit is given and the new creations are licensed under the identical terms.

For reprints contact: reprints@medknow.com

How to cite this article: Shamhoot EA, Elkholy AR. The role of combined posterior and anterolateral retroperitoneal approach in the treatment of posttraumatic burst lumbar fractures. Asian J Neurosurg 2019;14:467-72.

Ebrahim Ahmed Shamhoot, Ahmed Rizk Elkholy

Department of Neurosurgery,
Faculty of Medicine,
Tanta University, Tanta, Egypt

Address for correspondence:
Dr. Ebrahim Ahmed Shamhoot,
Department of Neurosurgery,
Faculty of Medicine,
Tanta University, El-Geesh
Street, Tanta, Egypt.
E-mail: shamhoot2017@yahoo.
com

Access this article online

Website: www.asianjns.org

DOI: 10.4103/ajns.AJNS_262_18

Quick Response Code:



surgically treated using staged surgery. Posterior fusion with or without decompression followed after 1 week by anterolateral fusion.

Preoperative evaluation

All patients were evaluated and subjected to complete clinical history and examination. General and neurological examination was performed. It included motor, sensory, visceral, and local examination. The preoperative pain and functional state were determined using Denis pain scale^[5] and Frankel scale score.^[7] Routine laboratory investigations and radiological assessment including computed tomography (CT) and magnetic resonance imaging lumbar spine were done for all cases. Indications for combined approach were vertebral body height loss more than 50%, kyphotic angle more than 33°, canal encroachment more than 50%, and posterior ligamentous complex injury. As regard thoracolumbar injury classification score; all patients were classified more than five points and required surgical intervention.^[8]

Operative technique

Posterior approach

All patients were surgically treated with posterior segmental fixation and posterolateral fusion using iliac crest bone graft performing pedicle screws' fixation one level above and one level below the fracture site with or without laminectomy.

Anterolateral approach

Patients underwent anterolateral retroperitoneal approach with single-level corpectomy decompression and reduction. The skin incision was done over the 11th rib and resected it from the angle of the rib to the junction of the rib and costal cartilage, leaving the ribbed intact. Twelfth rib was not resected in most patients because it is too small to obscure the operative field; complete discectomy was done caudad and cephalad to the fracture level. A large rongeur and drill were used to remove the vertebral body and retropulsed fragment. After corpectomy, we inserted the titanium mesh cage packed with corrected vertebral body and rib. Postoperatively, all patients were managed in a total contact thoracolumbar sacral orthosis for 3 months.

Postoperative evaluation

Clinical follow-up was done every 3 months for 1-year duration using Denis pain scale and Frankel scale score to evaluate the functional outcome postoperatively. Radiological follow-up including plain CT lumbar spine and X-ray was done in all cases within 72 h after surgery and after 1 year to measure vertebral body height and regional kyphosis and assess construct stability and fusion.

Statistical analysis

Statistical analysis of data was performed with SPSS software version 21 (IBM Corp., Armonk, NY, United States of America). Data were presented as

mean \pm standard deviation, and percentage and paired sample and Wilcoxon signed-rank tests were used for comparing pre- and postoperative data of patients. $P < 0.05$ was considered as statistically significant.

Results

This study included 41 patients with burst lumbar fractures with retropulsed fragments; they were operated on and followed up for 1 year postoperatively. Twenty-five (61%) were males while 16 were females (39%) with a male-to-female ratio of 1.6:1. The age of the patients ranged between 16 and 44 years with a mean age of 27.58 ± 8.89 years [Table 1].

All patients were presented by burst lumbar fractures with retropulsed fragments. The mode of trauma was motor vehicle accident (56.1%) and falling from height (43.9%). The duration of symptoms ranged between 1 and 3 days with a mean duration of 1.53 ± 0.59 days. Low back pain was the most common presenting symptom occurring in all cases (100%) followed by weakness in both lower limbs in 25 patients (61%) and visceral manifestation in 16 cases (36.6%) [Table 1].

Examination of patients revealed lower limb weakness in 25 patients (61%), visceral manifestation in 16 cases (36.6%), and intact in 16 cases (39%). Preoperative evaluation of patients according to the Frankel scale score revealed that Frankel E was present in 16 patients (39%), Frankel B in 7 patients (17.1%), and Frankel C in 18 patients (43.9%). Preoperative evaluation of pain according to the Denis pain score revealed that P3 (moderate) was present in 4 patients (9.8), P4 (moderate to severe) in 17 patients (41.5), and P5 (severe) in 20 patients (48.8). The most common level of injury was L4 in 16 patients (39%) followed by L3 in 10 patients (24.4%) [Table 1].

Table 1: Demographic data of the studied patients

Parameters	Patients (n=41), n (%)
Age (years)	27.59 \pm 8.89 (16-44)
Sex	
Male	25 (61)
Female	16 (39)
Mode of trauma	
Motor vehicle accident	23 (56.1)
Falling from height	18 (43.9)
Duration of symptoms (days)	1.54 \pm 0.60 (1-3)
Spinal level of injury	
L1	7 (17.1)
L2	7 (17.1)
L3	10 (24.4)
L4	16 (39.0)
L5	1 (2.4)
Burst lumbar fracture with retropulsed fragment complete peroneal nerve degeneration	41 (100)

All patients were operated using combined posterior and anterolateral retroperitoneal approach. All cases were operated for posterior fusion with or without decompression followed after 1 week by anterolateral fusion.

As regards Frankel scale score and Denis pain score, the functional state of all patients improved after surgery and during our period of follow-up (1 year). Frankel scale score revealed that Frankel E was present in 16 patients (39%), Frankel B in 7 patient (17.1%), and Frankel C in 18 patients (43.9%). Moreover, statistical analysis revealed that there was a significant improvement in grades of patients postoperatively compared to preoperative grades ($P < 0.05$) [Table 2].

Denis pain score revealed that P3 (moderate) was present in 4 patients (9.8%), P4 (moderate to severe) in 17 patients (41.5%), and P5 (severe) in 20 patients (48.85%). Statistical analysis revealed that there was a significant improvement in Denis pain score among patients of the study postoperatively compared to preoperative scores ($P < 0.05$) [Table 2].

The visceral manifestation was present in 16 cases (36.6%). There was an improvement in all cases except two cases [Table 2].

There was a significant improvement in the preoperative ($25.61^\circ \pm 10.54^\circ$) and postoperative ($16.49^\circ \pm 0.93^\circ$) kyphotic angles in the studied patients ($P < 0.05$) and also with a significant improvement in the preoperative (1.53 ± 0.21 cm) and postoperative (4.68 ± 0.39 cm) vertebral heights ($P < 0.05$) [Table 3].

Unintended durotomy was present in six cases treated by stitching using absorbable sutures and fat graft. Wound infection was present in two cases treated by antibiotics and daily dressing. A solid fusion was achieved in all cases [Table 4]. Pre and post-operative radiological data of some studied cases are shown in Figures 1-8.

Discussion

Indications of combined posterior and anterolateral retroperitoneal approaches in this study include (1) complete posterior ligamentous complex injury, (2) retropulsed fragment $>50\%$, (3) vertebral body height loss $>50\%$, and (4) regional kyphotic angle $>33^\circ$. The advantages of combined surgical approaches are anterior column reconstruction and restoration of alignment and stabilization of the injured posterior ligamentous complex.^[9]

Few researchers tried to compare anterior versus posterior approaches for thoracolumbar fractures. Gertzbein concluded that the bladder function regained following anterior compared to posterior approaches. Hitchon *et al.* reported that deformity was corrected when the anterior approach was used. Others also showed that both approaches are associated with statistically

Table 2: Pre- and 1-year postoperative Denis pain score, Frankel grading system, and visceral affection of the studied patients

Parameters	Preoperative, n (%)	1-year postoperative, n (%)	P
Denis pain score			
P1	0	33 (80.5)	0.001
P2	0	8 (19.5)	
P3	4 (9.8)	0	
P4	17 (41.55)	0	
P5	20 (48.8)	0	
Frankel grading system			
Fa	0	0	0.001
Fb	7 (17.1)	0	
Fc	18 (43.9)	0	
Fd	0	4 (9.8)	
Fe	16 (39.0)	37 (90.2)	
Visceral affection			
No	26 (63.4)	39 (95.1)	0.002
Yes	15 (36.6)	2 (4.9)	

Table 3: Pre- and postoperative kyphotic angle and vertebral height

	Mean \pm SD	Difference between pre- and postoperative	P
Preoperative kyphotic angle	25.61 \pm 10.54	9.12 \pm 10.03	0.001
Postoperative kyphotic angle	16.49 \pm 0.93		
Preoperative vertebral height	1.53 \pm 0.21	-3.14 \pm 0.37	0.001
Postoperative vertebral height	4.68 \pm 0.39		

SD - Standard deviation

Table 4: Postoperative outcomes

Outcomes	n (%)
No complications	33 (80.5)
Durotomy	6 (14.6)
Wound infection	2 (4.9)

significant results. In general, although clinical outcome may be similar, the anterior approach for thoracolumbar burst fractures may present fewer complications and need for additional surgery compared to the posterior approaches.^[10,11]

Our study included 41 patients with burst lumbar fractures with retropulsed fragments. Males were more than females. The main presentation was low back pain and weakness of lower limbs with visceral manifestation. They were operated by staged surgery to avoid severe blood loss. Posterior fusion with or without decompression followed after 1 week by anterior decompression and reconstruction by titanium mesh. Sin *et al.*'s study

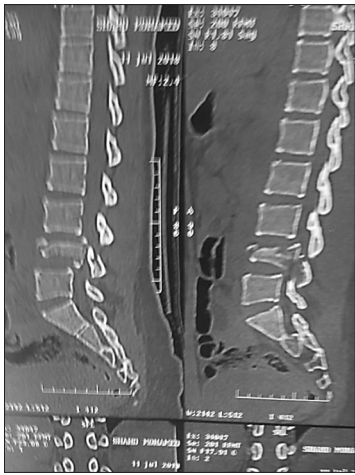


Figure 1: Sagittal computed tomography showing L4 burst fracture

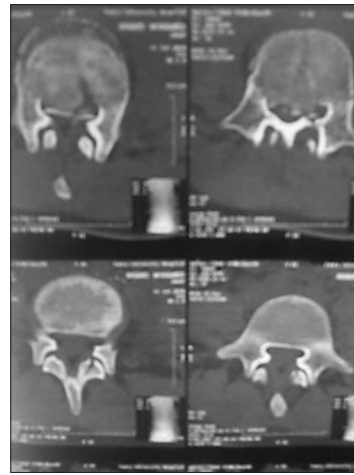


Figure 2: Axial computed tomography showing L4 burst fracture with retropulsed fragment

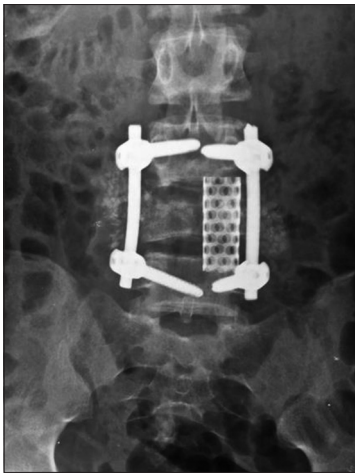


Figure 3: Postoperative anteroposterior X-ray showing posterior fusion by rod and screws, anterior fusion by titanium mesh cage

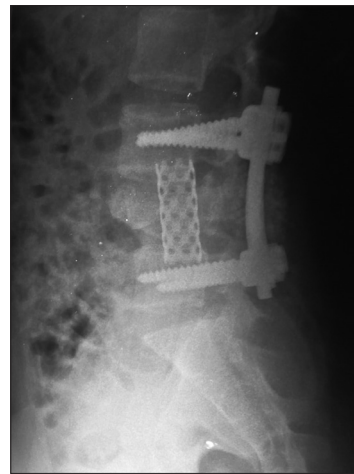


Figure 4: Postoperative lateral X-ray showing posterior fusion by rod and screws, anterior fusion by titanium mesh cage

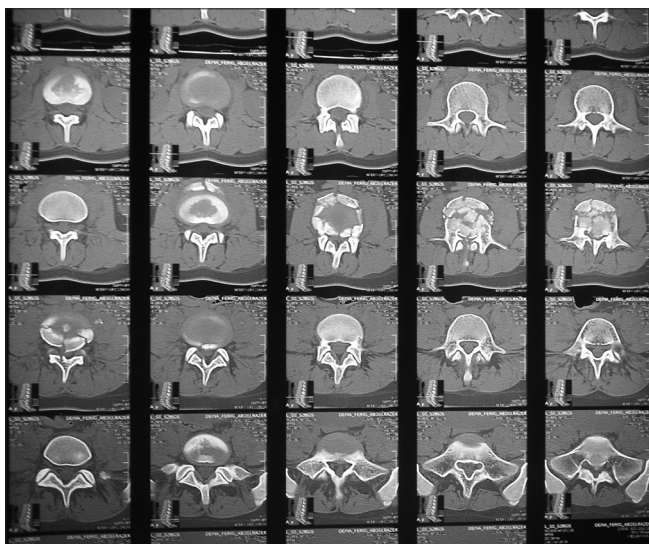


Figure 5: Sagittal computed tomography showing L4 burst fracture

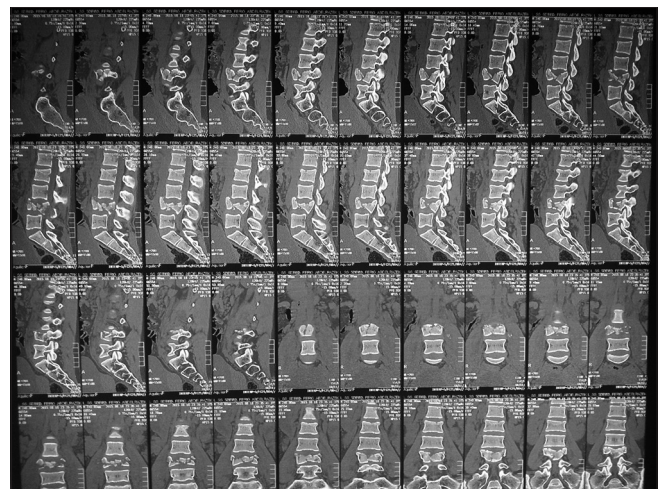

Figure 6: Axial computed tomography showing L4 burst fracture with retropulsed fragment

operated on 111 patients. Twenty-five patients operated by combined approach and 86 patients underwent posterior

decompression with fusion. The indication for combined approach of their study was as follows: (1) vertebral

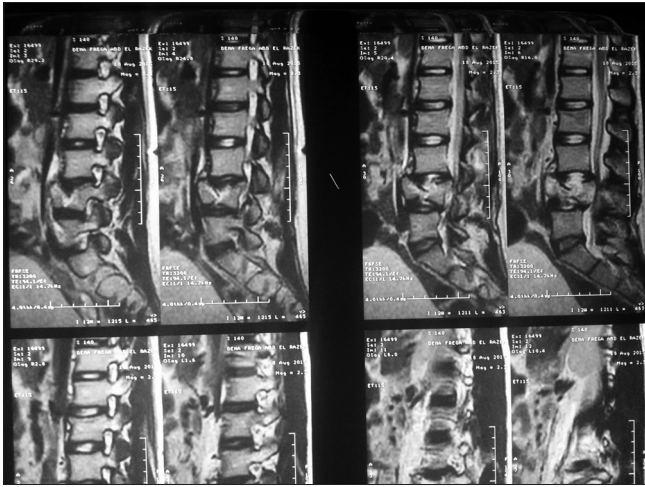


Figure 7: T2 magnetic resonance imaging showing burst L4 fracture with intervertebral cleft filled with blood and injured disrupted PLL complex

body height >50%, (2) severe canal compromise, and (3) kyphotic angle >33°^[12] and this agrees with our study. They concluded that posterior fusion combined with anterolateral fusion for unstable thoracolumbar burst fractures has many advantages including kyphosis correction, canal decompression, spinal stabilization, and less liability for additional surgery. Been and Bouma^[2] reported the results of combined anterior and posterior stabilization surgery for unstable thoracolumbar burst fractures. The improvement of the kyphotic correction between the combined AP approach (3.3 ± 7.7) and the posterior fusion only ($4.1 \pm 12.4^\circ$) approach was significantly greater in the combined surgery; this agrees with our finding as there is improvement of kyphotic angle in our series (9.12 ± 10.03).

As regards Sin *et al.*'s study,^[12] they reported that in 360° fusion group, staged surgery was done. Posterior fusion with or without fusion was followed by anterolateral fusion after 1 week. They preferred to do posterior fusion first because of useful kyphotic angle correction at prone position that maintains stabilization and spinal canal decompression. This agrees with our study. Graillon *et al.*^[13] did both approach simultaneously to avoid anesthetic risk and hasten patient recovery to reduce care costs. Moreover, they were familiar with retroperitoneal approach.

Functional outcome of our study was assessed by Frankel scale score and Denis pain score. Frankel scale score revealed that Frankel E was present in 16 patients (39%), Frankel B in 7 patients (17.1%), and Frankel C in 18 patients (43.9%). Moreover, statistical analysis revealed that there was a significant improvement in grades of patients postoperatively compared to preoperative grades and improvement of kyphotic angle. Denis pain score revealed that P3 (moderate) was present in 4 patients (9.8%), P4 (moderate to severe) in 17 patients (41.5%), and P5 (severe) in 20 patients (48.8%). Statistical analysis revealed that there was a significant improvement in Denis

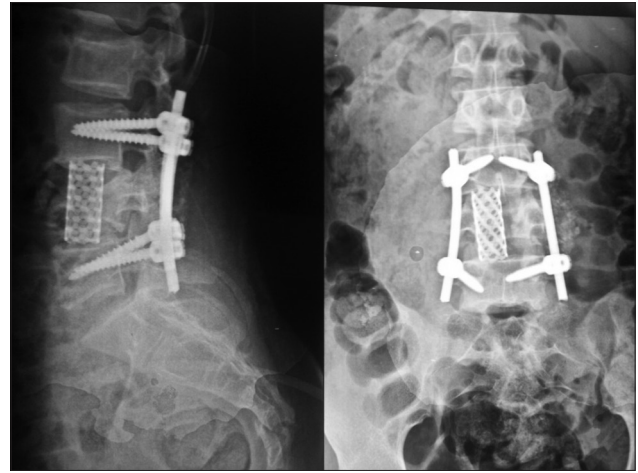


Figure 8: Postoperative X-ray showing posterior fusion by screws and anterior fusion by titanium mesh cage

pain score among patients of the study postoperatively compared to preoperative scores. Esses *et al.*^[14] did a study of 40 patients who underwent anterior decompression with posterior transpedicular distraction. They found significant improvement as regards Frankel grade or kyphosis correction, and canal decompression was substantially greater after completion of the anterior operation. Pain relief can occur by stabilization and fusion rather than deformity correction. This is best achieved by combined approach. Malcolm *et al.* reviewed 48 patients and reported that anterior and posterior reconstruction had no failures of fusion; but with isolated anterior correction, failure rate was 50%.

Samudrala *et al.*^[15] concluded that every spine surgeon should be aware with the complex regional anatomy of retroperitoneal approach. Some precautions advised by Samudrala for complication avoidance during retroperitoneal technique: (1) ureter should be mobilized with the peritoneum during exposure, (2) gentle dissection of sympathetic plexus to avoid injury, (3) flex the hip to relax psoas muscle for easy mobilization to avoid injury to lumbosacral plexus, and (4) avoid ligation of segmental arteries close to aorta for fear of its retraction beneath the aorta.

Some authors preferred to do posterior stand-alone corpectomy to avoid second anterior approach, but they found that; the risk of spinal nerve root injury was very high.^[13] Furthermore, increased risk of infection and bleeding is due to long operative time. In our study, the adverse effects of anterior approach were mild and treated. In our study, six cases of durotomy happened; four of them were anterior due to retropulsed fragment treated by fat graft and gelfoam and the other two cases were posterior unintended durotomy, and treated by stitching and fat graft. There were two cases of wound infection treated by antibiotics and daily dressing.

Study limitations

The limitations of the present study are its retrospective nature, small number of patients, and short follow-up time.

Conclusions

Combined posterior and anterolateral retroperitoneal approach is feasible and effective in surgical exposure and treatment of unstable lumbar burst fractures with retropulsed fragment. In the present study, staged 360° fusion is favorable approach than posterior fixation in terms of kyphotic angle correction, interbody height, fusion level, and postoperative pain for thoracolumbar burst fractures.

Financial support and sponsorship

Nil.

Conflicts of interest

There are no conflicts of interest.

References

- Sasso RC, Renkens K, Hanson D, Reilly T, McGuire RA Jr, Best NM, *et al.* Unstable thoracolumbar burst fractures: Anterior-only versus short-segment posterior fixation. *J Spinal Disord Tech* 2006;19:242-8.
- Been HD, Bouma GJ. Comparison of two types of surgery for thoraco-lumbar burst fractures: Combined anterior and posterior stabilisation vs. posterior instrumentation only. *Acta Neurochir (Wien)* 1999;141:349-57.
- Aydinli U, Karaeminogullari O, Tışkaya K, Oztürk C. Dural tears in lumbar burst fractures with greenstick lamina fractures. *Spine (Phila Pa 1976)* 2001;26:E410-5.
- Denis F. The three column spine and its significance in the classification of acute thoracolumbar spinal injuries. *Spine (Phila Pa 1976)* 1983;8:817-31.
- Denis F. Thoracolumbar spine trauma. In: Moes's Textbook of Scoliosis and Other Spinal Deformities. 3rd ed. Philadelphia: W.B. Saunders; 1995. p. 577-89.
- Enis F. Spinal instability as defined by the three column spine concept in acute spinal trauma. *Clin Orthop* 1984;189:65-76.
- Frankel HL, Hancock DO, Hyslop G, Melzak J, Michaelis LS, Ungar GH, *et al.* The value of postural reduction in the initial management of closed injuries of the spine with paraplegia and tetraplegia. I. Paraplegia 1969;7:179-92.
- Rihn JA, Anderson DT, Harris E, Lawrence J, Jonsson H, Wilsey J, *et al.* A review of the TLICS system: A novel, user-friendly thoracolumbar trauma classification system. *Acta Orthop* 2008;79:461-6.
- Wilke HJ, Kemmerich V, Claes LE, Arand M. Combined anteroposterior spinal fixation provides superior stabilisation to a single anterior or posterior procedure. *J Bone Joint Surg Br* 2001;83:609-17.
- Gertzbein SD. Scoliosis research society. Multicenter spine fracture study. *Spine (Phila Pa 1976)* 1992;17:528-40.
- Hitchon PW, Torner J, Eichholz KM, Beeler SN. Comparison of anterolateral and posterior approaches in the management of thoracolumbar burst fractures. *J Neurosurg Spine* 2006;5:117-25.
- Sin E, Kim H, Lee C, Ha H, Jung C. Results of combined 360° fusion versus posterior fixation alone for thoracolumbar burst fractures. *Korean J Neurotrauma* 2013;9:52-6.
- Graillon T, Rakotozanany P, Blondel B, Adetchessi T, Dufour H, Fuentes S, *et al.* Circumferential management of unstable thoracolumbar fractures using an anterior expandable cage, as an alternative to an iliac crest graft, combined with a posterior screw fixation: Results of a series of 85 patients. *Neurosurg Focus* 2014;37:E10.
- Esses SI, Botsford DJ, Kostuik JP. Evaluation of surgical treatment for burst fractures. *Spine (Phila Pa 1976)* 1990;15:667-73.
- Samudrala S, Khoo LT, Rhim SC, Fessler RG. Complications during anterior surgery of the lumbar spine: An anatomically based study and review. *Neurosurg Focus* 1999;7:e9.