

Cerebral Phaeohyphomycosis with Onychomycosis: Case Report and Review of Literature

Abstract

The term phaeohyphomycosis (PHM) means dark-pigmented fungal hyphae. Cerebral PHM (CPHM) with onychomycosis is extremely rare; very few have been reported so far. The authors report a case of CPHM with onychomycosis in a 37-year-old male from a rural background in Haryana, India, with involvement of the left frontal lobe. The mass was resected and biopsy was sent for histopathological examination. He was given antifungal drugs in the postoperative period. The patient responded very well to the treatment, and there were no signs of recurrence at the 6-month follow-up visit. The clinical features, imaging and histopathological investigations, and management of this rare entity are discussed, and the available literature is also reviewed.

Keywords: Cerebral phaeohyphomycosis, fungal, onychomycosis

**Ravishankar S. Goel,
Sachin Gupta,
Vikram Dua,
Ranjan Kumar¹**

Departments of Neurosurgery and ¹Pathology, QRG Central Hospital and Research Centre, Faridabad, Haryana, India

Introduction

CPHM with onychomycosis is extremely rare. Authors report a case and discuss treatment.

Case Report

History and examination

A 37-year-old male, farmer presented with forgetfulness and altered behavior for 3 months. There is a history of blackish discoloration of all nails 1 year back, which improved after 3 months of medical treatment. On examination, his right thumb's nail was black and irregular.

Routine laboratory investigations were within normal limits, and Western blot test was negative for HIV. Noncontrast computerized tomography (NCCT) scan chest and NCCT scan par nasal sinus were normal. NCCT head revealed ill-defined hyperdense lesion in the left frontal region [Figure 1a]. Contrast-enhanced magnetic resonance imaging (MRI) of his brain revealed large ill-defined gray-white area of altered signal intensity involving left frontal region [Figure 1b] with involvement of left basal ganglia and anterior part of the corpus callosum showed T2-weighted, fluid-attenuated inversion recovery (FLAIR) hyperintense signal

with no significant restricted diffusion. Lesion demonstrated intense heterogeneous enhancement as postcontrast T1-weighted image. No perifocal edema is noted.

The patient underwent surgery for resection and biopsy of the lesion.

Operation

Craniotomy was done. Dura mater was incised. Intraoperatively, a blackish, ill-defined lesion was noted invading the cerebral tissue. The lesion was infiltrating the cerebral tissue. Resection of the lesion was done. Immediate and delayed postoperative periods were uneventful.

Histopathological examination

On gross examination, the biopsy comprised of blackish tissue admixed with pieces of gray-white soft tissue. On microscopic examination, the necrotic debris, spore, and septate-pigmented and branching hyphae with giant cell [Figure 2] were noted. Fontana Masson stain confirmed the presence of dematiaceous hyphae. The gross and microscopic findings of the lesion we describe are characteristic features of cerebral phaeohyphomycosis (CPHM). Potassium hydroxide staining and fungal culture were not done as fungal etiology was not suspected pre- and intra-operatively.

The patient was started on antifungal drug voriconazole after histopathology reports.

This is an open access journal, and articles are distributed under the terms of the Creative Commons Attribution-NonCommercial-ShareAlike 4.0 License, which allows others to remix, tweak, and build upon the work non-commercially, as long as appropriate credit is given and the new creations are licensed under the identical terms.

For reprints contact: reprints@medknow.com

How to cite this article: Goel RS, Gupta S, Dua V, Kumar R. Cerebral phaeohyphomycosis with onychomycosis: Case report and review of literature. *Asian J Neurosurg* 2019;14:575-7.

Address for correspondence:

*Dr. Ravishankar S. Goel,
Department of Neurosurgery,
QRG Central Hospital
and Research Centre,
Faridabad, Haryana, India.
E-mail: docravishankar@yahoo.
co.in*

Access this article online

Website: www.asianjns.org

DOI: 10.4103/ajns.AJNS_259_18

Quick Response Code:



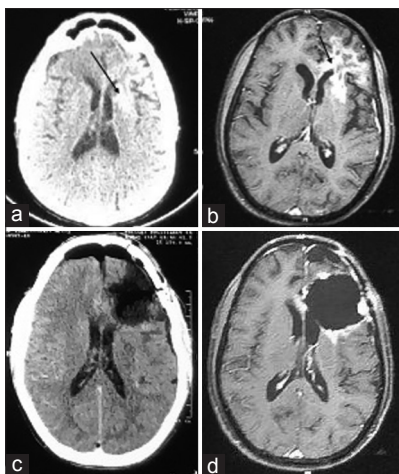


Figure 1: Radiological imaging (a) preoperative noncontrast computerized tomography head showing irregular hyperdense lesion (black arrow) seen in left frontal region; (b) preoperative magnetic resonance imaging (fluid-attenuated inversion recovery) of the brain (axial section) showing irregular lesion (black arrow) seen in the left frontal region. (c) Postoperative (day 1) contrast-enhanced computerized tomography scan of the brain (axial section) showing postoperative cavity with substance defect; (d) postoperative (3 months) magnetic resonance imaging (contrast enhanced T1 image) of the brain (axial section) showing near-total nonvisualization of lesion

On 6 months follow-up, the patient has neither nail discoloration nor any neurological deficits.

Postoperative contrast-enhanced computerized tomography scan head (at day 1) revealed postoperative cavity with substance defect [Figure 1c].

Postoperative contrast MRI brain (at 3 months) revealed large postoperative cavity with substance defect and perilesional gliosis and hemosiderin staining in the left frontal region with peripheral nodular shaggy enhancement, likely due to postoperative granulation tissue. There is near-total nonvisualization of the left frontal lesion [Figure 1d].

Discussion

Ajello *et al.* coined the term phaeohyphomycosis (PHM) in 1974 to describe cutaneous, subcutaneous, and systemic infection caused by hyphomycetous fungi, which develop as dematiaceous, septated hyphae in the host tissue.^[1] The presence of melanin in the fungal cell walls gives a dark color to the hyphae.^[2] Melanin is considered a major virulence factor^[2] as melanin provides advantage in evading host defense and crossing the blood–brain barrier by binding to hydrolytic enzymes.^[3] Such fungi are soil inhabitant, a true pathogen that are known for their neurotrophism.

The neurotrophic fungi are often geographically restricted, such as *Rhinocladiella mackenziei* occurring in the Middle East and *Cladophialophora bantiana* mainly in India.^[2] Although most infections with *Exophiala dermatitidis* are reported from East Asia, the fungus is encountered worldwide.^[2] CPHM commonly occurs in the second and

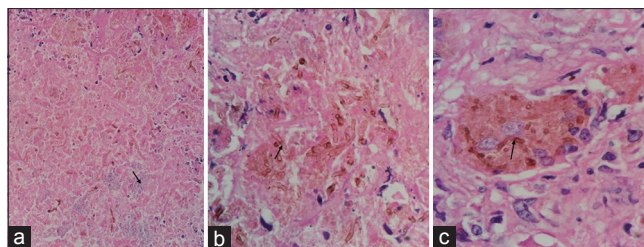


Figure 2: Photomicrographs showing (a) light blue-colored round spores (black arrow) (H and E, $\times 40$); (b) brown-pigmented fungal hyphae (black arrow) (H and E, $\times 100$); (c) fungal hyphae (black arrow) in giant cell (H and E, $\times 100$)

third decades of life with male predominance, except *R. mackenziei* which affects adults with a median age of 62 years without male predominance.^[4] The occurrence of CPHM irrelevant to immune status of host is its most unique characteristic.^[3] In this case, patient was 37 years old, male, and immunocompetent.

Central nervous system (CNS) seeding may occur due to hematogenous dissemination^[2,3] of inhaled spores or accidental skin inoculation^[3] as well as direct extension from adjacent paranasal sinuses or ears. In this case, spread to brain could be hematogenous spread after accidental inoculation in nail.

Early diagnosis is a challenge due to the rarity and lack of specific signs and symptoms of disease. Brain abscess is classic CNS manifestation.^[5] However, the patient can also present meningitis, encephalitis, myelitis, or arachnoiditis.^[3] Clinical symptoms can vary as memory loss and hemiplegia. Headache and hemiparesis are the most common symptoms.^[3] In this case, symptoms were memory loss and altered behavior.

Classically described MRI findings are ring-enhancing lesions on T1-weighted imaging, hypointensity of the rings on T2-weighted imaging, and low-to-high signal on diffusion-weighted imaging.^[6] We were misled to the preoperative diagnosis of high-grade glioma in the present case due to absence of fever and other constitutional symptoms of infection and hyperintensity on T2-weighted imaging and FLAIR. Magnetic resonance spectroscopy brain can help to differentiate.^[5] Intraoperative frozen section or crush smear can help in early diagnosis and management of CPHM.^[7]

Culture and isolation of pathogen from the serum or cerebrospinal fluid (CSF) may not always be possible.^[8] Diagnosis is made by surgical biopsy.^[5] Only the tissue examination can be useful to identify irregularly swollen hyphae with yeast-like structure and to confirm the presence of dematiaceous hyphae in melanin-specific Fontana Masson stain.^[2,3] There is no standard guidelines for CPHM due to rarity of cases.^[2] Most treatment protocols are based on sporadic case reports.^[2] A combination of surgical and medical treatment is generally recommended.^[6,9] Complete excision of brain abscess has better outcome than only

aspiration or partial excision. There are no standardized therapies, but voriconazole, posaconazole, and itraconazole demonstrate the most consistent *in vitro* activity against this group of fungi.^[2] Voriconazole may presumably be superior for CNS infections because of its ability to achieve good levels in the CSF.^[2,3,9,10] The precision of treatment length is still not known, but long-term therapy is recommended.

For disseminated or intracranial diseases with limited surgical options, combination antifungal therapy (polyene, flucytosine, terbinafine, echinocandins, and/or extended-spectrum azoles) is frequently considered.^[2,10] In most cases in which surgery is performed, antifungal drug treatment is used to insure elimination of any residual infection^[10] as in this case.

Therapy for pulmonary PHM consists of intravenous liposomal amphotericin B or mold-active azoles, except ketoconazole, for a prolonged period.^[2] CPHM with pulmonary involvement should have a role of liposomal amphotericin B along with azoles. Prognosis is poor.

Conclusions

CPHM is rare disease, but challenging one with high mortality rate, particularly when the CNS is affected. Diagnosis depends on a high index of clinical suspicion along with accurate mycological findings. Detailed studies are required for deciding treatment protocols.

Declaration of patient consent

The authors certify that they have obtained all appropriate patient consent forms. In the form the patient(s) has/have given his/her/their consent for his/her/their images and other clinical information to be reported in the journal. The patients understand that their names and initials will not be published and due efforts will be made to conceal their identity, but anonymity cannot be guaranteed.

Financial support and sponsorship

Nil.

Conflicts of interest

There are no conflicts of interest.

References

1. Ajello L, Georg LK, Steigbigel RT, Wang CJ. A case of phaeohyphomycosis caused by a new species of *Phialophora*. *Mycologia* 1974;66:490-8.
2. Chowdhary A, Meis JF, Guarro J, de Hoog GS, Kathuria S, Arendrup MC, et al. ESCMID and ECMM joint clinical guidelines for the diagnosis and management of systemic phaeohyphomycosis: Diseases caused by black fungi. *Clin Microbiol Infect* 2014;20 Suppl 3:47-75.
3. Revankar SG, Sutton DA, Rinaldi MG. Primary central nervous system phaeohyphomycosis: A review of 101 cases. *Clin Infect Dis* 2004;38:206-16.
4. Palaoglu S, Sav A, Basak T, Yalcinlar Y, Scheithauer BW. Cerebral phaeohyphomycosis. *Neurosurgery* 1993;33:894-7.
5. Jung NY, Kim E. Cerebral phaeohyphomycosis: A rare cause of brain abscess. *J Korean Neurosurg Soc* 2014;56:444-7.
6. Li DM, de Hoog GS. Cerebral phaeohyphomycosis – A cure at what lengths? *Lancet Infect Dis* 2009;9:376-83.
7. Aggarwal A, Salunke P, Mohindra S, Garg R, Radotra BD. A case of cerebral phaeohyphomycosis in an immunocompetent patient: Emphasis on intraoperative findings. *Neurol India* 2014;62:551-2.
8. Takei H, Goodman JC, Powell SZ. Cerebral phaeohyphomycosis caused by *Ladophialophora bantiana* and *Fonsecaea monophora*: Report of three cases. *Clin Neuropathol* 2007;26:21-7.
9. Sood S, Vaid VK, Sharma M, Bhartiya H. Cerebral phaeohyphomycosis by *Exophiala dermatitidis*. *Indian J Med Microbiol* 2014;32:188-90.
10. Perfect JR. Management of phaeohyphomycosis. In: Ghannoum MA, Perfect JR, editors. *Antifungal Therapy*. 1st ed. Florida: CRC Press; 2016. p. 343-50.