

Meningiomas with Collagenous Rosettes: A Report of Three Cases

Abstract

Formation of rosettes is very rarely encountered in meningiomas. The 2016 WHO classification of central nervous system tumors mentions it as a rare pattern secondarily encountered in different variants. We report three cases of meningiomas forming collagenous rosettes. Case 1 was a 60-year-old male with a right frontoparietal mass lesion. Excisional biopsy showed features of atypical meningioma (WHO Grade II) with diffusely scattered collagenous rosettes. Case 2 was a 48-year-old male with right frontoparietal space-occupying lesion. Microscopy revealed a papillary variant of meningioma (WHO Grade III) with prominent diffusely scattered collagenous rosettes. Case 3 was a 75-year-old female with left parietal convexity tumor. Microscopy revealed a clear-cell meningioma (WHO Grade II) with cerebral invasion. Focal collagenous rosettes and fibrosclerotic whorls were noted. In all three cases, Masson's trichrome was used to confirm collagenous nature of the rosettes. All three tumors were positive for epithelial membrane antigen and vimentin.

Keywords: *Atypical meningioma, clear-cell meningioma, collagenous rosettes, papillary meningioma*

Introduction

Meningiomas are tumors arising from meningeothelial cells which show diverse histological features. Many morphological variants and patterns are described some of which are known to upgrade tumor, for example, papillary, rhabdoid, clear cell, and choroid.^[1]

In the 2016 WHO classification of central nervous system tumors, formation of meningeothelial rosettes has been described as a rare pattern encountered secondarily in different variants.^[1] If they are encountered in poorly differentiated cases, they may pose a diagnostic challenge since rosettes are usually associated with ependymal or neuronal differentiation.^[2]

Due to the rarity of this pattern, there are very few reports found in the literature. In this case report, we discuss three cases with formation of rosettes.

Case Reports

Case 1

A 60-year-old male presented with numbness in the left hand for 1 year and an episode of generalized tonic-clonic convulsions.

This is an open access journal, and articles are distributed under the terms of the Creative Commons Attribution-NonCommercial-ShareAlike 4.0 License, which allows others to remix, tweak, and build upon the work non-commercially, as long as appropriate credit is given and the new creations are licensed under the identical terms.

For reprints contact: reprints@medknow.com

His neurological examination was normal. Magnetic resonance imaging (MRI) revealed an extra-axial solid-cystic mass in the right frontoparietal region measuring 6.8 cm × 3.8 cm × 3.7 cm. Excisional biopsy showed features of an atypical meningioma (WHO Grade II) with meningeothelial cells in syncytia and nests. Nuclear pleomorphism, hyperchromatism, and prominent nucleoli were seen. Mitotic activity was 5/10 hpf. Also seen were diffusely scattered rosettes. Masson's trichrome was used to confirm their collagenous nature. Tumor showed epithelial membrane antigen (EMA) and vimentin positivity.

Case 2

A 48-year-old male presented with 1-year history of convulsions and left-sided limb weakness for 4 months. MRI showed right frontoparietal space-occupying lesion. Excisional biopsy revealed papillary variant of meningioma (WHO Grade III) with focal rhabdoid features. There was nuclear pleomorphism with few cells showing prominent nucleoli. Tumor showed inflammatory infiltrate composed of lymphocytes and plasma cells. Prominent diffusely scattered collagenous rosettes were seen which were highlighted by Masson's trichrome stain. Mitotic count

How to cite this article: Vaidya MM, Shenoy AS, Goel NA. Meningiomas with collagenous rosettes: A report of three cases. *Asian J Neurosurg* 2019;14:568-70.

**Mihir Mohan Vaidya,
Asha Sharad
Shenoy¹,
Naina Atul Goel¹**

*Departments of Neuropathology
and ¹Pathology, Seth G.S.M.C,
Mumbai, Maharashtra, India*

Address for correspondence:

*Dr. Asha Sharad Shenoy,
301, Arihant, 613-B, 15th Road,
Khar, Mumbai - 400 052,
Maharashtra, India.
E-mail: shenoyasha@yahoo.
co.in*

Access this article online

Website: www.asianjns.org

DOI: 10.4103/ajns.AJNS_256_18

Quick Response Code:



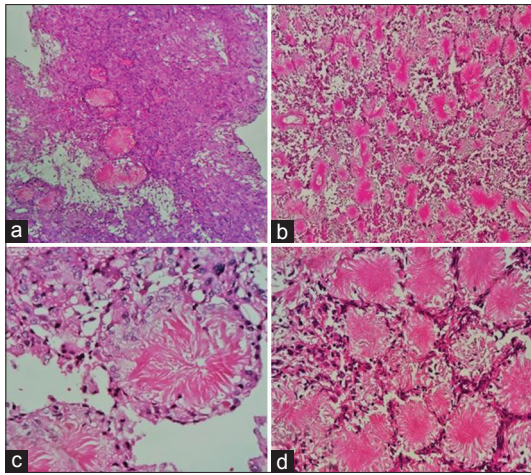


Figure 1: Diffusely scattered collagenous rosettes surrounded by neoplastic meningothelial cells (a and b: H and E, $\times 10$, c and d: H and E, $\times 40$)

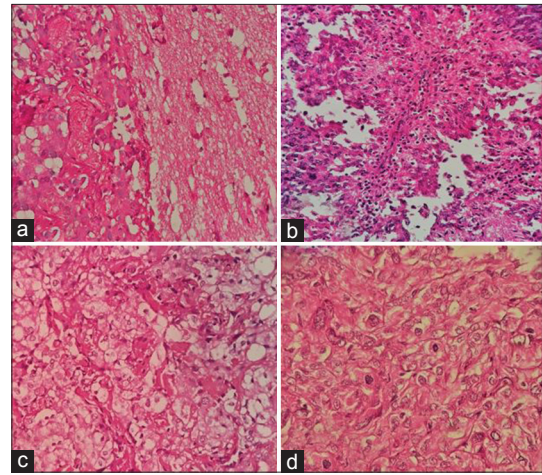


Figure 2: Higher grade features displayed by meningiomas. (a) Cerebral invasion, (b) papillary architecture, (c) clear-cell morphology, (d) increased mitotic activity (H and E, $\times 40$)

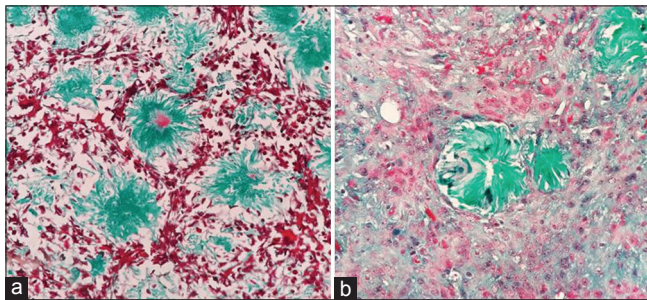


Figure 3: Trichrome stain highlighting the collagenous nature of the rosettes (a and b: Masson's trichrome, $\times 40$)

was $<4/10$ hpf. MIB-1 labeling index was 5%–6%. Tumor was positive for EMA and vimentin.

Case 3

A 75-year-old female presented with a history of right-sided limb weakness for 10 months and multiple episodes of seizures for 9 months. MRI revealed a left parietal convexity tumor. Excisional biopsy revealed a clear-cell variant of meningioma (WHO Grade II) showing marked pleomorphism with some binucleated cells and multinucleated giant cells. Scattered tiny foci of necrosis were present. Intervening blocky perivascular and interstitial collagen were seen. Occasional mitoses were noted ($<4/10$ hpf). Focal collagenous rosettes and fibrosclerotic whorls were seen which were highlighted by Masson's trichrome stain. Tumor cells showed EMA and vimentin positivity. Focally, tumor was seen infiltrating the cerebral parenchyma [Figures 1-4].

Discussion

Rosette formation is a very rare pattern that can occasionally be encountered in meningiomas. As per our knowledge, only published reports of rosette-forming meningiomas in humans are a clinicopathological study of 11 rosette-forming meningiomas,^[2] a case report describing

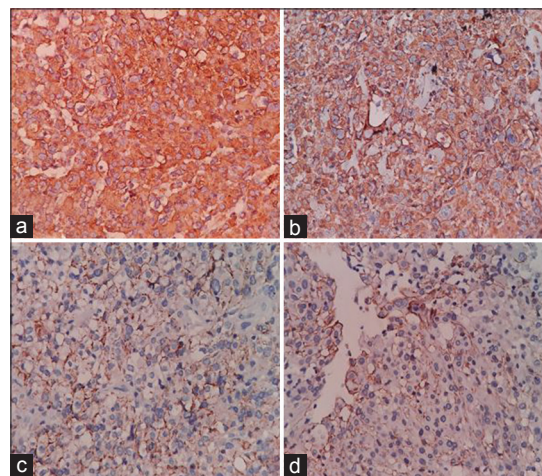


Figure 4: (a and b) Tumor cells showing vimentin positivity. (c and d) Membranous epithelial membrane antigen positivity displayed by the tumor cells ($\times 40$)

secretory meningioma with meningothelial rosettes in a case of moyamoya disease^[3] and a mention by Dr. Kepes while highlighting differential diagnostic problems in meningiomas.^[4] Haybaeck *et al.* described a case of collagen-producing meningioma showing many collagenous spheroid precipitates instead of rosettes in which tumor cells also expressed vasogenic substances.^[5] Meningothelial rosettes have been reported in canines.^[6]

Two of our cases were male patients while one was a female. One patient was middle aged (38 years old), while two patients were elderly (60 and 75 years old). In two of the cases, tumor was right frontoparietal in location, while in the third case, it was seen in left parietal convexity.

In the case series of 11 cases, patients ranged from 18 to 86 years, female-to-male ratio was 1:8 and all tumors were intracranial.^[2] In the other published report of secretory meningioma with meningothelial rosettes, tumor was seen in a 66-year-old male and location was left hemisphere.^[3]

Table 1: Summary of pathological features of the three cases of meningioma

Case number	Location of tumor	Subtype	Mitoses	Brain Invasion	Other features	Nature and distribution of rosettes	Grade of tumor
1	Right frontoparietal	Atypical meningioma	5/10 hpf	None	Pleomorphism, hyperchromatic nuclei, prominent nucleoli	Collagenous/diffuse	II
2	Right frontoparietal	Papillary meningioma	<4/10 hpf	None	Focally rhabdoid, pleomorphism, bizarre cells, inflammatory infiltrate	Collagenous/diffuse	III
3	Left parietal convexity	Clear-cell meningioma	<4/10 hpf	Present	Pleomorphism, intervening blocky collagen, foci of necrosis, brain invasion	Collagenous/focal	II

Hpf – High-power field

Table 2: Comparison of age, sex, and grade of the present cases with other published case reports

Case report	Age	Sex	Grade
Present	60, 48, 75	Male (2), female (1)	II, III, II
Liverman <i>et al.</i> ^[2]	18-86	Female: male ratio=1:8	I-III
Tada <i>et al.</i> ^[3]	66	Male	I (secretory)

All our cases were higher grade meningiomas. Two of the meningiomas were of the WHO Grade II (atypical meningioma and clear-cell meningioma) with the first case having a mitotic count of 5/10 hpf and clear-cell meningioma showing foci of brain invasion. One case was papillary meningioma (WHO Grade III). In the study published by Liverman *et al.*, 11 rosette-forming meningiomas had different grades ranging from I to III and different patterns, leading them to conclude that rosettes may be seen nonspecifically in different variants and also any grade can be encountered.^[2]

Rosettes encountered in meningiomas can be collagenous or with central gland-like lumens (true rosettes) and even perivascular pseudorosettes can be encountered. In poorly differentiated cases, they may pose a diagnostic challenge, especially if the rosettes resemble the Homer–Wright rosettes as seen in primitive neuroectodermal tumor, medulloblastomas, neuroblastomas, etc.^[2] In all three of our cases, rosettes were of collagenous nature, as highlighted by the Masson's trichrome stain.

In two of our cases, rosettes were diffusely scattered throughout tumor, while in one tumor, they were only focally seen. In the study done by Liverman *et al.*, 7 out of 11 rosettes had focal rosettes, while only 4 cases had diffuse distribution of rosettes [Table 1].^[2]

To summarize, all three of our rosette-forming meningiomas were of a higher grade (Grades II and III) and

were seen in middle-aged to elderly patients. All rosettes were collagenous in nature and either diffuse or focal in distribution [Table 2].

Declaration of patient consent

The authors certify that they have obtained all appropriate patient consent forms. In the form the patient(s) has/have given his/her/their consent for his/her/their images and other clinical information to be reported in the journal. The patients understand that their names and initials will not be published and due efforts will be made to conceal their identity, but anonymity cannot be guaranteed.

Financial support and sponsorship

Nil.

Conflicts of interest

There are no conflicts of interest.

References

1. Louis DN, Ohgaki H, Wiestler OD, Cavenee WK. WHO Classification of Tumours of the Central Nervous System. 4th ed. IARC: Lyon; 2016.
2. Liverman C, Mafra M, Chuang SS, Shivane A, Chakrabarty A, Highley R, *et al.* A clinicopathologic study of 11 rosette-forming meningiomas: A rare and potentially confusing pattern. *Acta Neuropathol* 2015;130:311-3.
3. Tada T, Ishii K, Oshima S, Hara H, Kobayashi S. Secretory meningioma associated with numerous meningotheial rosettes. *Acta Neuropathol* 1992;84:342-5.
4. Kepes JJ. Presidential address: The histopathology of meningiomas. A reflection of origins and expected behavior? *J Neuropathol Exp Neurol* 1986;45:95-107.
5. Haybaeck J, Smolle E, Schöckler B, Kleinert R. The WHO grade I collagen-forming meningioma produces angiogenic substances. A New meningioma entity. *Anticancer Res* 2016;36:941-9.
6. Yamashita T. Meningotheial rosettes in the canine subarachnoid space. *Acta Neuropathol* 1985;66:223-32.